

**Case report**

**Mydriasis and Ophthalmoplegia in a 10-year-old girl: A Diagnostic Predicament**

UNDER PEER REVIEW

## Abstract:

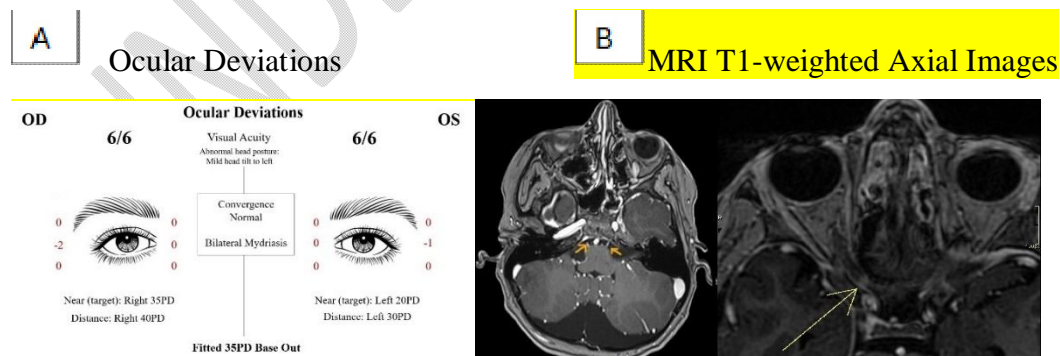
This case reports a 10-year-old girl who presented with sudden-onset diplopia and bilateral mydriasis following a recent upper respiratory infection. Ocular examination showed poor light response and mild abduction deficits. Initial low-resolution MRI was normal, but a high-resolution MRI revealed bilateral enhancement of the abducens and oculomotor nerves. Viral-induced cranial nerve palsies were suspected. The use of systemic steroids was considered but concerns about side effects in children led to a conservative approach. Patient achieved full recovery four months later. This case highlights the importance of high-resolution imaging in diagnosing cranial nerve palsies in children and raises questions about the role of corticosteroids in managing viral-induced neuropathies. Further research is needed to determine optimal treatment strategies for such cases.

**Keywords:** Mydriasis, Ophthalmoplegia, Lateral Rectus Palsy, Viral-induced, Paediatrics, Paediatric Ophthalmology, Neuro-ophthalmology

## Introduction

Mydriasis is due to stimulation of the iris dilator muscle, compromise of the parasympathetic tone of the iris sphincter muscle, or both<sup>1</sup>. Bilateral mydriasis typically arises when sympathetic innervation exceeds parasympathetic innervation<sup>2</sup>. This is frequently associated with systemic disorders such as Miller-Fisher syndrome or Botulism, pharmaceutical agents, midbrain lesions (specifically in the pretectal area and third nerve nuclei), iris ischaemia due to vasculitis or atherosclerosis, or autoimmune autonomic ganglionopathy<sup>3</sup>. Ophthalmoplegia refers to the condition of the paralysis of eye muscles, which can be caused by various factors such as nerve damage, systemic diseases, or genetic mutations<sup>4,9,10</sup>. Viral aetiologies of mydriasis and ophthalmoplegia are rare. This study is a case of acute mydriasis and ophthalmoplegia in a girl.

## Case Presentation:



**Figure 1:** A. The patient displayed bilateral esotropia and bilateral mydriasis; B. MRI T1 weighted axial images demonstrating bilaterally enhancing abducens nerves (left) and right oculomotor enhancing nerve (right).

A 10-year-old Caucasian girl presented to an eye center with sudden onset diplopia and bilateral mydriasis. One week earlier, while on holiday, she became unwell with lethargy, headaches, fever and progressive cough. She was diagnosed with upper respiratory tract infection and was managed conservatively with gradual resolution of her systemic symptoms. She had no previous ocular history and denied any trauma.

On examination, best-corrected Snellen visual acuity was 6/6 either eye. There was bilateral symmetrical mydriasis with poor response to light and accommodation (Figure 1 A). There was no ptosis. On extra-ocular muscle testing the child exhibited -2 abduction deficit in the right and -1 abduction deficit in the left. Anterior segments appeared healthy and dilated funduscopy was unremarkable. There were no other neurological findings on examination.

Blood investigations including infectious screen, autoimmune screen, aquaporin-4 and myelin oligodendrocyte glycoprotein and anti-gangliosides antibodies were all negative. Low-resolution magnetic resonance imaging (MRI) of the brain and orbits with contrast enhancement did not reveal any abnormality. Lumbar puncture demonstrated normal cerebrospinal fluid (CSF) studies, including infections screen and oligoclonal bands, and the opening pressure was 21cmH<sub>2</sub>O.

**Diagnosis:**

Suspected Viral Induced Cranial Nerve Palsies

**Next Step:**

Repeat high-resolution MRI of brain with contrast

**Discussion:**

Acquired third, fourth, and sixth cranial nerve palsies are rare in children and often signal serious pathologies<sup>5</sup>. Neoplasia and trauma are the leading causes in this age group for all three palsies. Prompt diagnostic work-up is crucial due to the potential for long-term loss of function and life-threatening conditions.

The initial diagnostic work-up of the patient did not confirm a diagnosis. Even though an infectious aetiology was suspected due to the temporal association with the preceding upper respiratory tract infection, it was necessary to exclude the possibility of neoplasia. The primary low-resolution MRI was reported as normal with no space occupying lesion or raised intracranial pressure but was considered inadequate in visualising cranial nerve pathways. Therefore, a multiplanar high resolution 3T MRI with contrast enhancement was requested which demonstrated bilateral abducens and oculomotor nerve enhancement (Figure 1 B).

Palsies of abducens, oculomotor or trochlear nerve may arise from disease processes which affect them at any point along their anatomical pathways. Each nerve travels along a highly stereotypical path beginning at the individual cranial nerve nuclei in the brain and terminating at the neuromuscular junction, where they innervate their respective extraocular muscle(s). Three-dimensional MRI steady-state free precession sequences and modified fully refocused steady-state sequences such as constructive interference in steady state (CISS) should

be requested to allow detailed visualization of the cranial nerve pathways in patients with unexplained cranial nerve palsies.

A lumbar puncture was performed to rule out intracranial hypertension, which is rare in paediatric patients, as well as to assess for inflammatory, infectious, or infiltrative processes through CSF studies. Viral serology for common viruses was also undertaken and was negative. Due to the COVID-19 pandemic and recent travel history, COVID infection was suspected. The child had a negative rapid test on holiday but could not undergo a polymerase chain reaction (PCR). A PCR was performed 12 days after the onset of her systemic symptoms and was also negative. She did have though high levels of COVID antibodies with no previous history of vaccination and last confirmed COVID infection almost a year ago.

The treatment for viral-related oculomotor and abducens nerve palsy remains unclear. The palsy is often self-limiting, usually within months, and therefore a more conservative approach may be warranted<sup>5</sup>. For symptomatic relief Fresnel prisms were fitted and the patient was asymptomatic in primary position.

There was a debate among the patient's physicians whether systemic steroids should be prescribed. The role of steroids in children with viral-induced cranial nerve palsy is not clear. Steroids have been used successfully in pediatric populations to treat oculomotor and abducens nerve palsies<sup>4</sup>. Steroids have been shown to hasten recovery in cranial nerve neuropathies caused specifically by COVID-19<sup>6,7</sup>. However, children are more susceptible to steroid side effects than adults<sup>8</sup>. Given the self-limiting nature of the palsies, the risk of significant adverse effects may not outweigh the benefits of corticosteroid administration. Nevertheless, more research is required to determine suitability of corticosteroids as a treatment.

#### **Patient Outcome:**

The repeat high-resolution MRI imaging helped localize the inflammation along the pathways of the oculomotor and abducens cranial nerves. The most likely diagnosis was viral related cranial nerve palsy, as most other aetiologies were excluded and there was a close temporal association with the preceding upper respiratory tract infection. COVID-19 was suspected but could not be proven. The patient attained full recovery four months from the onset of symptoms and remained symptom-free two years later.

#### **Conclusion:**

Virally induced mydriasis and ophthalmoplegia is rare but important complication. Neoplasia and other causes of raised intracranial pressure must be excluded. Treatment was conservative with Fresnel prism lenses and the condition ultimately resolved four months after symptom onset. The specific viral aetiology was unclear although COVID-19 was suspected.

**Consent:**

As per international standards, parental written consent has been collected and preserved by the author(s).

**Disclaimer (Artificial intelligence)****Option 1:**

Author(s) hereby declare that NO generative AI technologies such as Large Language Models (ChatGPT, COPILOT, etc.) and text-to-image generators have been used during the writing or editing of this manuscript.

**Option 2:**

Author(s) hereby declare that generative AI technologies such as Large Language Models, etc. have been used during the writing or editing of manuscripts. This explanation will include the name, version, model, and source of the generative AI technology and as well as all input prompts provided to the generative AI technology

Details of the AI usage are given below:

- 1.
- 2.
- 3.

**References:**

1. Rathnasiri, K. A. D. V., Senadeera, Y., Karunathilaka, S., Wijerathne, A., & Premasiri, L. (2024). Bilateral mydriasis as the first manifestation of Miller Fisher syndrome. *Asian Journal of Internal Medicine*, 3(2). <https://doi.org/10.4038/ajim.v3i2.166>
2. Kang, Y. E., Chae, J., Nguyen, T. T., Kang, J. J., & Oh, S. Y. (2024). A Case Report of Acute Bilateral Mydriasis Induced by Herbal Medication. *Neuro-Ophthalmology*, 48(3), 193-197. <https://doi.org/10.1080/01658107.2023.2301363>
3. Xu, P., Wu, J., Qian, F., Wan, H. Q., Yu, Y., Li, M., ... & Huang, M. (2021). Rare autonomic nervous system dysfunction: Alternating bilateral mydriasis. *World Journal of Emergency Medicine*, 12(4), 330. <https://doi.org/10.5847/wjem.j.1920-8642.2021.04.015>
4. Park, K.-A., Min, J.-H., Oh, S.Y., Kim, B.J., 2019. Idiopathic third and sixth cranial nerve neuritis. *Jpn J Ophthalmol* 63, 337–343. <https://doi.org/10.1007/s10384-019-00666-7>
5. Merino, P., Gómez de Liaño, P., Villalobo, J.M.C., Franco, G., Gómez de Liaño, R., 2010. Etiology and treatment of pediatric sixth nerve palsy. *Journal of American*

*Association for Pediatric Ophthalmology and Strabismus* 14, 502–505.

<https://doi.org/10.1016/j.jaapos.2010.09.009>

6. Zhang, T., Tang, J., 2021. Two cases of benign abducens nerve palsy in children and their long-term follow-up. *Journal of International Medical Research*.  
<https://doi.org/10.1177/0300060520986702>
7. Elenga, N., Martin, E., Gerard, M., Osei, L., Rasouly, N., 2021. Unilateral diplopia and ptosis in a child with COVID-19 revealing third cranial nerve palsy. *Journal of Infection and Public Health* 14, 1198–1200. <https://doi.org/10.1016/j.jiph.2021.08.007>
8. Deshmukh, C.T., 2007. Minimizing side effects of systemic corticosteroids in children. *Indian J Dermatol Venereol Leprol* 73, 218. <https://doi.org/10.4103/0378-6323.33633>
9. Albayram S, Ozer H, Sarici A, Murphy K, Miller N. Unilateral mydriasis without ophthalmoplegia—a sign of neurovascular compression?: case report. *Neurosurgery*. 2006 Mar 1;58(3):E582-3.
10. Kobayashi Y, Kondo Y, Uchibori K, Tsuyuzaki J. Recurrent painful ophthalmoplegic neuropathy with residual mydriasis in an adult: should it be classified as ophthalmoplegic migraine?. *Internal Medicine*. 2017 Oct 15;56(20):2769-72.

UNDER PEER REVIEW