

Strangulated trans epiploic hernia: A rare case and review of the literature

Abstract :

Internal hernias are protrusions of the abdominal hollow viscera into an intraperitoneal orifice, but which remain within the abdominal cavity.

This does not include iatrogenic post-surgical forms, the most frequent of which are currently observed after orthotopic liver transplants and laparoscopic gastrojejunal shunts with Y-loop anastomosis. The different varieties of internal hernia are usually presented according to their relative frequency and anatomical location, according to the classification proposed by Welch in 1958 and used in most published works: Paraduodenal 50-55%, pericæcal 10-15%, transmesenteric 8-10%, foramen of Winslow 6-10%, intersigmoid 4-8%, pelvic 6%, including broad ligament 4-5%.

We report the case of a 66-year-old patient, followed for diffuse interstitial lung disease at fibrosis stage for 4 years, diabetic on insulin for 20 years, hypertensive on amlodipine for 4 years.

Admitted to our department in an emergency setting for an occlusive syndrome, clinically the patient presented with a tympanic distended abdomen.

A CT scan revealed a gallbladder occlusion and surgical exploration revealed a transepilpoic internal hernia.

Keywords : trans epiploic hernia, surgical exploration , abdominal herniation

Introduction

An internal abdominal herniation is the protrusion of an abdominal organ through a normal or abnormal mesenteric or peritoneal aperture. Internal hernias can present as an acute bowel obstruction, usually with an ischemic component due to vascular strangulation, and account for 0.2% to 5.8% of small bowel obstructions in published series [1-3]. Abdominal hernias are common among patients with surgical diseases. The most common type, inguinal hernia, constitutes 75-77% [11]. Internal abdominal herniations can

be either acquired through a trauma or surgical procedure (iatrogenic internal abdominal herniations) or constitutional or related to congenital peritoneal defects. Because internal abdominal herniations are rare, their diagnosis remains a challenge for both the clinician and the radiologist. Symptoms of internal abdominal herniations are non-specific. Computed tomography (CT) is believed to facilitate the diagnosis of internal abdominal herniations [4]. Internal hernia through trans-epiploic is a rare cause of intestinal obstruction. It is most often diagnosed intraoperatively[5,12]. This study presents a case of Strangulated trans epiploic hernia in an emergency setting.

Case report :

The patient was 66 years old, followed for diffuse interstitial lung disease at the fibrosis stage for 4 years, diabetic on insulin for 20 years, hypertensive on amlodipine for 4 years.

Admitted to our department in an emergency setting for an occlusive syndrome evolving 2 days prior to admission, associated with food vomiting.

Clinical examination showed a tympanic distended abdomen. Abdomen without preparation (ASP) showed water-area levels in the pelvis (Fig.1).

D URGENCE CASABLANCA

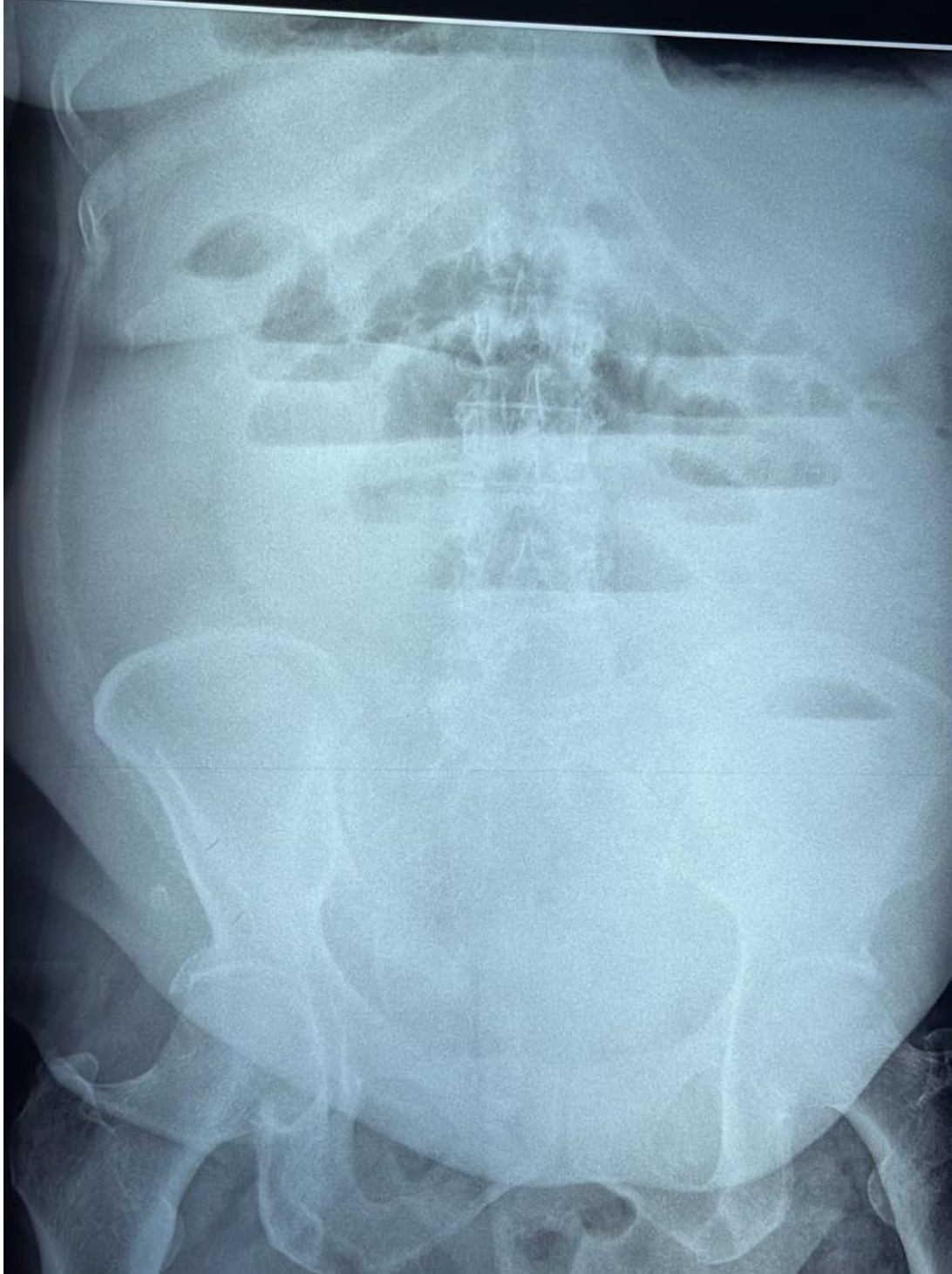


Figure 1: Hydro-area levels on the ASP

On thoraco-abdomino-pelvic CT scan: mechanical bowel obstruction with a transitional level in the right flank at the level of the vertebral body of L4, with no sign of digestive distress (fig.2).

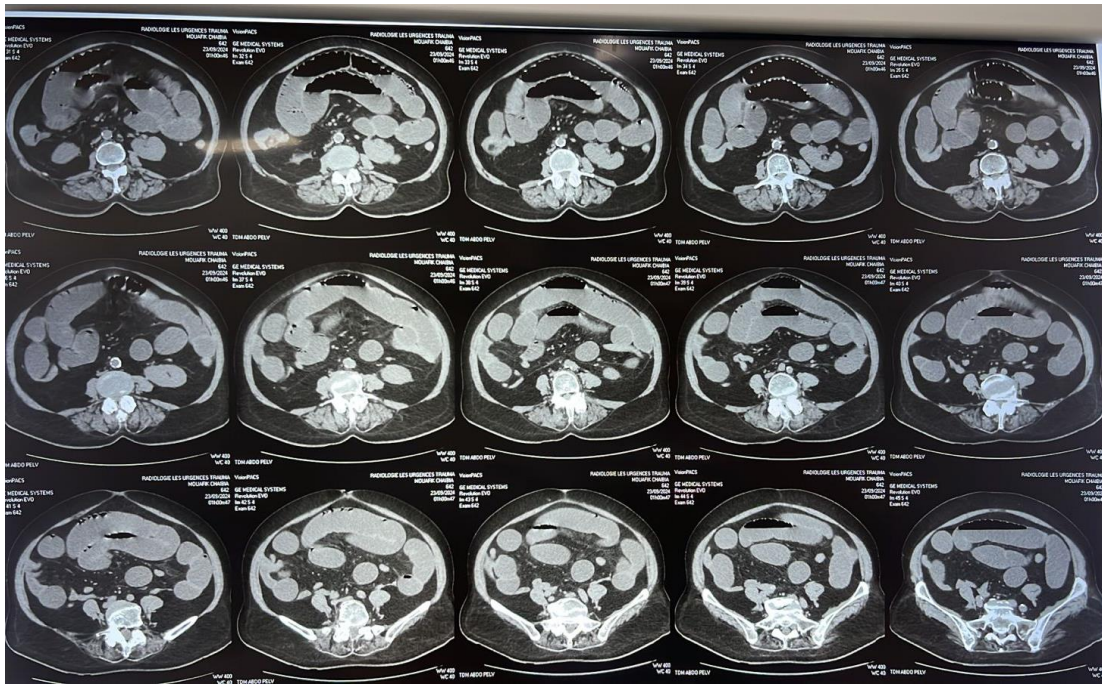


Figure 2: scannographic section with hydroaerobic distension and transitional level in the right flank.

Intraoperative examination revealed a small peritoneal effusion of serous fluid, and a trans epiploic internal hernia with viable oelitic content and 3.5cm of upstream oelitic distension, with no sign of digestive distress. The rest of the epiploic apron was without anomaly (fig.3 and 4).

- The procedure involved reduction of a trans epiploic hernia with opening of the epiploic defect.

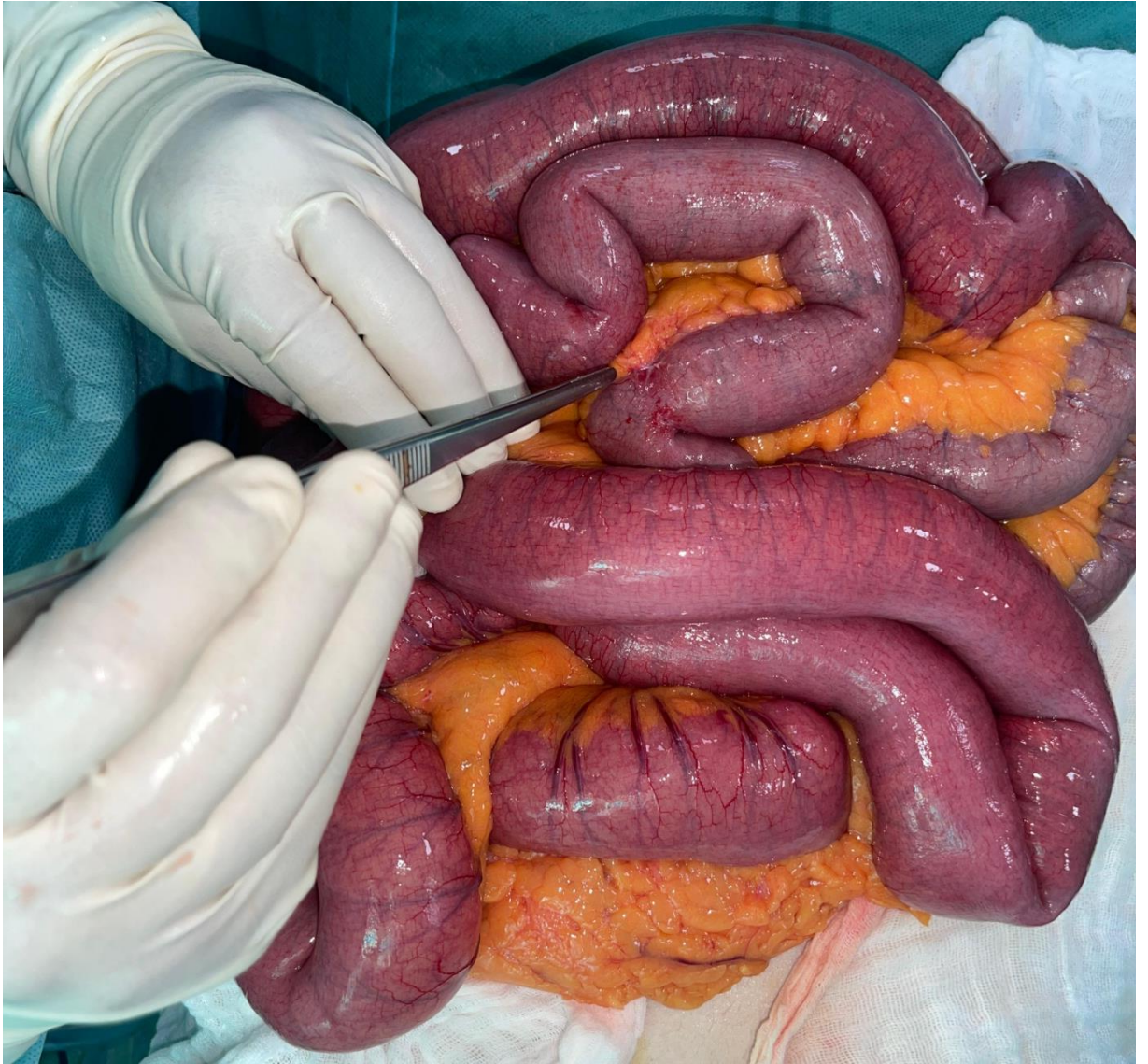

Figure3: distended cecum with transitional level

UNDER

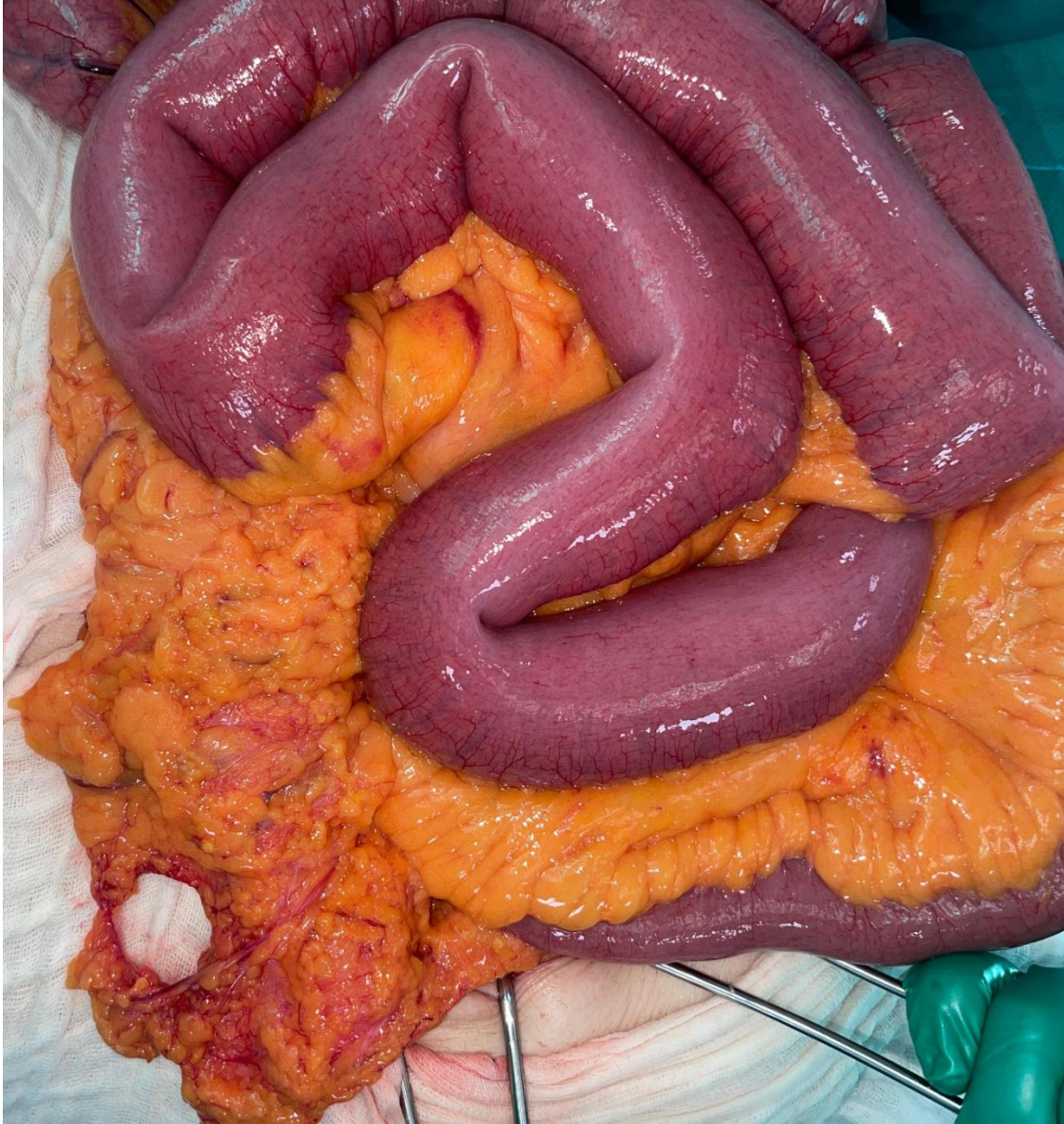

figure 4: the trans epiploic hernia orifice

Discussion :

Internal hernias are a rare cause of intestinal obstruction, representing about 0.5 to 5% of all causes. Internal hernias are rare, representing 0.5 to 5.8% of cases of intestinal obstruction; however, they are associated with mortality of

up to 50% in certain series. trans epiploic hernia is the third most frequently occurring, representing 8% of internal hernias (5) .

True trans-omental hernias correspond to the incarceration of small intestines in an orifice generally located near the free edge of the greater omentum on the right side. They have no sac, and the distended loops are anteriorly located, with a point of convergence at a distance from the right iliac fossa, generally paramedian, retroumbilical. Incarcerated coives are most often of the small intestine, but the cecum and a dolichosigmoid may be associated. The characteristic feature is the medial and posterior displacement of the cecum and ascending colon, as the distended herniated loops develop in the right paracolic gutter. As in transmesenteric hernias, there is obviously no omental fat interposed between the distended loops and the abdominal wall (6).

They should be distinguished from “iatrogenic” trans-mesenteric, transmesocolic or retro-anastomotic internal hernias after surgery [7,8]. The clinical symptoms may be non-specific: they generally point to an acute small bowel obstruction epigastric pain [9]. Their diagnosis is usually made intraoperatively. However, with the development of medical imaging, in particular CT and MRI, preoperative diagnosis is now possible.

Therefore, it is essential to appreciate the different varieties of internal hernias. Indeed, the diagnosis of a bowel obstruction by internal hernia implies a perfect knowledge of the anatomical varieties involved. Several anatomical forms of internal hernias have been reported. The delayed diagnosis can invoke necrosis which is a fatal complication [10].

Conclusion

Any sudden-onset occlusive syndrome with dilated small intestines in a central position in the abdominal cavity should, in a subject with no history of surgery, even an elderly one, raise the possibility of a strangulated internal hernia.

Trans epiploic hernia is a rare but possible cause of acute bowel obstruction in adults. The presence of spontaneously reduced episodes of sub-occlusion can be an important argument for the diagnosis. Late diagnosis can lead to complications such as intestinal necrosis.

Disclaimer (Artificial intelligence)

Option 1:

Author(s) hereby declare that NO generative AI technologies such as Large Language Models (ChatGPT, COPILOT, etc.) and text-to-image generators have been used during the writing or editing of this manuscript.

Option 2:

Author(s) hereby declare that generative AI technologies such as Large Language Models, etc. have been used during the writing or editing of manuscripts. This explanation will include the name, version, model, and source of the generative AI technology and as well as all input prompts provided to the generative AI technology

Details of the AI usage are given below:

- 1.
- 2.
- 3.

References :

1. GHAREMANI GG. Abdominal and pelvic hernias. *In* : RM Gore, MS Levine. Textbook of gastrointestinal radiology, 2nd d. Philadelphia, Saunders, 2000 : 1993-2009.
2. WELCH CE. Hernia : intestinal obstruction. Chicago, Year Book Medical, 1958: 239-268.
3. Meyers MA (1994) Dynamic radiology of the abdomen: normal and pathologic anatomy, 4th edn. Springer, New York
4. Martin LC, Merkle EM, Thompson WM (2006) Review of internal hernias: radiographic and clinical findings. *AJR Am J Roentgenol* 186:703–717
5. Tarek Anis, Acute Small Bowel Obstruction Caused by Trans Epiploic Hernia in a Young Man: A Case Report, *Scholars Journal of Medical Case Reports*, 10.36347/sjmcr.2023.v11i05.059.
6. INOUE Y, NAKAMURA H, MIZUMOTO S, AKASHI H. Lesser sac hernia through the gastrocolic ligament : CT diagnosis. *Abdom Imaging*, 1996, 21 : 145-147

7. Internal hernia through the omental foramen. Answer to the e-quiz "Epigastric pain with sudden onset" J. Cazejust, C. Lafont, M. Rayna, L. Aziz, A.C. Tourabi et Y. Menu Diagnostic and Interventional Imaging, 2013-06-01, Volume 94, Numéro 6, Pages 663-666, Copyright © 2012 Éditions françaises de radiologie

8. Mathieu D., Luciani A.: Internal abdominal herniations. AJR Am J Roentgenol. 2004; 183: pp. 397-404. Takeyama N., Gokan T., Ohgiya Y., Satoh S., Hashizume T., Hataya K., et. al.: CT of internal hernias. Radiographics 2005; 25: pp. 997-1015.

9. Fujita Anna, Takaya Junji, Takada Kohei, Ishihara Takayasu, Hamada Yoshinori, Harada Yoshiaki, et al. Transmesenteric hernia: report of two patients with diagnostic emphasis on plain abdominal X-ray finding. Eur J Pediatr 2003;162:147-9

10. ACUTE SMALL BOWEL OBSTRUCTION CAUSED BY TRANSMESENTERIC HERNIA STRANGULATION IN A YOUNG MAN: A CASE REPORT. Abdesslam Bouassria 1,2*, Hicham El Bouhaddouti 1,2, Ouadii Mouaqit 1,2, El Bachir Benjelloun 1,2 , Abdelmalek Ousadden 1,2 , Khalid Ait Taleb1,2 . 1 School of medicine and pharmacy of Fez, Sidi Mohammed Ben Abdellah University, Fez, Morocco. 2 Department of surgery « A », University Hospital Hassan IId , Fez, Morocco.

11. Mensah S, Maison POM, Kyei I, Adjei GA, Morna MT, Debrah S, Rahman GA. Evaluation of External Abdominal Wall Hernia Surgery in a Secondary Level Facility in Kumasi, Ghana. J. Adv. Med. Med. Res. [Internet]. 2020 Jul. 17 [cited 2024 Nov. 26];32(11):1-7. Available from: <https://journaljammr.com/index.php/JAMMR/article/view/3698>

12. Abbasov A, Yanar HT. Incarcerated appendix epiploica in a right inguinal hernia sac. Turkish Journal of Trauma & Emergency Surgery. 2022 Dec;28(12):1744.

UNDER PEER REVIEW