

# ***Clinical and Radiological Outcomes of Suprapatellar Intramedullary Nailing in Proximal Third Tibia Fractures: Technical Insights and Results.***

## **ABSTRACT**

**Aims:** Here we tend evaluate efficacy of supra-patellar nailing in the management of proximal tibial fractures by analyzing clinical, functional, and radiological outcomes. Additionally, it provides a detailed description of the technical aspects of the procedure, offering guidance to young surgeons on minimizing intraoperative and postoperative complications.

**Study Design:** Retrospective cohort study.

**Place and Duration of Study:** The study was conducted in the Department of Orthopaedics at G.K. General Hospital, Bhuj, from March 2022 to March 2024.

**Methodology:** This retrospective study included 50 patients with proximal tibia fractures treated with supra-patellar nailing. The data were collected over a two-year period, from March 2022 to March 2024, at the Gujarat Adani Institute of Medical Sciences, Bhuj, in the Department of Orthopaedics.

**Results:** A total of 50 patients were evaluated for clinical, functional, and radiological outcomes using appropriate scoring systems. The findings revealed a mean Visual Analog Scale (VAS) score of 0.45 at 1 year postoperatively, a mean Lysholm score of 97.12, and a mean radiological union time of 5 weeks.

**Conclusion:** Supra-patellar nailing is a highly effective technique for treating proximal third tibial fractures, provided that it is performed meticulously, adhering to established surgical principles and techniques with proper implant selection. This approach results in excellent clinical and radiological outcomes, with minimal complications when compared to other treatment modalities. Supra-patellar nailing offers distinct advantages in terms of positioning, nail entry, and placement, making it a viable option for the management of proximal third tibia fractures.

**Limitations:** The main limitations of this study include the relatively small sample size and the short duration of follow-up, which may influence the generalizability of the results.

*Keywords: Proximal tibia, functional, technical aspects, Fracture, Supra-patellar nailing*

## 1. INTRODUCTION

Tibial fractures are the most common among long bone fractures, with extra-articular proximal tibial fractures accounting for 6-12% of tibial shaft fractures. These injuries are often the result of high-energy trauma and frequently involve concomitant soft tissue damage [1]. The preferred treatment strategy for extra-articular tibial fractures, regardless of location (epiphysis, metaphysis, or diaphysis), involves stabilization and osteosynthesis using intramedullary nails [2]. Traditionally, these nails are introduced through an infrapatellar portal with the knee in full flexion [3]. However, this approach presents two key challenges. First, maximal knee flexion complicates the fixation of proximal fractures due to the antecurvatum deformity of the patellar tendon. Second, the integrity of the nail entry site is often compromised by soft tissue injuries resulting from the fracture.

In 1996, Tornetta and Collins [4] introduced a semi-extended technique involving a medial parapatellar arthrotomy to improve outcomes in proximal metaphyseal tibial fractures. They observed a displacement of approximately 15 degrees in proximal third tibial shaft fractures when the knee was flexed between 80 to 90 degrees, attributing this to the displacing force exerted by the quadriceps on the proximal segment. As a result, proximal third tibial fractures are particularly susceptible to positional influences, and the semi-extended approach offers significant benefits. By maintaining the leg at approximately 15-20 degrees of flexion, surgeons can mitigate the force of the quadriceps and focus on achieving an accurate and secure entry point. Tornetta described the optimal starting point as being located on the medial aspect of the lateral tibial spine in the coronal plane and at the articular margin in the sagittal plane [5].

It was not until 2010 that Eastman et al. demonstrated in a cadaveric study the feasibility of inserting a tibial nail in a retro-patellar manner through a considerably smaller incision than the medial para-patellar approach proposed by Tornetta [6]. Following this, manufacturers developed tibial nails specifically designed for insertion proximal to the patella through a small division in the quadriceps tendon, using protective sleeves to navigate beneath the patella. This technique is referred to as suprapatellar tibial nailing (SPTN), and the protective sleeves—usually made of metal or plastic—serve to safeguard the patellofemoral cartilage and vary depending on the manufacturer.

This study aims to review our experience with the suprapatellar approach for semi-extended nail insertion. Our objective is to compare this technique with traditional intramedullary nailing in terms of postoperative alignment, healing, function, range of motion (ROM), and pain.

---

## 2. Materials and Methods

This retrospective study evaluates the outcomes of supra-patellar tibial nailing in patients with proximal tibia fractures. A total of 50 patients were included in the study, conducted between March 2022 and March 2024 at the Gujarat Adani Institute of Medical Sciences, Bhuj, in the Department of Orthopaedics. Patients were classified according to the AO/OTA classification system. Postoperatively, all patients were followed up at regular intervals (every 4-6 weeks) for up to 2 years.

Clinical outcomes were assessed using the Visual Analog Scale (VAS) for pain [Figure-1], while functional outcomes were measured using the Lysholm knee score [Table-2]. Radiological union was assessed using the Radiological Union Score for Tibial fractures (RUST) [Table-1].

Preoperative assessment included evaluating the mobility of the patella in the affected limb and reviewing radiographic films for any signs of patellofemoral arthritis. The affected limb was shaved and prepped for surgery. The patient was positioned supine on a radiolucent table, with the injured leg supported by a knee roll or bolster, maintaining a flexion angle of approximately 15–20 degrees. The C-arm was positioned to obtain optimal imaging in both lateral views. The limb was draped, and the skin was prepped using standard sterile technique.

A 2 cm incision was made approximately 1-2 cm proximal to the superior pole of the patella. Soft tissue dissection was performed to identify the quadriceps tendon, which was split in the middle of the tendon along its full length. The retro-patellar space was bluntly assessed to ensure proper passage of the trocar. The trocar was introduced into the well-dissection space beneath the patella until it encountered the tibia. Once safely within the retro-patellar space, the trocar was removed and replaced with a guide-wire sleeve. A 3.2 mm guide-pin was inserted through the sleeve, and fluoroscopic images (AP and lateral views) were obtained. If the guide-pin was angled in varus or valgus in the AP view, it was re-directed; if the pin was incorrectly placed in the lateral view, the bolster was adjusted either proximally or distally to correct the pin trajectory. The multi-hole sleeve was then removed, and the entry reamer was introduced over the guide-pin.

It is essential to achieve reduction and maintain it with the help of reduction bone clamps or external reduction maneuvers before reaming. Successive reaming was performed, 1.5-2 mm above the selected nail diameter. The appropriate-sized nail was measured under fluoroscopy and inserted through the guide-pin. The nail was fixed using conventional screw fixation. If compression at the fracture site was necessary, a back-slapping technique could be used after inserting the distal screw. Fracture reduction and implant position were confirmed with fluoroscopic imaging.

Finally, the knee joint was irrigated, and soft tissue debris was suctioned to prevent future damage to the joint. The full range of motion was checked to verify patellar tracking. Closure was performed using conventional surgical techniques with appropriate suture materials [Figures-2, 3, 4, 5].

❖ INCLUSION CRITERIA:

- Extra-articular fracture of the proximal tibia (AO type 41A2)



TABLE -2 Lysholm score[9]

<b>1. Limp ( 5 points )</b>	None	5
	Slight or Periodic	3
	Severe/Constant	0
<b>2. Support ( 5 points )</b>	None	5
	Cane/Crutch Needed	3
	Unable to bear weight	0
<b>3. Locking ( 15 points )</b>	None	15
	Catching	10
	Occasional	6
	Frequently	2
	Currently Locked	0
<b>4. Instability ( 25 points )</b>	Never gives way	25
	Rarely with sports	20
	Often with sports	15
	Sometimes with ADL's	10
	Often during ADL's	5
	Every Step	0
<b>5. Pain ( 25 points )</b>	None	25
	Slight or periodic	20
	Severe/Constant	15
	Marked walking > 2km	10
	Marked walking < 2 km	5
	Constant	0
<b>6. Swelling ( 10 points )</b>	None	10
	After sports	3
	After daily activities	2
	Constant	0
<b>7. Stairs ( 10 points )</b>	No problem	10
	Slight Problem	6
	One step at a time	2
	Impossible	0
<b>8. Squatting ( 5 points )</b>	No problem	5
	Slight Problem	4
	Not beyond 90°	2
	Impossible	0

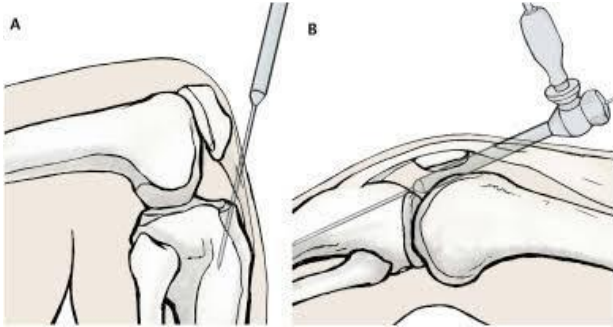


Figure-2 Technique of nailing, A-infrapatellar nailing, B-supra patellar nailing

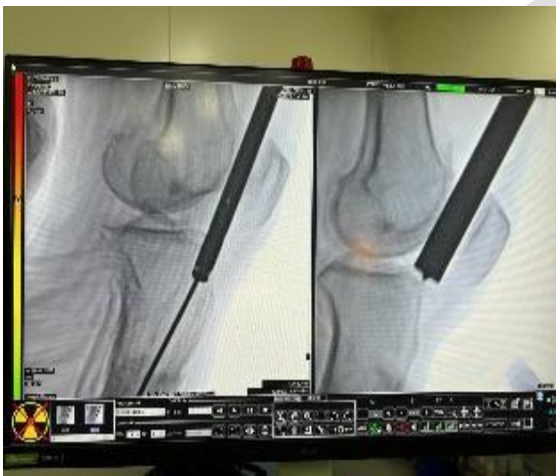

Figure-3 intra-op. IITV images

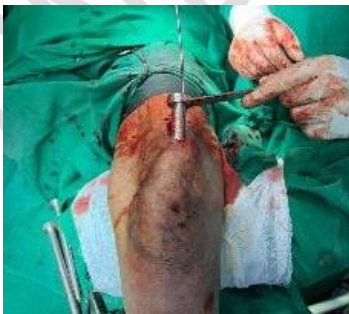

Figure-4 Position of zig-ap view

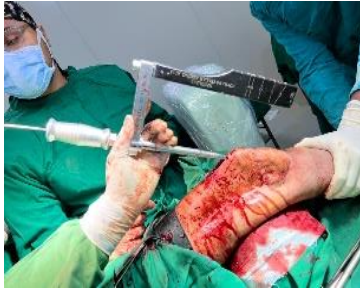

Figure-5 Position of zig

## Statistical Analysis

Data was analysed using frequency, percentage analysis, mean, standard deviation, using a statistical tool after entering the data into Microsoft Excel and descriptive statistical analysis was done using SPSS version 24, IBM Corp, Chicago. The probability value of 0.05 was considered significant.

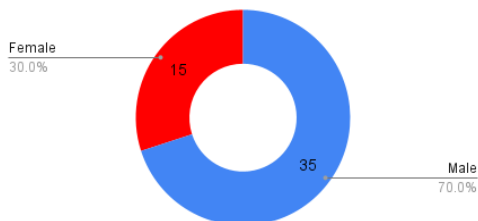
## RESULTS AND DISCUSSION

### 1. PATIENT RELATED

This is a Retrospective type of study. In which All patients were selected according to inclusion criteria. The Follow-up time period was of 2 year. Total patients selected were 50 Of which there were (70%)35 male and (30%) 15 females. Out of 50 patients (55%) 28 patients were having fracture over RIGHT side and (45%) 12 having fracture over LEFT side. Average age of patients was 44.3 years. Open fractures were (35%) 18 and Closed fractures were (65%)32. Maximum patients (75%) 38 had a history of major RTA and other (25%) 12 had as history of Trivial fall/ domestic fall . All fractures were of AO type 41A2. [GRAPH-1,2,3,4]

#### Sex distribution

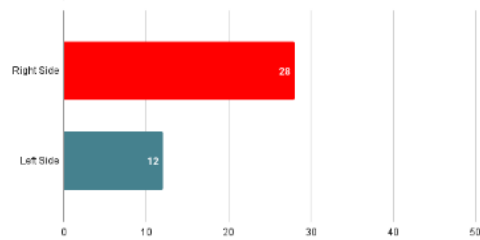
Out of 50 patients



GRAPH 1-SEX DISTRIBUTION

#### Affected side of fracture

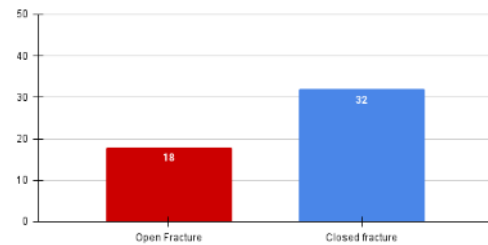
Out of 50 patients



GRAPH 2-AFFECTED SIDE

#### Type of Fracture

Out of 50 patients

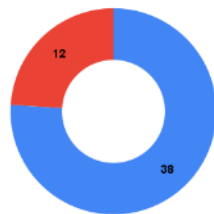


GRAPH 3-TYPE OF FRACTURE

#### Mode of impact

All fractures were of AO type 41A2

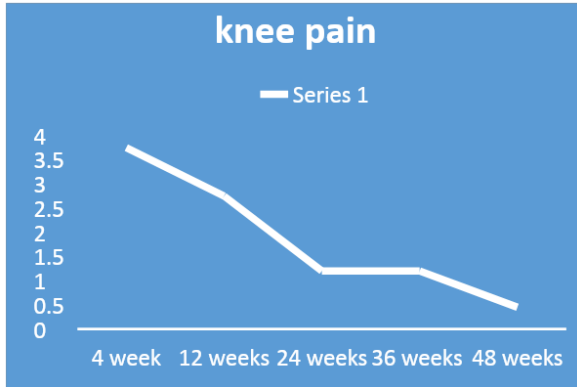
● History of Major RTA ● History of trivial fall / domestic fall



GRAPH 4-MODE OF IMPACT

## 2. KNEE PAIN (VAS score)

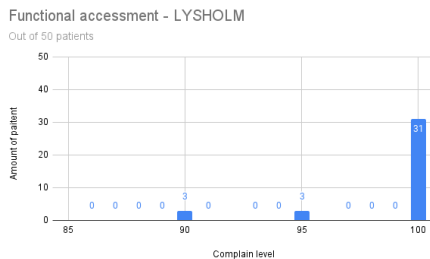
For the post operative assessment of knee pain **VISUAL ANALOGUE SCORE (VAS)** was used, on scale of 0-10 with 10 being the severe and worst feeling of pain and 0 being no pain at all. At 2 years follow up of 50 patients, 38 patient had no complain of any nee pain in any of the quadrant of knee, while 3 patient had a knee pain (VAS = 2) over the superior quadrant at the site of incision and 3 patient had knee pain (VAS = 1) over the lower quadrant of patella below the tibial tuberosity at the fracture site. Rest 6 patients were of old age had started pain with osteoarthritic changes in knee and had knee pain (VAS= 2). Given below is the graphical representation of mean VAS score we have noted throughout our study period in an interval of 1,3,6,9,12 and 24 months.[GRAPH-5]



GRAPH 5-KNEE PAIN

### 3. FUNCTIONAL OUTCOME (Lysholm score)

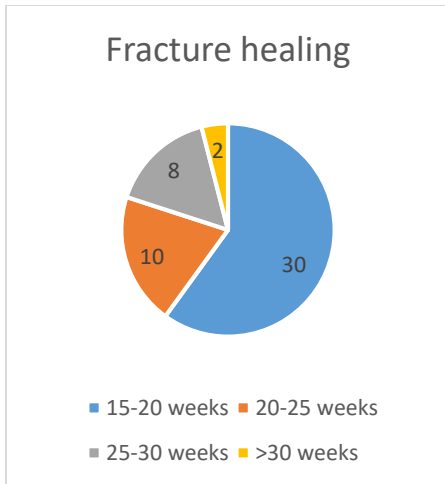
For the functional assessment of knee function the **Lysholm** score is used having general components of limp, need of support, locking of knee, instability in knee, pain over the knee, swelling, ability to climb the stairs, squatting. Assessing 50 patients at 2 year follow-up the mean LYSHOLM score was found to be 97.12, if we take specific difficulties out of 50 patients, **13** patients were still having complain of pain(95,95,90,90,85) , **3** patients were having difficulty in climbing stairs(96) and **3** patient was having difficulty in squatting(92).[GRAPH-6]



GRAPH 6-FUNCTIONAL ASSESMENT SCORE

### 4. HEALING OF FRACTURE (RUST SCORE)

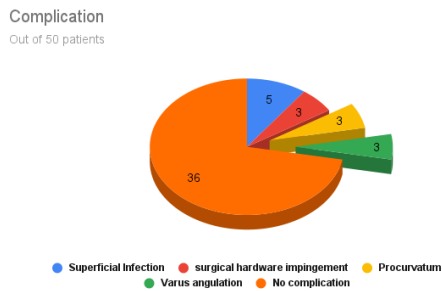
Radiological union of the proximal tibia fracture was assessed after 2 year of postoperative management using **Radiographic union scale in tibia (RUST)**.4 cortex assessment was done i.e. AP & LATERAL view x-rays of all the patients for the proper confirmation of radiological fracture union. The mean radiological union time noted to be as 20.4 (ranging from 16-38 weeks). Out of the 20 patients all but 3 patients fracture had healed (85%). Of this 3 patients due to side addiction history of 3 patients of long term ingestion of smoking and alcohol the RUST score obtained at end of 2 year was 8,10 and 12 respectively for 3 patients.[GRAPH-7]



GRAPH 7-FRACTURE HEALING

#### 5. COMPLICATION:

Every procedure, technique and surgery carries potential risk of complication with itself. In our study of supra-patellar nailing in proximal tibia fracture we encountered some of the short term complication, as our study is of only 1year follow-up of patients selected in retrospect manner. Out of the 50 patients we studied in the 2 year of our data base **5** patient had developed superficial infection over incision site, **3** patient had a surgical hardware (implant) impingement, **3** patient had procurvatum, **3** patient had fracture fixation in varus angulation. [GRAPH-8]



GRAPH 8-COMPLICATIONS

## DISCUSSION

Our study evaluated the functional and radiological outcomes, as well as the technical aspects, of treating proximal third extra-articular tibial fractures, classified according to the AO/OTA system, with the supra-patellar nailing technique. At the most recent follow-up, nearly all fractures had united, achieving satisfactory functional outcomes. Proximal third tibial fractures, which account for 6-12% of all tibial fractures, are typically the result of high-energy trauma and are often associated with significant soft tissue and systemic injuries. Due to their peri-articular location, achieving precise anatomical alignment is crucial for optimal functional restoration.

While open reduction and plate osteosynthesis can restore anatomical alignment, these techniques often fail to achieve satisfactory functional outcomes due to associated complications. In contrast, intramedullary nailing offers several advantages, including minimal soft tissue disruption, load-sharing properties, a minimally invasive approach, reduced blood loss, and early partial weight-bearing. These benefits have led to promising outcomes with this technique. However, traditional infrapatellar nailing has been associated with higher rates of malunion, nonunion, and other complications, largely due to the limitations of older nail designs and difficulties inherent to the infrapatellar approach. These difficulties include issues with medial and posterior entry, which can lead to malalignment and increased anterior knee pain.

Recent improvements in nail design, including a reduced Herzog's bend and multiple proximal locking options, have addressed many of the complications associated with traditional infrapatellar nailing. The supra-patellar approach, recommended by studies such as those by Tornetta and Eastman, circumvents the complications associated with hyperflexion and improper entry seen in the infrapatellar technique. This results in better alignment, fewer instances of anterior knee pain, and a lower risk of intra-articular damage.

Our study, which focused on a homogeneous group of extra-articular fractures (41 A2 type) treated with supra-patellar nailing, demonstrated functional outcomes that were comparable to or exceeded those reported in the literature, with fewer complications. Notably, despite some patients requesting implant removal, no cases of anterior knee pain were reported post-removal.

A systematic review and meta-analysis by Timothy W. Packer et al. demonstrated superior Lysholm knee scores for the supra-patellar approach, with greater entry point accuracy and reduced fluoroscopy exposure, while maintaining an equivalent risk of complications compared to the infrapatellar approach [11]. Similarly, Lim et al. compared the outcomes of the supra-patellar nail to those of locking plate fixation, finding that the supra-patellar intramedullary nailing group achieved comparable results in terms of radiological alignment and complications [12]. Given the association of proximal tibial fractures with high-energy trauma and significant soft tissue damage, we believe that supra-patellar intramedullary nailing offers a promising alternative.

Ponugoti et al.<sup>13</sup> shows that suprapatellar nailing is associated with reduced post-operative pain scores and improved functional outcomes. The data suggest no significant difference in terms of operative times, fluoroscopy times, rates of deep infection, non-union or secondary procedures when compared to infrapatellar techniques. Further studies are required to confirm these findings and assess long-term results

## Limitations

The primary limitations of our study include its retrospective design, the absence of a control group, and the relatively short follow-up period. These factors may limit the ability to capture long-term outcomes, such as the development of post-traumatic arthritis. However, our study benefits from a single-center design, standardized treatment protocols, a trauma-trained surgeon, and adequate follow-up. Additionally, malalignment was assessed using measurements of the normal contralateral tibia rather than fixed values, improving the accuracy of our assessment [Table-3].

TABLE: 3 Vas Score showing Normal contralateral tibia

	<u>VAS -SCORE</u>	<u>UNION TIME</u>	<u>LYSHOLM - SCORE</u>	<u>LEFS</u>
<u>OUR STUDY</u>	<b><u>0.45</u></b>	<b><u>5 MONTHS</u></b>	<b><u>97.12</u></b>	=
<u>STUDY 1</u> (11 PATIENTS)	<b><u>0.18</u></b>	=	<b><u>89.9</u></b>	-
<u>STUDY 2</u>	<b><u>0.05</u></b>	<b><u>8 MONTHS</u></b>	<b><u>82.14</u></b>	=
<u>STUDY 3</u> (60 PATIENTS)	<b><u>0.00</u></b>	<b><u>7.3 MONTHS</u></b>	=	<b><u>89.4</u></b>
<u>STUDY 4</u> (32 PATIENTS)	<b><u>0.20</u></b>	<b><u>12.45 MONTHS</u></b>	<b><u>95</u></b>	=
<u>STUDY 5</u> (62 PATIENTS)	<b><u>0.20</u></b>	<b><u>5 MONTHS</u></b>	<b><u>88.2</u></b>	

## CONCLUSION

It is very wise and thoughtful to use suprapatellar nailing in proximal 1/3<sup>rd</sup> tibial fracture as it gives us excellent results in terms of clinical, functional, and radiological outcomes. We recommend the supra patellar nailing with current and advanced surgical principles and proper instruments systems. The technique has the added advantage for proximal 1/3<sup>rd</sup> tibia fracture in terms of positioning, placement of nail entry. And other disadvantages of conventional infrapatellar nailing are omitted using this technique. Suprapatellar nailing for proximal third tibial fractures offers superior clinical, functional, and radiological outcomes, adhering to advanced surgical principles and utilizing contemporary instrumentation. This technique enhances nail entry and positioning while mitigating the drawbacks associated with conventional infrapatellar nailing. However, our study highlights that the learning curve for suprapatellar nailing is notably steep and progresses slowly. It is imperative for novice surgeons to thoroughly understand the fundamental principles, knee joint anatomy, and to employ a well-supported zig system for optimal results in suprapatellar tibial nailing.

**Consent:**

As per international standards or university standards, patient(s) written consent has been collected and preserved by the author(s).

**COMPETING INTERESTS:**

Authors have declared that they have no known competing financial interests OR non-financial interests OR personal relationships that could have appeared to influence the work reported in this paper.

**Disclaimer (Artificial intelligence)****Option 1:**

Author(s) hereby declare that NO generative AI technologies such as Large Language Models (ChatGPT, COPILOT, etc.) and text-to-image generators have been used during the writing or editing of this manuscript.

**Option 2:**

Author(s) hereby declare that generative AI technologies such as Large Language Models, etc. have been used during the writing or editing of manuscripts. This explanation will include the name, version, model, and source of the generative AI technology and as well as all input prompts provided to the generative AI technology

**Details of the AI usage are given below:**

- 1.
- 2.
- 3.

**REFERENCES**

1. Franke J, Hohendorff B, Alt V, Thormann U, Schnettler R. Suprapatellar nailing of tibial fractures– Indications and technique. Injury. 2016 Feb 1;47(2):495-501.
2. Githens M, Bishop J. Complex tibial fractures: tips and tricks for intramedullary nail fixation. Clinical Medicine Insights: Trauma and Intensive Medicine. 2014 Jan;5:CMTIM-S12264.

3. Sanders RW, DiPasquale TG, Jordan CJ, Arrington JA, Sagi HC. Semiextended intramedullary nailing of the tibia using a suprapatellar approach: radiographic results and clinical outcomes at a minimum of 12 months follow-up. *Journal of orthopaedic trauma*. 2014 May 1;28(5):245-55.
4. Tornetta P, Collins E. Semiextended position for intramedullary nailing of the proximal tibia. *Clinical Orthopaedics and Related Research*®. 1996 Jul 1;328:185-9.
5. Tornetta III P, Riina J, Geller J, Purban W. Intraarticular anatomic risks of tibial nailing. *Journal of orthopaedic trauma*. 1999 May 1;13(4):247-51.
6. Eastman J, Tseng S, Lo E, Li CS, Yoo B, Lee M. Retropatellar technique for intramedullary nailing of proximal tibia fractures: a cadaveric assessment. *Journal of orthopaedic trauma*. 2010 Nov 1;24(11):672-6.
7. Byrne JP, Nathens AB, Gomez D, Pincus D, Jenkinson RJ. Timing of femoral shaft fracture fixation following major trauma: a retrospective cohort study of United States trauma centers. *PLoS medicine*. 2017 Jul 5;14(7):e1002336.
8. Sekimpi P, Okike K, Zirkle L, Jawa A. Femoral fracture fixation in developing countries: an evaluation of the Surgical Implant Generation Network (SIGN) intramedullary nail. *JBJS*. 2011 Oct 5;93(19):1811-8.
9. Tegner YE, Lysholm JA. Rating systems in the evaluation of knee ligament injuries. *Clinical Orthopaedics and Related Research (1976-2007)*. 1985 Sep 1;198:42-9.
10. Delgado DA, Lambert BS, Boutris N, McCulloch PC, Robbins AB, Moreno MR, Harris JD. Validation of digital visual analog scale pain scoring with a traditional paper-based visual analog scale in adults. *JAAOS Global Research & Reviews*. 2018 Mar 1;2(3):e088.
11. Packer TW, Naqvi AZ, Edwards TC. Intramedullary tibial nailing using infrapatellar and suprapatellar approaches: a systematic review and meta-analysis. *Injury*. 2021 Mar 1;52(3):307-15.
12. Lim, S., Song, H.K., Kim, T.H. *et al.* Comparison of suprapatellar intramedullary nailing versus minimal invasive locked plating for proximal tibia fractures. *Arch Orthop Trauma Surg* **143**, 7009–7017 (2023).
13. Ponugoti, N., Rudran, B., Selim, A. *et al.* Infrapatellar versus suprapatellar approach for intramedullary nailing of the tibia: a systematic review and meta-analysis. *J Orthop Surg Res* **16**, 94 (2021).