

## Original Research Article

# ISOLATION AND IDENTIFICATION OF DERMATOPHYTES FROM ANIMALS IN THE MALWA REGION OF PUNJAB: A PRELIMINARY STUDY

### ABSTRACT:

**Aim and scope:** In recent decades, there has been an increase in the incidence of dermatophytosis among humans, especially those who are in close contact with animals. It is caused by one of the dermatophyte groups causing superficial mycoses in both humans and animals. *Trichophyton* and *Microsporium* spp are the most common genera responsible for skin infection in animals. Despite reports of dermatophytes from various regions, there is increasing evidence of geographical variation in fungal species, their spread to new areas, and growing resistance to antifungal treatments. The ability of these infections to transmit from animals to humans underscores the need for vigilance and proactive management. Addressing this issue can help protect animal and human health, making early detection and treatment vital in preventing outbreaks and ensuring overall well-being. Hence, we conducted a preliminary study on the incidence of dermatophytosis in animals of the Malwa region with a hot-humid climatic condition and a large animal population.

**Study design:** Purposive sampling was done and samples were subjected to isolation and identification of dermatophytes.

**Place and Duration of study:** The study was conducted in the Malwa region of Punjab state, India from July 2021 to June 2023.

**Methodology:** Samples (n=51) from various animal species were examined for fungal infection by direct microscopy (10% KOH). Fungal isolates were cultured on Sabouraud's dextrose agar (SDA) and Dermatophyte test medium. Microscopic and macroscopic identification of dermatophytes was performed.

**Results:** Of the 51 clinically suspected dermatophytosis cases, 27 (52%) were found positive by KOH preparations. *Trichophyton* spp were isolated from 11 (40%) samples demonstrating their significant presence among animals. The results of the present study highlight the incidence of dermatophyte infections in animals within the Malwa region, offering valuable insights into the prevention and control of dermatophytosis in both animals and humans. This information is a critical reference for public health strategies and underscores the importance of effective monitoring and managing dermatophytosis in animals and humans.

**Keywords:** Dermatophytosis, Phenotypic, hot-humid climate, Microspore, Zoonotic.

## 1. INTRODUCTION:

Microbial infections seriously threaten public health, and the mortality rate from drug resistance is rising worldwide. Likewise, mycotic diseases are increasingly prevalent and developing resistance to antifungal agents. Over the decades, these infections have increased significantly, affecting around 20-25% of the global population (Kim et al., 2015). The increase in fungal infections can be attributed to various factors such as climate change, pandemics, drug resistance, population growth, and longer life spans (WHO, 2022). In contrast to the considerable attention directed towards bacterial and viral infections, fungal infections are relatively neglected. Fungal infections include a variety of diseases, ranging from superficial mycoses like dermatophytosis and candidiasis to invasive deep-tissue infections caused by *Cryptococcus* and *Blastomyces* (Moskaluk and Vande Woude, 2022). Confirmatory diagnosis of these infections can take weeks, and treatment often requires longer therapy duration. Among these infections, superficial mycoses caused by dermatophytes are typically self-curing in healthy animals but may have zoonotic potential (Łagowski et al., 2019). Among the various groups of dermatophytes (anthropophilic: zoophilic and geophilic), zoophilic dermatophytes are the major fungi causing superficial mycoses in animals (Moskaluk & VandeWoude, 2022). There are seven genera of dermatophytes currently characterized and the important genera *Trichophyton*, *Microsporum*, and *Epidermophyton*, are keratinophilic fungi that produce keratinase enzymes to digest the keratin present on the nails, skin, and hair. This enzymatic reaction can attract inflammatory cells, leading to an inflammatory response at the site of infection, resulting in severe itching and tissue damage. Timely diagnosis and treatment are crucial for a positive outcome as they can cause high morbidity and indirect psychological effects.

Lifestyle changes and increased interaction with pets, farms, and wild animals have impacted the epidemiology of zoonotic dermatophytosis (Ameen, 2010). Report on epidemiological studies on anthropophilic fungi shows the changing trends of various etiological agents of superficial mycoses (Ameen, 2010, Verma et al., 2021, Kumar et al., 2023). Similar studies of prevalence and epidemiological trends of zoophilic fungi may provide knowledge about the major genera circulating in animals which further improve the understanding of risk factors associated with mycoses (Lopes et al., 2024). Humans and animals in tropical and subtropical regions are more vulnerable to superficial mycosis, and increasing interactions between them may serve as a potential source of zoonotic infections. Hence, identifying the etiologic agent and the pattern of skin infection is a reliable indicator of health status in humans and animals, enabling timely intervention and effective management of the infection (Krishnan and Almheiri, 2024). Manoyan et al. (2024) emphasise the need for systematic monitoring of dermatophytosis in animals to develop a methodology for assessing the transfer of pathogenic dermatophytes common to humans

and animals. A survey on dermatophytes in dogs and cats reported the high prevalence of *T. mentagrophytes* and *M. canis* (Fratti, et al., 2023, Nehru et al., 2024) which indicates that pet animals are potential carriers of dermatophytes. Suleiman et al. (2017) employed various methods and techniques to identify useful molecular markers for detecting dermatophytes in donkeys. Therefore, a preliminary study was envisaged to detect the incidence of dermatophytes in animals of the Malwa region of Punjab. This region has various species of animals and agriculture farming is one of the main occupations. The data on dermatophytes of animals in Punjab especially in the Malwa region is scarcely available. Hence, the studies on dermatophytosis are dire necessary to understand the depth of these neglected infections in animals and the outcome of the study will provide insight into the zoonotic potential of dermatophytes in animals of the Malwa region of Punjab.

## **2. MATERIALS AND METHODS:**

### **2.1 Collection of clinical samples:**

The study was conducted in the Malwa region of Punjab state, India and the animals were presented at TVCC, College of Veterinary Science, Rampura Phul, from July 2021 to July 2023. The samples were collected by purposive sampling in which livestock and pet animals with clinical signs of superficial mycoses such as itching, alopecia, scaling areas, and red rashes with round skin lesions were included.

The Skin scrapings and hair sample(s) were aseptically collected from 51 animals comprised of various species and submitted for microbiological evaluation. The animal species included in the study were Canine (n=35), Caprine (n=3), Bovine (n=5), cats (n=2) and rabbits (n=6). After swabbing the sight with 70% ethanol, hairs were plucked from the periphery of round lesions. Skin scrapings were collected aseptically from the borders of the round lesion using a sterile scalpel blade and collected in a sterile container. The samples were submitted to the Department of Veterinary Microbiology, College of Veterinary Science, Rampura Phul for Laboratory investigation.

**2.2 Direct examination of the clinical specimen by 10% KOH:** The samples were processed with a few drops of 10% KOH and kept at room temperature for 5-10 minutes for the digestion of keratinous tissues. The processed samples were observed under the low power objective of the microscope (10X and 40X magnification) for preliminary identification of fungal elements such as hyphae, microspores (ectothrix and endothrix) and arthrospores.

**2.3 Isolation of organism:** The sample found positive for fungal elements (spores/hyphae) was inoculated on Sabouraud's dextrose agar (SDA) supplemented with chloramphenicol and cycloheximide (Himedia) and Dermatophyte test medium (DTM) containing Dermato supplement (Himedia). All the inoculated plates were incubated at

27°C for 21-28 days and observed daily for fungal growth. Culture plates that showed no visible colonies after 28 days were deemed negative.

## 2.4 Identification of isolated fungal organism

### *Phenotypic identification*

*Macromorphological examination:* The isolated fungal colonies were observed for their growth rate, consistency, surface/or reverse colour and colour change in the DTM.

*Microscopic examination:* The obtained colonies were examined under a microscope using lactophenol cotton blue (HiMedia) staining for observation of microconidia and macroconidia, septate hyphae, and chlamydospores (Begum and Kumar, 2020).

## 3.RESULTS AND DISCUSSION:

The present study was conducted to isolate and identify the dermatophytes from the suspected cases of mycoses in animals. Alopecia with erythematous round lesions were the most observed clinical sign along with other symptoms like itching, weight loss, anorexia etc. It was found that most of the clinical cases were presented from March to September. This agrees with previous studies suggesting that hot, humid and rainy seasons favour the growth of dermatophytes in humans and animals (Segal and Elad, 2021).

**3.1 Direct examination of the clinical specimen by 10% KOH:** Out of 51 samples, 27 (52%) were found positive by direct microscopic examination by 10% KOH preparations. In the present study, animals of all ages and sex were found susceptible to infection, and most were young animals between 1-3 years of age. Out of 32 young animals, 15 were found positive by the KOH method and obtained 6 isolates (Table 1). The majority of clinical cases were reported in dogs, and out of 35 cases, 21 were found to be positive by the KOH method. Although the number of animals from other species in the study was smaller than that of dogs, these animals were also found to be positive for fungal elements. Direct microscopic examination showed characteristic fungal microspores and elements like refractile bodies, and branching septate hyphae (Fig 1.a) which suggest dermatophytes. Among the different types of samples, hair was found to be the most frequently affected. Multiple outgrowths of fungal elements and arthrospores indicate fungal involvement in the skin infection. Conventional methods for identifying dermatophytes involve detecting fungal elements through direct microscopy of clinical specimens and isolating them on specific culture media. Identifying fungal elements by direct microscopic method may not be conclusive for dermatophytosis as there may be other nonspecific/contaminant fungal agents. Hence, fungal species may be confirmed by isolating fungi on a selective culture medium (Lopes *et al.*, 2024) and further molecular characterization.

**3.2 Isolation of organism:** Out of 27 KOH-positive samples, 11 isolates of dermatophytes were obtained on DTM (40.74%). The growth of fungal colonies was observed after 8-9 days and radially expanded on extended incubation. Fungal growth was observed in both DTM and SDA medium. The characteristic yellow-to-red colour change in the medium was observed when a fluffy white-coloured colony formed on DTM (Fig.1.b and c). **The growth characteristic on SDA and DTM suggests that the isolated colonies may be *Trichophyton* spp. Similar findings were reported by Baumbach et al. (2021).**

The presence of antibacterial and antifungal agents in the DTM such as chloramphenicol, gentamicin, and cycloheximide prevent/inhibit the growth of contaminating bacteria and saprophytic fungi (Byrne, 2014). The pH of the medium will change to alkaline by the metabolic activity of dermatophytes, giving a characteristic red colour (Greenacre, 2017). The time of colour change is also important as contaminating fungi can change the colour after a long incubation period (Hnilica and Patterson, 2017). Hence, the observation time at which colour change is initiated is significant in identifying dermatophytes. Further microscopic characterization of the isolated colony was done by staining with lactophenol cotton blue which showed septate hyphae, microspores, segmented arthroconidia, and macroconidia (Fig.1.d). **Coiled hyphae along with intercalating chlamydospores are suggestive of *Trichophyton* spp. (Begum and Kumar, 2020)** Few macroconidia were observed in isolated cultures. This could be because dermatophytes grown on DTM may not have adequate conidial production for identification. The different culture media like rice agar, oatmeal agar and potato dextrose agar were reported to be used for macroconidia production. Though, MAT agar was found to be best for conidia production (Achterman et al., 2011). Even though the gold standard method for the identification is isolation and characterisation, KOH preparation of clinical specimens can be considered for the preliminary identification of dermatophytes in resourceless laboratories. It is a simple and cost-effective method that clinicians can use to begin treatment before the culture reports are available, which often take several days to weeks. Taha et al., 2016 suggest that advanced molecular methods like PCR, RFLP etc. are rapid but too expensive for the regular diagnosis. **Fratti et al. (2023) studied the effectiveness of the direct mycological examination of skin and hair samples from animals and suggested that it may provide an idea of the potential dermatophyte species to incriminate, depending on the animal, and may already draw attention to the risk of contracting dermatophytosis**

Gupta et al., 2021 report the high prevalence and increasing trend of dermatophytosis among humans. They also suggest that the hot-humid climatic conditions and occupation of the people of the Malwa region are contributing factors to the growing incidence of dermatophytosis. This region of Punjab has a significant population of animals of various species, which play a crucial role in the local economy. The residents of this

area primarily rely on livestock farming as a key source of income. The present study identified a significant prevalence of mycotic infections among animals in this region (Table 1), particularly from March to September, characterised by hot and humid climatic conditions. The bovine, canine, feline, caprine and rabbit species in this study were infected with dermatophytes. Hence, there may be a correlation between increased dermatophytosis in humans who are in contact with these animals. Several factors that can impact the incidence of dermatophytosis include climate change, natural disasters, chemotherapy, socioeconomic conditions, migration and transportation. Łagowski et al., (2019) isolated *Trichophyton verrucosum* from Lamas and reported the high genetic invariability of the strains isolated from humans and animals. Even though an active infection in animals may not be common, many animals can act as dermatophyte carriers. Incidents of zoophilic dermatophytes among humans are related to the increased prevalence of dermatophytosis in animals. Moreover, increased interaction of humans with wild animals can cause the emergence and re-emergence of zoonotic fungal infection (Segal and Elad 2021; Jkelenstam-Koek et al., 2024).

#### **4. CONCLUSION:**

The preliminary study on the occurrence of dermatophytes in animals of the Malwa region suggests that various species of dermatophytes are circulating among them. Most of the infections were reported during the hot-humid, rainy season. Young animals between the ages of 1 and 3 years were found to be more affected. Direct microscopic examination was found to be effective method for preliminary identification of superficial mycoses, serving as a valuable tool for practitioners in the field. Increased occurrence of dermatophytes in animals may be the reason for rising cases of human dermatophytosis. Our finding shows the importance of region-wise study of dermatophytes and clinicians can take precautionary measures to contain the zoonotic fungal infections. It is also important to educate people to curtail the spread of disease. Current findings indicate the need for a systematic study involving humans and animals, and various factors contributing to dermatophytosis, to determine the actual magnitude of this health issue in the area.

**ACKNOWLEDGEMENTS:** The authors express their gratitude to the authorities of the Guru Angad Dev Veterinary & Animal Sciences University for their essential funding and support in conducting this work.

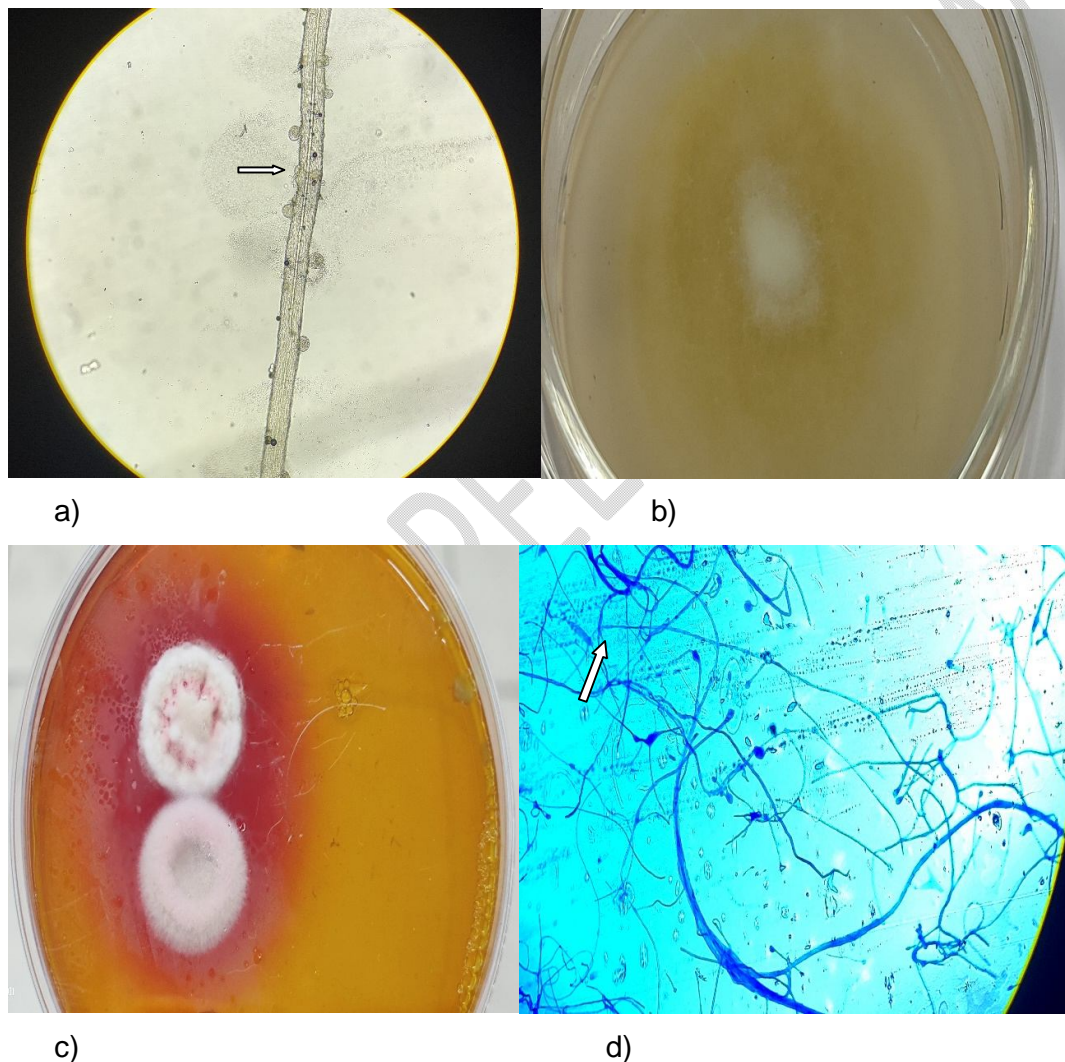
**COMPETING INTERESTS:** Authors declare there is no conflict of interest

**AUTHORS' CONTRIBUTIONS:** S.S.M designed the study, wrote the laboratory protocol, literature search, and wrote the first draft of the manuscript. G.S. collected the data and samples, and N.S.S. analysed the study. All authors read and approved the final draft of the manuscript.

**Data Availability Statement:** The data supporting the findings of this study can be obtained from the corresponding author upon reasonable request.

**Disclaimer (Artificial intelligence)**

Author(s) hereby declare that NO generative AI technologies such as Large Language Models (ChatGPT, COPILOT, etc.) and text-to-image generators have been used during the writing or editing of this manuscript.



**Figure 1.:** Microscopical and Macromorphological identification of Dermatophytes a) 10% KOH preparation of hair sample showing microspores, arthrospores and branching hyphae; b) White fluffy growth on SDA; c) Growth on DTM showing white fluffy colony with a colour change from yellow to red; d) Lactophenol cotton blue staining showing fungal hyphae, micro and macrospores (Arrowhead).

Table 1.: Different animals with age groups included in the present study and Laboratory method used for identification of dermatophytes.

Animals						
No of animals	Dog (n=35)	Cat(n=2)	Cow/Buffalo (n=5)	Goat (n=3)	Rabbit (n=6)	Total Animals (n=51)
KOH Positive	21	1	1	1	3	27 (52.94%)
DTM positive	10				1	11 (40.74%)
SDA positive	10	1	1	1	1	14 (51.85%)
Age						
Age group	1 to 3	4 to 7	8 to 11	Total Animals		
No of animals	32	17	2	51		
KOH Positive	15	10	2	27		
DTM positive	6	4	1	11		

#### References:

1. Achterman, R. R., Smith A. R., Oliver, B.G.&White, T.C. (2011). Sequenced dermatophyte strains: growth rate, conidiation, drug susceptibilities, and virulence in an invertebrate model. *Fungal Genet Biol.*48(3), 335-41. doi: 10.1016/j.fgb.2010.11.010.; Epub 2010 Dec 7.; PMID: 21145410; PMCID: PMC3035951.
2. Ameen M. (2010). Epidemiology of superficial fungal infections. *Clinics in Dermatology*, 28(2),197-201, <https://doi.org/10.1016/j.clindermatol.2009.12.005>.
3. Baumbach, C-M, Müller, S., Reuschel, M., Uhrlaß, S., Nenoff, P., Baums, C.G. et al. (2021). Identification of Zoophilic Dermatophytes Using MALDI TOF Mass Spectrometry. *Front. Cell. Infect. Microbiol.* 11, 631681. doi: 10.3389/fcimb.2021.631681
4. Begum, J. & Kumar, R. (2020). Prevalence of dermatophytosis in animals and antifungal susceptibility testing of isolated Trichophyton and Microsporum species. *Tropical Animal Health and Production* 53(1). doi:10.1007/s11250-020-02476-3
5. Byrne, B. A. (2014). Laboratory Diagnosis of Fungal Diseases. *Equine Infectious Diseases*, 393–399.e1. doi:10.1016/b978-1-4557-0891-8.00046-4

6. Fratti, M., Bontems, O., Salamin, K., Guenova, E. & Monod, M. (2023) Survey on Dermatophytes Isolated from Animals in Switzerland in the Context of the Prevention of Zoonotic Dermatophytosis. *J. Fungi*. 9, 253. <https://doi.org/10.3390/jof9020253>.
7. Greenacre, C. (2017). Avian and Exotic Animal Dermatology In Small Animal Dermatology, 508–574. doi:10.1016/b978-0-323-37651-8.00015-8
8. Gupta, A., Alisha, Saini, R. & Kaur S. (2021). Clinical patterns and epidemiological characteristics of dermatophyte infection in Malwa region of Punjab. *Int J Res Dermatol*. 7, 91-5.
9. Hnilica, K. A. & Patterson, A. P. (2017). Chapter 2 - Diagnostic Techniques In Small Animal Dermatology (4<sup>th</sup> edn), W.B. Saunders. pp30–44. doi:10.1016/b978-0-323-37651-8.00002-x
10. IJkelenstam-Koek, M., de Jager, S. A. & Kemperman, P. M. J. H. (2024). Huidafwijkingen aan de handen door eenstekeligegast [Skin lesions on the hands due to a prickly guest]. *Ned Tijdschr Geneesk*. 21(168), D8114. Dutch. PMID: 39228347.
11. Kim, S. H., Cho, S. H., Youn, S. K., Park, J. S., Choi, J. T., Bak, Y. S. et al. (2015). Epidemiological Characterization of Skin Fungal Infections Between the Years 2006 and 2010 in Korea. *Osong Public Health Res Perspect*. 6(6):341-5. doi: 10.1016/j.phrp.2015.10.012.; Epub 2015 Nov 10.; PMID: 26835243; PMCID: PMC4700767.
12. Krishnan, S. & Almheiri, K. (2024). Pattern of Skin Diseases at a Dermatology Center: A Retrospective Study. *Cureus*. 24:16(7), e65259. doi: 10.7759/cureus.65259. PMID: 39184705; PMCID: PMC11343481.
13. Kumar, P., Ramachandran, S., Das, S., Bhattacharya S. N. & Taneja B. (2023). Insights into Changing Dermatophyte Spectrum in India Through Analysis of Cumulative 161,245 Cases Between 1939 and 2021. *Mycopathologia* 188, 183–202.
14. Łagowski, D., Gnat, S., Nowakiewicz, A., Osińska, M., Trościańczyk, A. & Zięba, P. (2019). In search of the source of dermatophytosis: Epidemiological analysis of *Trichophyton verrucosum* infection in llamas and the breeder (case report). *Zoonoses Public Health* 66, 982–989. <https://doi.org/10.1111/zph.12648>.
15. Lopes, R., Garcês, A., Silva, A., Brilhante-Simões, P., Martins, Â., Cardoso, L., et al. (2024) Dermatophytosis in Companion Animals in Portugal: A Comprehensive Epidemiological Retrospective Study of 12 Years (2012–2023). *Microorganisms* 12, 1727. <https://doi.org/10.3390/microorganisms12081727>
16. Lopes, R., Garcês, A., Silva, A., Brilhante-Simões, P., Martins, Â., Cardoso, L., et al. (2024). Dermatophytosis in Companion Animals in Portugal: A Comprehensive Epidemiological Retrospective Study of 12 Years (2012-2023). *Microorganisms*.

22;12(8),1727. doi: 10.3390/microorganisms12081727.; PMID: 39203570; PMCID: PMC11357242.

17. Manoyan, M. G., Gursheva, A. S., Gabuzyan, N. A. & Panin, A. N. (2024). Dermatophytoses of animals in the Russian regions: etiological structure and sensitivity of pathogens to antifungal drugs. *Sel'skokhozyaistvennayaBiologiya [Agricultural Biology]*, 59 (2), 342-354.
18. Moskaluk, A.E. &VandeWoude, S. (2022). Current Topics in Dermatophyte Classification and Clinical Diagnosis. *Pathogens*. 11(9), 957. <https://doi.org/10.3390/pathogens11090957>. PMID: 36145389; PMCID: PMC9502385.
19. Nehru, B. S., Mohanraj, N., Harish R. K., Kushwanth S. K. P., Sathish K. M., Tanmaie, K. et al. (2024). "Molecular Detection of Dermatophytes Associated With Dermatitis in Dogs of Puducherry, India". *Microbiology Research Journal International* 34 (7), 72-79. <https://doi.org/10.9734/mrj/2024/v34i71459>
20. Segal, E.& Elad, D. (2021) Human and Zoonotic Dermatophytoses: Epidemiological Aspects. *Front. Microbiol.* 12, 713532. doi: 10.3389/fmicb.2021.713532.
21. Suleiman, E. A., Abdalla, W. G., Ahmed, A. H.&Abdelgabar, M. A.(2017). "Isolation and Molecular Characterization of Dermatophytes in Donkeys". *International Journal of Tropical Disease & Health* 26 (4),1-8. <https://doi.org/10.9734/IJTDH/2017/36425>.
22. Tahaa, M., Elfangaryb, M., Essac, S. &Younesa, A. (2017). Species identification of dermatophytes isolated from human superficial fungal infections by conventional and molecular methods. *Journal of the Egyptian Women's Dermatologic.* 14, 76–84. DOI: 10.1097/01.EWX.0000499598.84966.cb.
23. Verma, S. B., Panda, S., Nenoff, P., Singal, A., Rudramurthy, S. M., Uhrlass, S. et al. (2021) The unprecedented epidemic-like scenario of dermatophytosis in India: I. Epidemiology, risk factors and clinical features. *Indian J Dermatol VenereolLeprol.* 87:154-75.
24. WHO (2022). WHO fungal priority pathogens list to guide research, development and public health action report. <https://www.who.int/publications/i/item/9789240060241>