

GONADAL HISTO-MORPHOLOGY AND ENHANCED FERTILITY
POTENTIAL OF *Curcuma Longa* IN MALE STZ-INDUCED DIABETIC RATS

ABSTRACT

Diabetes mellitus is a disorder in which the body fails to produce enough or respond normally to insulin, leading to abnormally high blood sugar levels. The study was aimed at investigating the effects of ethanolic extract of *Curcuma longa* (Turmeric) on fertility profile and gonadal histo-morphology of streptozotocin-induced hyperglycemic male Wistar rats. Semen parameters (count, motility and viability) and testicular histology of streptozotocin "STZ"-induced hyperglycemic male Wistar rats were investigated following the administration of *Curcuma longa* rhizome extract. Twenty-four (24) rats weighing 110-180g were grouped into four. The groups were labelled A to D and contained six rats each. Group A (normal control) rats were given rat pellets and distilled water only. Group B (diabetic control) rats were given 65mg/kg body weight "BW" of streptozotocin IP. Group C served as the standard group and was given 65mg/kg of streptozotocin IP + 250mg/kg of metformin IP, while Group D (test group) rats were given 65mg/kg BW of streptozotocin IP + 500mg/kg of *Curcuma longa* extract. *Curcuma longa* extract was administered through the oral route with the aid of an oro-gastric tube. The administration lasted for twenty-eight (28) days. The rats were then anaesthetized and the testes and semen obtained for histological and semen analysis (sperm count, sperm motility, sperm viability) respectively. The diabetic group showed seminiferous tubules with reduced germinal epithelium and distorted interstitial connective tissue with a significant ($p < 0.05$) reduction in sperm motility, count, viability compared to the normal group that showed normal histological features and normal sperm parameters (motility, count and viability). However, the administration of *C. longa* showed significant ($p < 0.05$) increase in levels of sperm parameters (motility, count and viability) and progressive restoration of histological integrity within the testes.

In conclusion, ethanolic extract of *C. longa* has the potential to reverse the damage caused by hyperglycemia in male reproductive function.

Key words: *Curcuma longa*, semen analysis, testis, diabetes mellitus

INTRODUCTION

Diabetes mellitus “DM” is a metabolic disorder with a characteristic high level of blood sugar (hyperglycemia) over a prolonged period of time and is usually accompanied by disturbed metabolism of proteins and fats (1). Blood glucose rises because it cannot be metabolized in the cells due to lack of insulin production by the pancreas, or the inability of the cells to effectively use the insulin that is being produced (1). Insulin is produced by the beta cells of the pancreas and its function is to regulate the uptake of glucose from blood into the different cells and tissues (2). Three major symptoms of Diabetes mellitus include frequent urination (Polyuria), increased hunger and appetite (polyphagia) and increased thirst (polydipsia) (1). DM is also associated with complications which include diabetic ketoacidosis, cardiovascular disease, foot ulcers, damage to nerves and eyes, encephalopathy, cardiomyopathy (1,3,4) and reproductive dysfunction (5).

The diabetic complications on different cells, tissues and organs have been linked to the reactive oxygen species (ROS) that are generated due to hyperglycemia (6). Prolonged and poorly controlled diabetes has been reported to cause sexual dysfunction in males and females. Sexual dysfunction can also be an early sign of diabetes (7). In males, diabetes mellitus has effects on the endocrine control of spermatogenesis and causes erectile, as well as dysfunction and impaired ejaculation (8). It also negatively impacts sperm parameters such as volume, count, motility and morphology (9). Due to the above-mentioned complications, it became imperative by scientists around the world to find affordable solutions. Studies have shown that to achieve a good metabolic control of diabetes and energy balance, a combination of lifestyle, nutrition, exercise and pharmaceutical treatment are important (10). They are also said to be major factors in the management of diabetes (11).

Pharmaceutically, Metformin is considered to be the first-choice agent for treatment of diabetes (12). Another class of drugs of choice is Sulfonylureas(13). These drugs however are seen to have undesirable side effects. On account of these side effects, there is advocacy for the use of medicinal plants (14), because they have been found to have little or no side effects and are easily affordable and affordable. The use of medicinal plants as an alternative medicine has in the last millennium, been accepted all over the world (15). In the United States of America for instance, about 38% of the population uses herbal medicine (16) and in Turkey, 48.8% of the population are said to use herbal medicines (17) to treat chronic diseases and illnesses. In Africa, the World Health Organization states that at least 80% of the population relies on medicinal plants (18). Some of these plants and herbs possess antioxidant properties. They contain carotenoids, flavonoids, alkaloids, glycosides and some are said to have anti diabetic effects (19). One of such plants is *Curcuma longa* commonly called turmeric.

Curcuma longa, the turmeric plant is commonly used as a spice but has been recognized by the scientific community for its antioxidant property. In Asia, it has been used as a natural therapeutic medicine since ancient times (20). Its main constituent is curcuminoid which gives it a wide range of pharmacological properties including antioxidant, anti-protozoan, anti-venom, anti-inflammatory (21), antibacterial, antidiabetic, antiviral and anticancer activities (19). It would therefore be interesting to evaluate its antidiabetic effects and its effects on the fertility profile of streptozotocin-induced hyperglycemic male Wistar rats.

Infertility affects about 8-12% of couples worldwide and an estimated 50-80 million couples have been reported to suffer from some form of infertility (22). Previously, infertility was thought to be a problem of the females but studies have now shown that 20-30% of infertility

is linked to the males (23) commonly due to poor semen quality or quantity (24). In 2015 it was observed in a study that type 1 diabetic patients showed a lower level of spermatozoa with increased motility, altered mitochondrial function and post ejaculatory dysfunction of the epididymis (8). Diabetes has also shown an increase in prevalence over the years with an estimated 425 million persons worldwide and nearly 50% of that number is not diagnosed (25). Studies have shown that there is a decline in fertility involving males with diabetes, leaving a high percentage of them with reproductive dysfunctions including reduced libido and impotence (5).

STZ is an alkylating agent that causes pancreatic islet β -cell destruction and is widely used experimentally to produce a model of type 1 diabetes mellitus (T1DM) (26). It is a cytotoxic glucose analogue which has been used as a chemotherapeutic agent in the treatment of metastasizing pancreatic islet cell tumors and other malignancies (27) and its effect can be seen within seventy-two hours after administration depending on doses administered (28). STZ has been one of the chemical agents used for the induction of diabetes mellitus in experimental animals. STZ functions as DNA-synthesis inhibitor in bacterial and mammalian cells (29). The selective pancreatic beta cell toxicity and diabetic condition, resulting from STZ induction, is related to the glucose moiety in its chemical structure which enables STZ to enter the beta cell via the low affinity glucose -2- transporter in the plasma membrane (30).

Since diabetes mellitus is said to also cause decline of fertility in males (5), semen analysis is therefore necessary in this study as it serves as a pivotal and indispensable procedure in the assessment of male fertility status (31). When conducted meticulously and in an in-depth manner, it possesses the ability to elucidate the underlying causes contributing to male infertility, thereby offering valuable insights and diagnostic clarity (32). The comprehensive

evaluation of semen encompasses the analysis of diverse parameters, including the measurement of ejaculate volume, quantification of sperm count, assessment of sperm motility and movement patterns, evaluation of sperm morphology and structural integrity, as well as the investigation of the composition and makeup of seminal secretions (32).

MATERIALS AND METHOD

Plant Collection and extract preparation

Rhizomes of *Curcuma longa* (Turmeric) were bought at watt market in Calabar, Cross River State, Nigeria. It was identified and authenticated by a taxonomist in the Department of Botany, University of Calabar, Cross River state, Nigeria and a voucher number (Bot/Herb/UCC/201) was given. The fresh turmeric rhizomes were cleaned, chopped into tiny pieces and air dried for 7days after which they were grounded into powdered form. A measured amount of 950g of powered rhizomes were extracted using 2 liters of 95% ethanol for 24 hours. The extract was first double filtered with Chess cloth, then with filterpaper (Whatman No.1 filter paper). The filtrate (extract) was concentrated under reduced pressure at 45°C in rotary evaporator to 10% volume and then dried in a vacuum water bath, yielding 58.9g (6.2%) of crude extract. The crude extract (paste) obtained was stored in a refrigerator until it was required.

Experimental Animals

Twenty-four (24) adult male Wistar rats with average weight of 160g were used for this research. The rats were kept in clean cages and divided into four groups designated A, B, C and D with six rats in each group. The rats were allowed to acclimatize for two weeks in animal house, University of Calabar and allowed access to commercially available chow (livestock feed) and water.

Experimental Design

Table 1 shows the experimental design of the research. Twenty-four animals were divided randomly into four groups containing six rats each. The groups as shown in the table includes the normal control, diabetic control, standard group and the test(*C.longa* treated) group.

Table 1: Experimental Design

GROUPS	NUMBER OF RATS	TREATMENT
A	6	Normal control (rat chow and distilled water)
B	6	Diabetic control 65mg/kg bw of STZ
C	6	65mg/kg bw of STZ + 250mg/kg.bw metformin
D	6	65mg/kg bw of STZ + 500mg/kg.bw <i>Curcuma longa</i>

Induction of Hyperglycemia

STZ was administered intra-peritoneally to the rats after fasting for twelve hours in order to induce hyperglycemia. The STZ was reconstituted in 0.5M sodium citrate and administered at a dose of 65mg/kgbw (33).

Confirmation of Diabetes Mellitus

Diabetes was confirmed three days after administration of STZ using Accu-Check glucometer with blood samples obtained from tails of the Wistar rats. The blood glucose levels (mg/dl) was checked before and after induction and every seven(7) days during administration of the ethanolic extract of *Curcuma longa* to ascertain hyperglycemic state. It was observed that the

blood glucose of all the animals in the diabetic groups were above 170 mg/dl as compared to that of the normal control which had values less than 91 mg/dl.

Administration of Extract

Curcuma longa extract administration commenced three days after induction of hyperglycemia by oro-gastric intubation which lasted for 28 days.

Termination of Experiment

At the end of treatment period, the experimental animals were weighed and sacrificed through chloroform inhalation. The anterior abdominal wall was incised and semen was extracted from the caudal epididymis for analysis. The testis was then obtained, weighed and preserved in 10% formal saline for tissue processing using hematoxylin and eosin staining method.

Ethical clearance

An approval for the experimental protocol of this study with registration number 220ANA2423 was obtained from the Faculty Animal Research Ethics committee (FAREC-FBMS), Faculty of Basic Medical Sciences, University of Calabar, Cross River state, Nigeria

Determination of weight

All the animals were weighed before and after induction of hyperglycemia and every three days during the course of administration of the extract.

Analysis of sperm parameters

The epididymis was dissected out and placed in a physiological saline in a ratio of 1:10 weight (g) by volume (ml), and was then macerated using surgical blade to release the sperm cells. The suspension was then filtered with 80 μm stainless mesh after pipetting (34). The following sperm parameters were estimated as follows:

i) **Sperm motility (%)**: Two drops of sperm suspension were placed on a clean and labelled microscope slide and covered with a coverslip. This was mounted on light microscope and the number of motile cells divided by the total number of sperm cells counted and was expressed in percentage.

ii) **Sperm viability (%)**: This was done using the eosin-nigrosin staining technique. The sperm suspension was mixed with equal volume of the stain and smeared on glass slides. Live sperm excluded the stain and appeared lightly colored, while dead sperm took up the stain and appeared pink in color. The counts of live sperm were divided by the total number of sperm cells and expressed as percentage.

iii) **Sperm count ($\times 10^6/\text{ml}$)**: Improved neubauer hemocytometer was used for the sperm count. A capillary tube was used to pipette the sperm suspension into the counting chamber of the hemocytometer. The hemocytometer was placed on a light microscope and the counting was estimated by multiplying the number of cells counted by the dilution factor and by the hemocytometer volume.

Histological study using Hematoxylin and Eosin stain “H&E”

The paraffin slides containing testicular tissue underwent a dewaxing process involving two rounds of exposure to xylene for a duration of 5 minutes each. Subsequently, rehydration was performed by sequentially immersing the slides in decreasing concentrations of alcohol

(100%, 95%, and 70%) and rinsing them under tap water. Following rehydration, the sections were subjected to a 15-minute staining procedure using hematoxylin, followed by a 5-minute rinse under tap water. To enhance visualization, the sections were then differentiated in acid alcohol for 1 minute and subsequently counter-stained with eosin for another 1 minute. After a rinse in tap water, the sections underwent dehydration and clearing using xylene. Following this, the sections were allowed to air dry, and a few drops of DPX were applied to the slide surface before placing a coverslip on top. The resulting tissue units were then taken using a digital camera connected to a light microscope for further examination (35).

Statistical Analysis

Data obtained from the experiment was analyzed using one-way Analysis of Variance and Duncan post hoc test using a Statistical Package for Social Science, SPSS version 26.0 for Windows. The results were presented as mean \pm standard error of mean and considered statistically significant at $p < 0.05$.

RESULTS

Assessment of Blood Glucose

The changes in fasting blood glucose “FBG” were determined in this study over the course of the 28-day experimental period and they are presented in figure 1. At day zero, the blood glucose levels in all experimental groups were considered normal ranging from about 70 mg/dl to 107 mg/dl. From the results, it can be observed that elevated blood glucose concentration was seen in all diabetic groups following the administration of 65mg/kg body weight of STZ. The elevated FBG level (Figure 1) of the diabetic control group only exhibited an increase ($p < 0.05$) of -24.40 ± 26.61 mg/dl (gotten by subtracting the final FBG level from

the initial FBG level after induction with diabetes mellitus), while that of the metformin and extract treated groups had significantly decreased FBG levels of $227.60 \pm 24.32 \text{ mg/dl}$ and $236.60 \pm 25.14 \text{ mg/dl}$ respectively ($p < 0.05$).

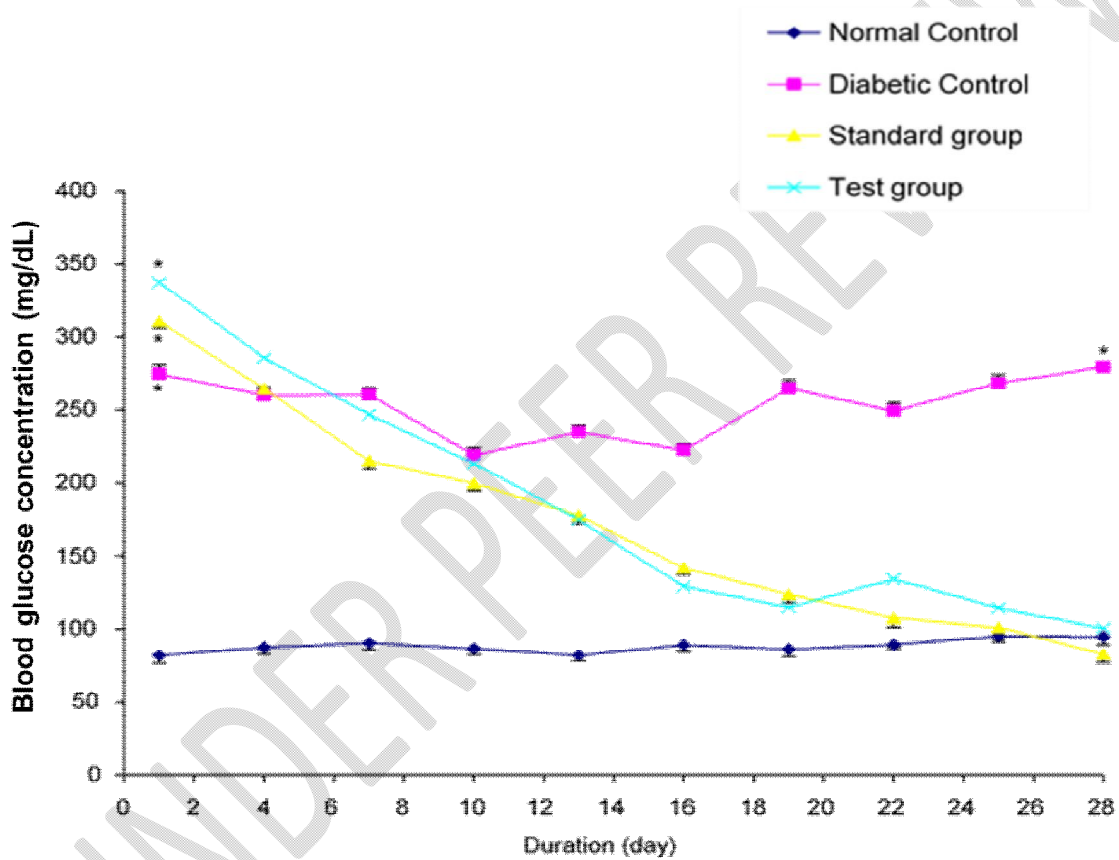


Figure 1: Daily blood glucose levels of the different experimental groups.

Values are expressed as mean +SEM, n = 6

* = significantly different from normal control at $p < 0.05$

Assessment of Body Weight

The results of changes in the body weight of experimental animals after 28 days' period were assessed. The initial and final weights across the 28-day period are presented on figure 2. Observed from these results was a significant ($p < 0.05$) reduction in body weight of the experimental rats induced with diabetes (-37.00 ± 5.75 g) after subtracting the final weight from the initial weight of the rats. The normal control group A had a significant increase of $+20.00 \pm 1.14$ g. On treatment with the test drug (metformin), a weight increase of $+0.80 \pm 1.80$ g was observed, while that of the *Curcuma longa* extract was a decrease of -1.20 ± 2.08 g ($p < 0.05$)

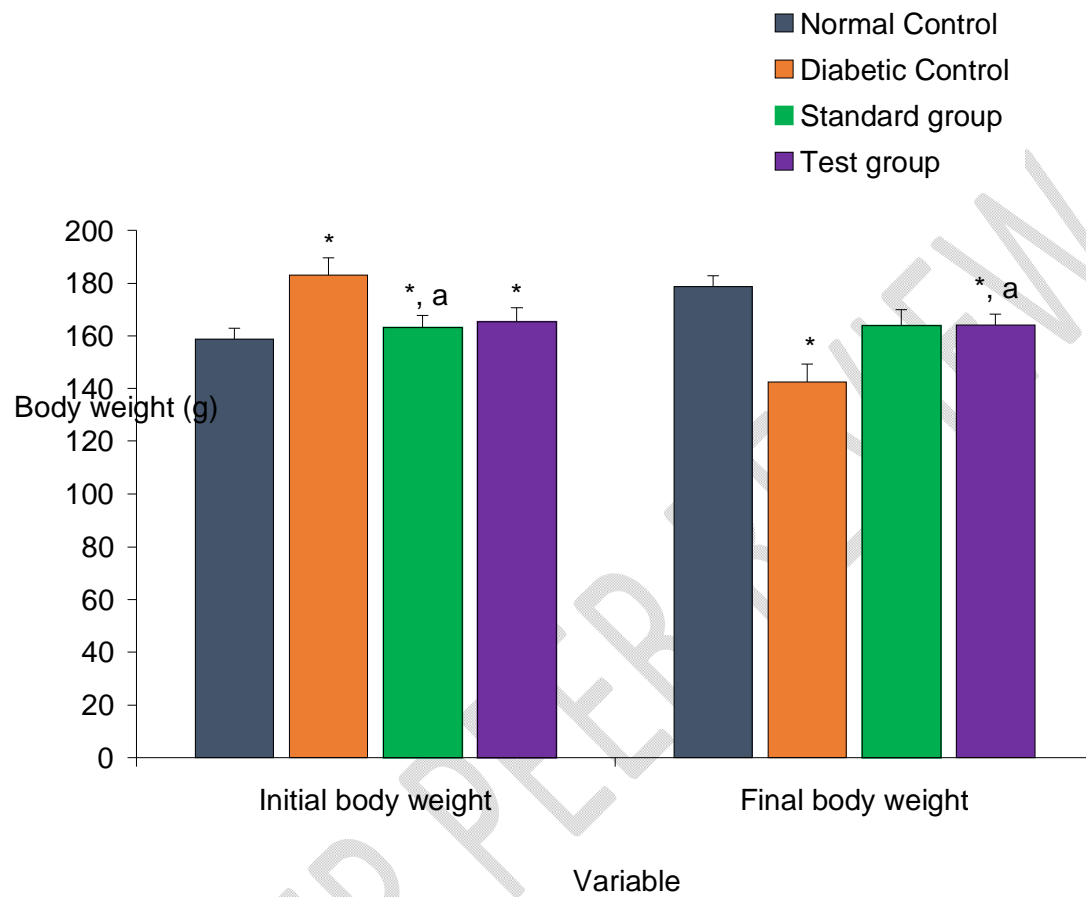


Figure 2: Initial and final body weights of the different experimental groups.

Values are expressed as mean +SEM, n = 6.

* = significantly different from control at $p < 0.05$

a = significantly different from diabetic control at $p < 0.05$

SEMEN ANALYSIS

Sperm Count

Results showed a significant ($p < 0.05$) decrease of 37.70 ± 7.5 million/ml and 47.10 ± 1.7 million/ml of sperm count in the diabetic control and metformin treated groups respectively compared to the normal control group that had 69.6 ± 1.5 million/ml sperm count. However, 65.40 ± 1.4 million/ml of sperm count was recorded in Group D animals (administered with 500mg/kg.bw of *C. longa*). This increase in sperm concentration was statistically significant when compared with the diabetic control ($p < 0.05$) (Figure 3).

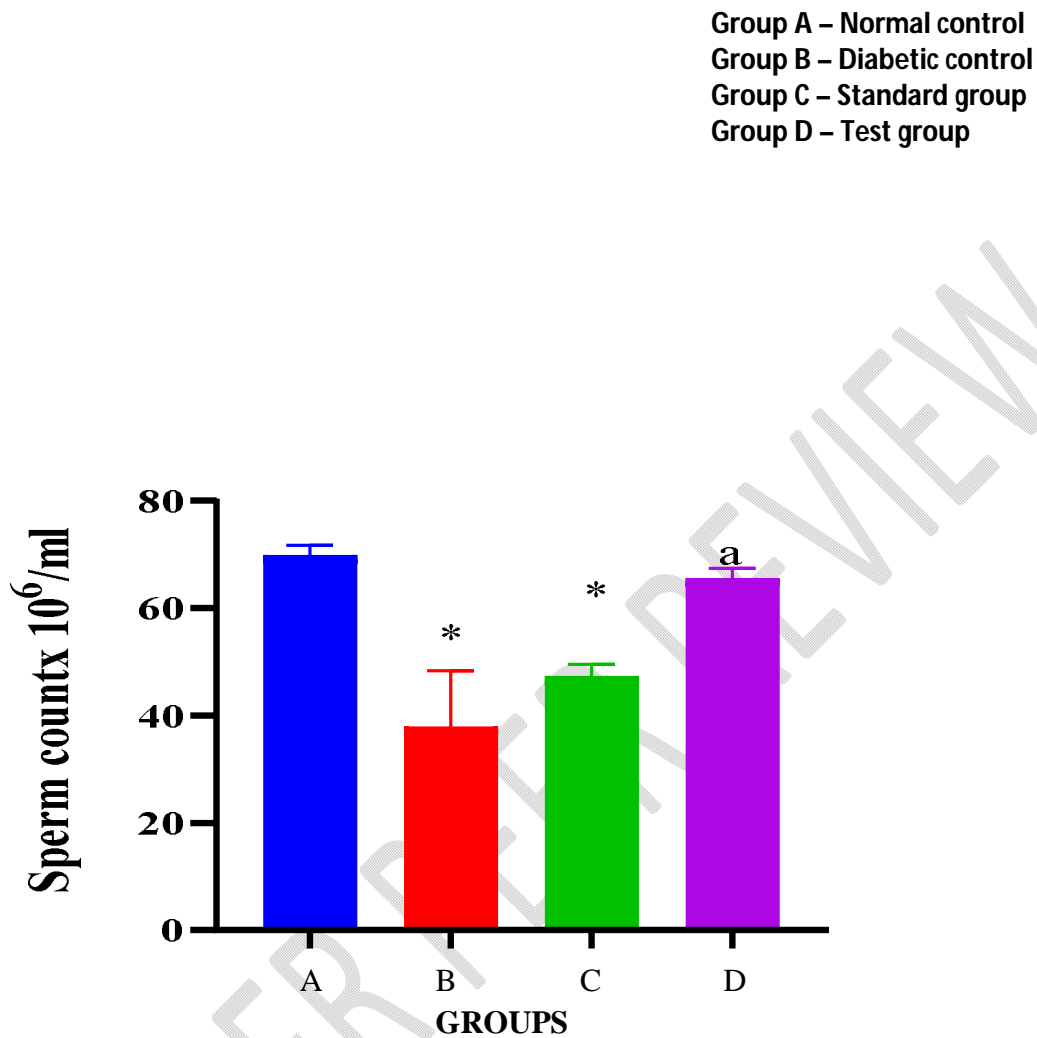


Figure 3: Sperm count in the different experimental groups.

Values are expressed in Mean \pm SEM. N = 6.

* = Values are significantly decreased compared to Normal Control ($p < 0.05$).

a = Values are significantly increased compared to Diabetic Control at $p < 0.05$.

Sperm Motility

Figure 4 shows the result of sperm motility for the experimental animals. Animals in the diabetic control group and the group treated with metformin recorded significant decrease in sperm motility values when compared with the normal control group ($p < 0.05$). However, Group D animals (placed on 500 mg/kg.bw of *C. longa*), showed an increase in sperm motility which was statistically significant when compared with the diabetic control and the metformin treated group.

UNDER PEER REVIEW

Group A – Normal control
Group B – Diabetic control
Group C – Standard group
Group D – Test group

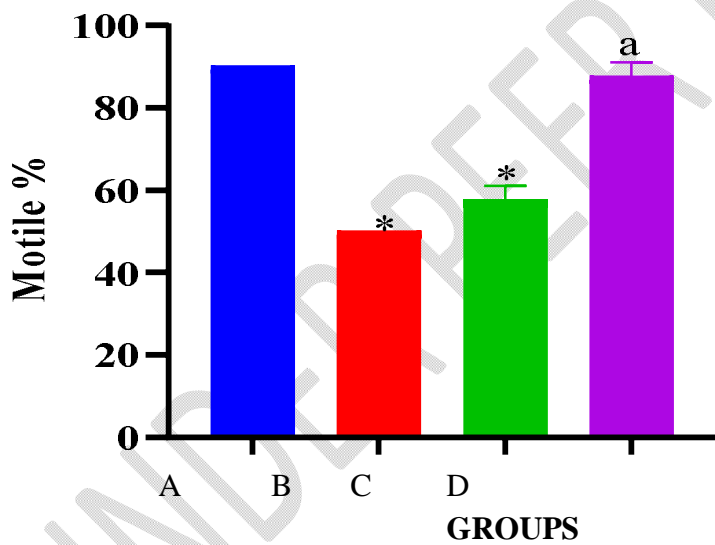


Figure 4: Sperm motility in the different experimental groups.

Values are expressed in Mean \pm SEM. N = 6.

* = Values are significantly decreased compared to Normal Control ($p < 0.05$).

a = Values are significantly increased compared to Diabetic Control ($p < 0.05$).

Sperm Viability

Experimental animals in the diabetic control group and the group placed on metformin recorded low sperm viability values which was significantly decreased when compared with the normal control group ($p < 0.05$). However, Group D animals (placed on 500mg/kg.bw of *C. longa*), showed an increase in sperm viability of which was statistically significant when compared with the diabetic control (Figure 5).

UNDER PEER REVIEW

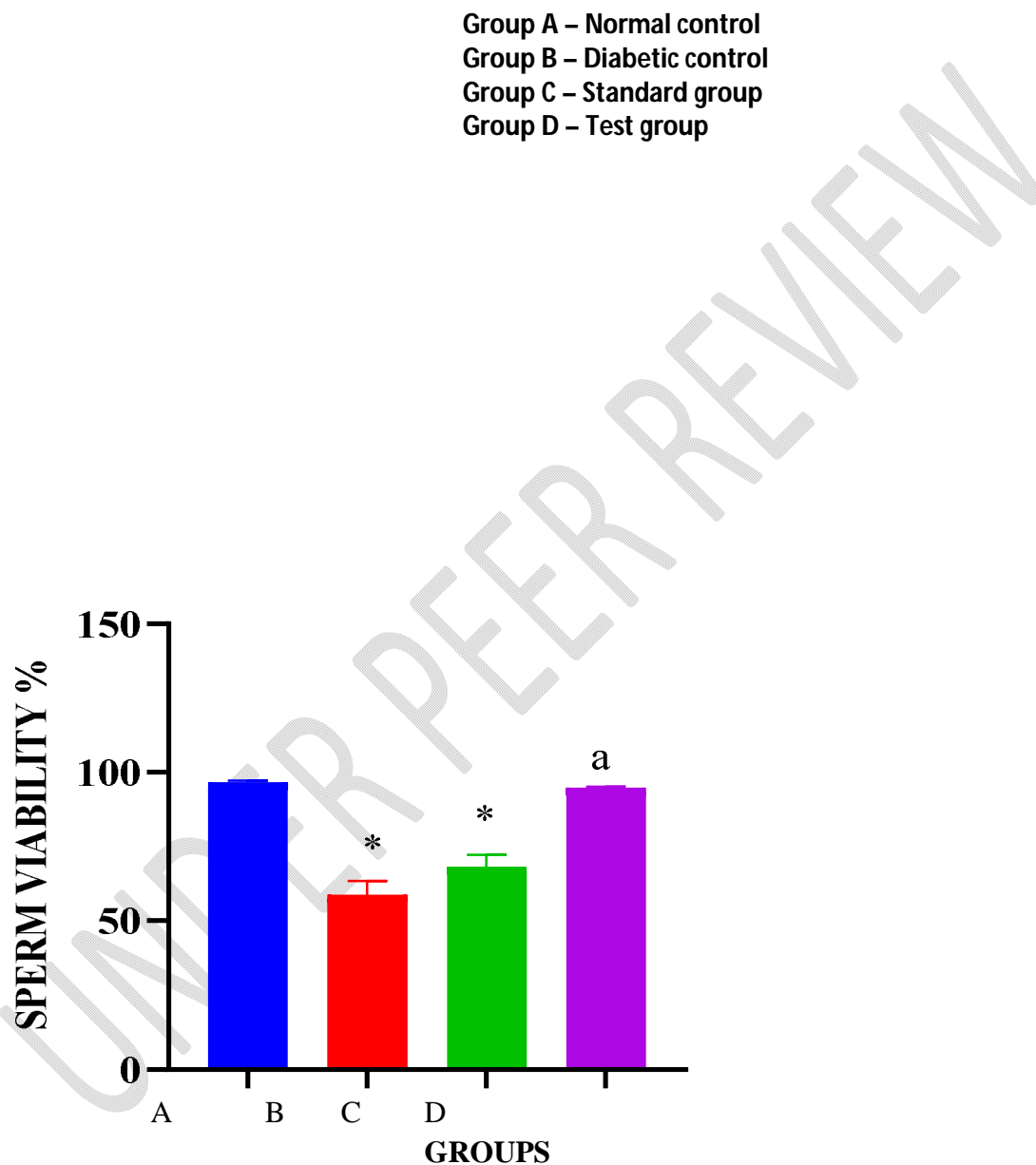


Figure 5: sperm Viability in the different experimental groups.

Values are expressed in Mean \pm SEM. N = 6.

* = Values are significantly decreased when compared to Normal Control at $p < 0.05$.

a = Values are significantly increased when compared to Diabetic Control at $p < 0.05$.

Histological observations

Histological study on sections of testes in the normal control group (X400) showed prominent seminiferous tubules with regular and consistent cellular arrangements on the germinal epithelium. The lumens of seminiferous tubules were filled with flagella of newly formed spermatozoa. Their basement membranes were intact and the intervening interstitium which contained blood vessels and clusters of Leydig cells showed regular pattern (Plate 1).

Section of testes from the diabetic control group (Group B) showed significant alteration in histological patterns in the testes when compared with the normal control. Irregular shaped seminiferous tubules with shrunken lumen and decreased tubular diameter were observed (Plate 2).

Section of testes in the diabetic animals treated with metformin (Group C) showed normal seminiferous tubules although its germinal epithelium was distorted with differentiating cells arranged in a coarse pattern. The interstitial connective tissue was distorted (plate 3).

For the test group treated with 500mg/kg.bw of *C. longa*, seminiferous tubules were prominent and intact with basement membrane. The interstitial connective tissue was distorted, but there is progressive restoration observed.

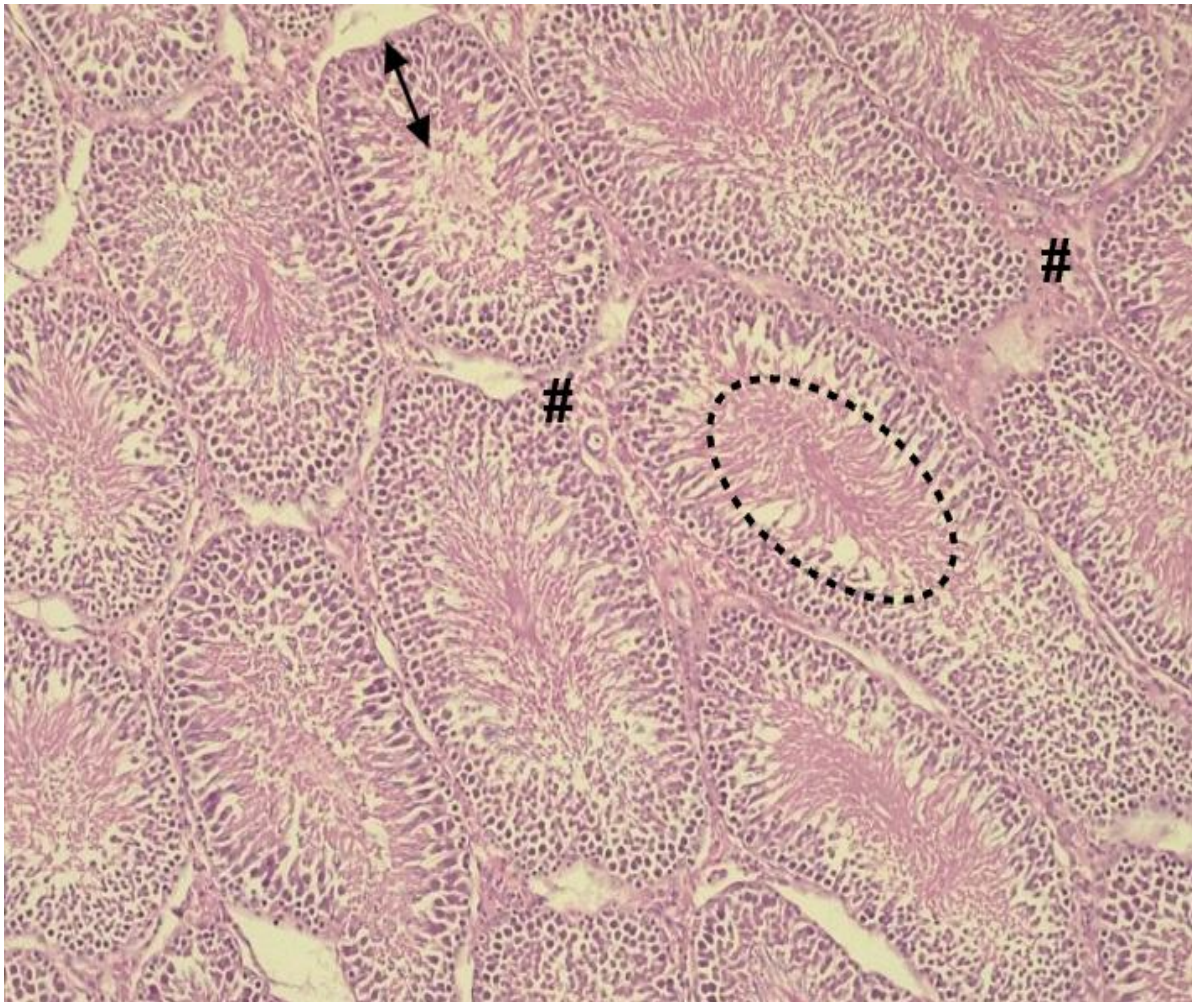


Plate 1: Testis (normal control) X400

Section of testes showing normal seminiferous tubules with germinal cell layers (**double-headed arrow**) on the basal lamina to spermatozoa filled lumen (**dotted circular lines**).

The interstitial connective (#) tissue was well preserved.

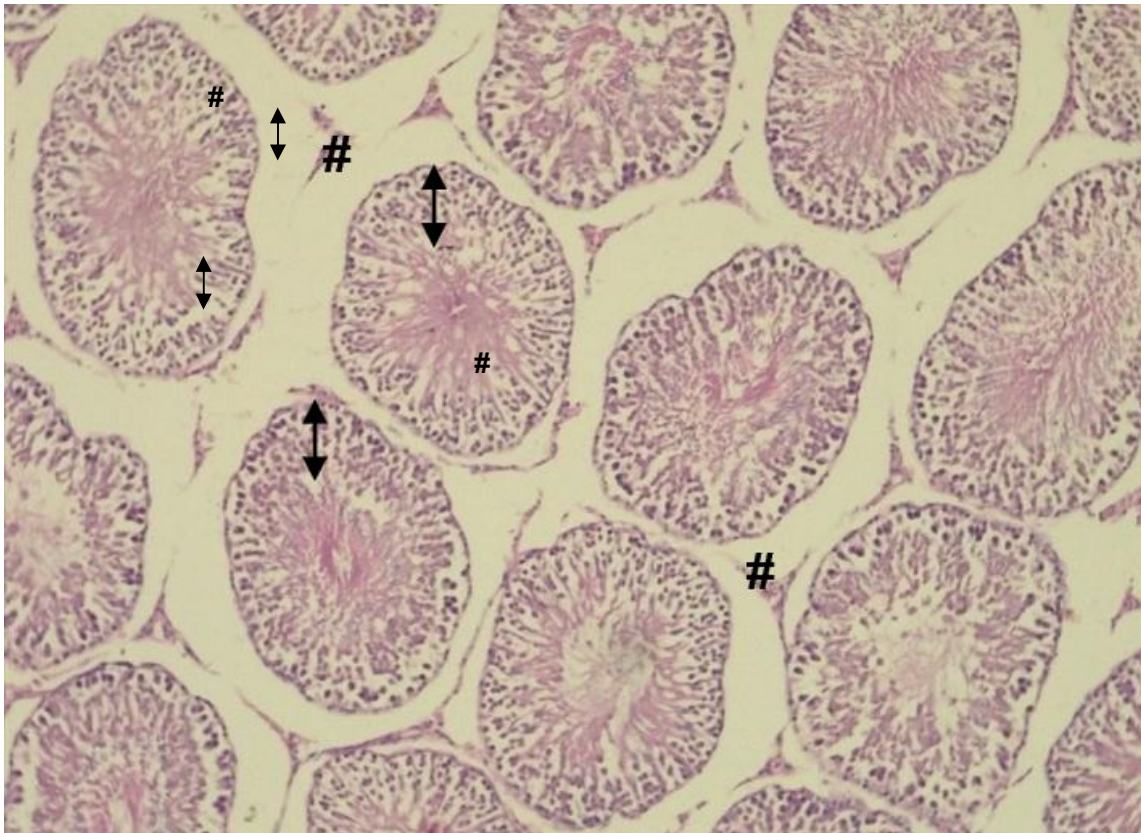


Plate 2: H&E section of testis of diabetic control (X400)

Section of testes showing seminiferous tubules with reduced germinal epithelium (double-headed arrow), distorted interstitial connective tissue (#).

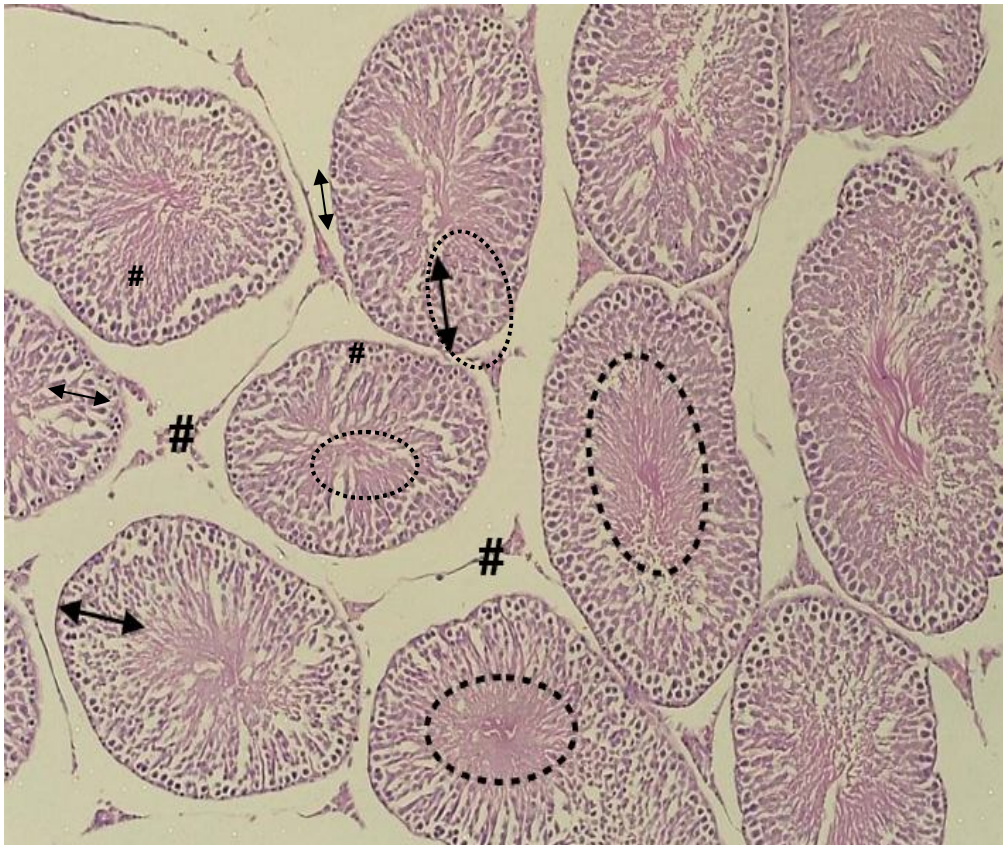


Plate 3: H&E section of testis (Standard group) X400

Section of testes showing normal seminiferous tubules tubules with germinal cell layers (**double-headed arrow**) starting from spermatogonia (**arrowhead**) on the basal lamina and spermatocytes filled lumen (**dotted circular lines**). The interstitial connective (#) tissues was distorted.

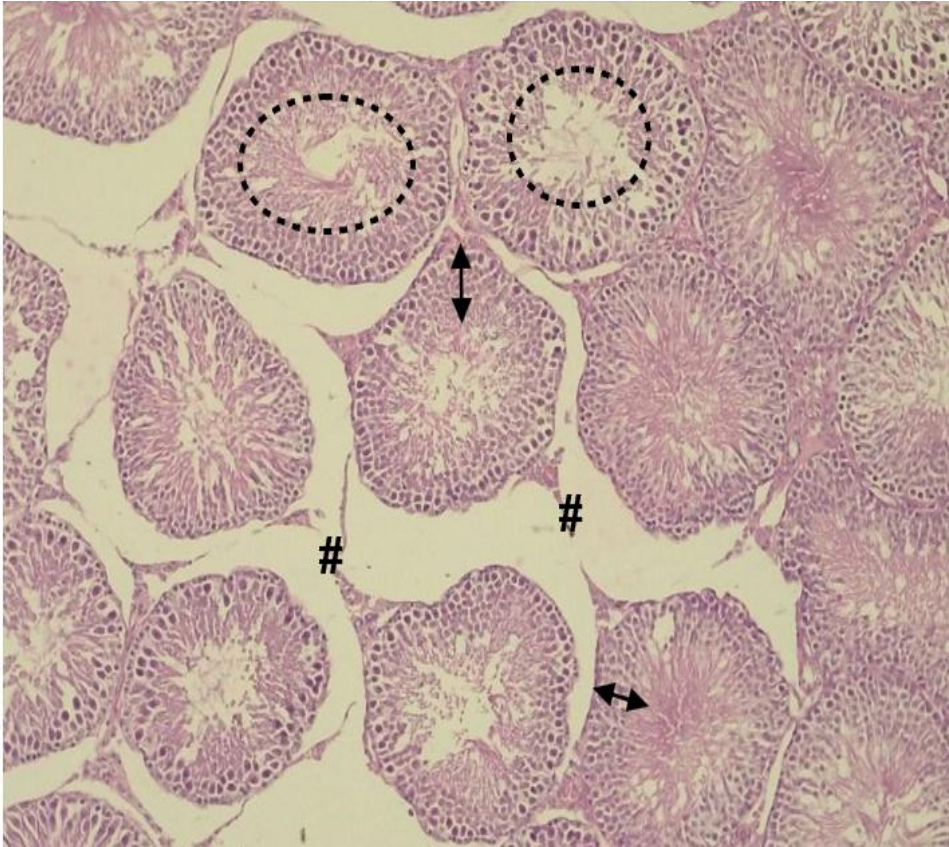


Plate 4: H&E section of testis(treated with 500mg/kg *C.longa*) X400

Section showed different stages of seminiferous tubules and the interstices. The seminiferous with germinal cell layers (**double-headed arrows**) showed lumen partly & completely filled (**dotted circular line**) with mature spermatocytes. The interstitial connective (#) tissues was distorted. Although the alteration exists, there is a progressive restoration observed.

DISCUSSION

Complex interplay of various pathological processes, prominently characterized by oxidative stress damage, inflammation, and apoptosis are involved in diabetic testicular damage (36). Curcumin, a bioactive compound derived from *Curcuma longa*, has emerged as a potential therapeutic agent with protective properties against diabetic testicular injury. However, the precise underlying mechanisms through which curcumin exerts its beneficial effects in this context remain a subject of ongoing investigation. The present study examined the effect of *C. longa* crude extract on the histology of the testis and semen parameters of streptozotocin-induced hyperglycemic male rats.

The sustained increase in the blood glucose levels of diabetic animals observed at the end of the study was corroborated by studies by Pulido-Moran et al (37) and Mohammed et al (38) which revealed hyperglycemic response in STZ treated animals. They postulated that the observation was due to impaired glucose oxidation which causes NAD⁺ depletion, ultimately culminating in the inhibition of insulin biosynthesis and secretion. The reduction in blood glucose levels in the metformin and extract-treated groups, aligns with the study by Akpaso et al (39), who reported a significant reduction in fasting blood glucose levels in animals administered curcumin. Studies by Shenoy (40) and Kunnumakkara et al (21) have corroborated the anti-diabetic efficacy of the extract, attributing it to its antioxidant and anti-inflammatory properties. Findings reported by Akpaso et al (41) also revealed the potential of *C. longa* to significantly reduce blood glucose levels in experimental animals.

The final bodyweight of the experimental animals in the extract-treated group showed a significant increase when compared to both the diabetic and control groups. The overall

changes in bodyweight statistically indicated that both the metformin and extract-treated groups experienced significant increases in their respective bodyweights when compared to both the control and diabetic groups. These findings are consistent with studies conducted by Shenoy (42) and Szudelski (43) which reported a significant decrease in bodyweight in streptozotocin-injected rats. Furthermore, the observed decrease in bodyweight of the diabetic rats aligns with the findings of Ding et al (44) and Zhong et al (45) who observed a similar effect on diabetic animals induced with streptozotocin. The underlying mechanisms contributing to the reduction in bodyweight within the diabetic group can be attributed to the intricate interplay of factors such as the degradation of structural proteins and muscle wasting as reported by He et al (46). Conversely, the ameliorative effects of *Curcuma longa* on bodyweight is supported in the work of Akpaso et al (41) where the oral administration of the plant extract demonstrated remarkable improvement in the bodyweight of experimental animals.

Semen analysis revealed a significant reduction in the total count of sperm cells in the diabetic control group, compared to the normal control group. This observation underscores the detrimental impact of diabetes mellitus, regardless of whether it is type 1 or type 2 diabetes, on male fertility. The findings of Tsao et al (47) demonstrated the adverse effects of experimentally induced diabetes on sperm parameters. Also a study conducted by Alizadeh et al (48) showed significantly reduced sperm count in diabetic animals. While the scientific basis underlying the pathophysiological mechanisms linking diabetes to semen parameters, particularly sperm count, remains diverse in the literature, prolonged hyperglycemia triggers the body's oxidative stress response and leads to endothelial injury in blood vessels, including those within the testis and epididymis (49). Moreover, elevated blood glucose levels can

disrupt the regulatory function of the hypothalamic-pituitary-gonadal axis, resulting in alterations in the number and morphology of testicular interstitial cells, degeneration of Sertoli cells, reduced synthesis and secretion of testosterone, impaired sperm development and maturation, and ultimately, compromised reproductive functions. However, the administration of the extract in the treated group led to a notable improvement in the total sperm count, which was comparable to that observed in the normal control group. These findings are in line with the research conducted by Chanapiwatet al(50) who demonstrated that replacing a ketogenic diet with curcumin supplementation improved semen quality. Additionally, a different study reported an increase in total sperm count among infertile men participating in a randomized clinical trial after receiving curcumin (51). Together, these studies provide further support for the positive effects of curcumin and its potential in ameliorating the adverse impacts of diabetes on semen parameters, including sperm count.

The experimental findings revealed a significant decline in the percentage concentration of motile sperm cells in the diabetic group compared to the control group. However both the standard and test groups showed an increase ($p < 0.05$) compared to the normal control group. These observed outcome in the diabetic group is consistent with the outcomes of prior investigations conducted by Ricci et al (52) and Zha (53) who reported that the addition of curcumin in frozen-thawed Angora goat semen improved both motility and acrosome integrity, while also enhancing the motility and functional integrity of sperm plasma membrane in frozen bull semen. In a report by Ozbek, he stated that diabetes mellitus is capable of disrupting endocrine and metabolic pathways, leading to reduced sperm motility and altered sperm morphology (54). The reduced sperm motility observed in the standard group agrees with studies by Raghif(55) and Naglaa et al (56) which illustrated that

metformin administration led to decrease in sperm motility. It was stated that vitamin B₁₂ deficiency could be the cause of this observation as chronic metformin use is associated with lower blood levels of vitamin B₁₂. Furthermore, metformin administration was said to impair the activity of mitochondrial complex-1 which plays a vital role in maintaining the normalcy of sperm motility (56,56).

Sperm viability values which decreased significantly in the diabetic control and metformin-treated groups compared with the normal control group. In the extract treated group there was an increase in sperm viability which was statistically significant when compared with the diabetic control. This finding aligns with a report by Ozbek also showed that diabetes mellitus was capable of altering sperm morphology through the disruption of endocrine and metabolic pathways (54). A study by Belhan et al (57) showed that the percentage of sperm viability in STZ-induced diabetic rats improved mildly in *Curcuma longa* treated group. The reason for the increase in sperm count, motility and viability as seen in the group treated with *Curcuma longa* extract may be due to its composite antioxidants which help reduce the oxidative stress caused by diabetes. Oxidative stress is capable of damaging sperm cells, as well as impairing their function (58).

The histopathological manifestations in the tissue sections of group B (diabetic control) rats were characterized by irregularly shaped seminiferous tubules exhibiting a shrunken lumen and decreased tubular diameter, which were indicative of severe edema and pronounced hyperemia within the veins. These findings align harmoniously with the seminal research conducted by Ghosh et al (59) and Barsiah et al (60) who expounded upon the frequent occurrence of abnormal histology within the testes of diabetic animals, with discernible

alterations observed in the cytoarchitecture of the seminiferous epithelium as well as disruptions in the occlusive distribution pattern.

Conversely, the tissue sections derived from the extract-treated group displayed notable therapeutic effects, which include prominent seminiferous tubules characterized by prominent basement membranes. Studies by Sudjarwo et al (61) and Singh et al (62) documented the positive influence of *Curcuma longa* on the cytoarchitecture of the testes. This remarkable therapeutic outcome can be attributed to the phenol compounds present in the extract as suggested by Sadhwani (63) and Pharm-Huy et al (64) that phenols possess the ability to counteract excessive free radicals, thereby safeguarding cells and tissues against their toxic effects. Many studies have also shown the tissue-protective effects of extracts of various medicinal plants rich in antioxidants (65,66,67,68,69).

CONCLUSION

The findings of the study suggest that extract of *Curcuma longa* has the potential to improve fertility in diabetic male animals, as well as protect against the detrimental effects of hyperglycemia on the male reproductive system.

REFERENCES

1. Gojka R. WHO global report on diabetes: a summary. *Intl J Noncom Dis.* 2016; 1(1): 3-8.
2. Shoback DG, Gardner D. Greenspan's basic and clinical endocrinology (9thed.). New York: McGraw-Hill Medical. 2011.
3. Saedi E, Gheini MR, Faiz F, Arami MA. Diabetes Mellitus and cognitive impairments. *World J Diabet.* 2016; 7(17): 412-422.

4. Leszek J, Trypka E, Tarasov VV, Ashraf GM, Aliev G. Type 3 diabetes mellitus: a novel implication of Alzheimers disease. *Cur Top Med Chem.* 2017; 17(12); 1331–1335.
5. Codner E, Merino PM, Tena-Sempere M. Female reproduction and type 1 diabetes: from mechanisms to clinical findings. *Hum Reprod.* 2012;18(5): 568-585.
6. Jaganjac M, Tirosh O, Cohen, G, Sasson S. Zarkovic N. Reactive aldehydes second messengers of free radicals in diabetes mellitus. *Free Rad Res.*2013; 47(1):39–48.
7. Miočić J, Car N, Metelko Ž. Sexual dysfunction in women with diabetes mellitus. *Diabetol Croat.* 2008;37:35–42.
8. La Vignera S, Condorelli RA, Di Mauro M. Reproductive function in male patients with type 1 diabetes mellitus. *Androl.* 2015; 3(6): 1082-7.
9. Alves MG, Martins AD, Rato L, Moreira PL, Socorro S, Oliveira PF. Molecular mechanisms beyond glucose transport in diabetes-related male infertility. *BiochimBiophysActa* 2013b;1832: 626-635.
10. Toumpanakis A, Turnbull T, Alba-Barba I. Effectiveness of plant-based diets in promoting well-being in the management of type 2 diabetes: a systematic review. *British Med J.*2018; 6(1).
11. Cappuccio. FP,CooperD, D`Elia L, StrazzulloP.MillerMA.Sleep duration predicts cardiovascular outcomes: a systematic review and meta-analysis of prospective studies. *Euro Heart J.* 2011; 32:1484-1492.
12. Inzucchi SE, Bergenstal RM, BuseJB,Diamant M, Ferrannini E, Nauck M et al. Management of hyperglycemia in type 2 Diabetes: a patient-centered approach: position statement of the American Diabetes Association (ADA) and the European Association for the study if Diabetes (EASD). *Diabet care.* 2012; 35:1364-1379.
13. Eldor R, Raz I. Diabetes therapy--focus on Asia: second-line therapy debate: insulin/secretagogues. *Diabet Metab Res Rev.*2012; 28(2):85–89.

14. Kooti W, Moradi M, Ali-Akbari S, Sharafi-Ahvazi N, Asadi-Samani M, Ashtary-Larky D et al. Therapeutic and pharmacological potential of *Foeniculumvulgare* Mill: a review. J Herbmed Pharmacol. 2015; 4(1): 1-9.
15. Wu CH, Wang CC, Kennedy J. Changes in herb and dietary supplement use in the U.S. adult population: a comparison of the 2002 and 2007 National health interview surveys. Clin Ther, 2011; 33:1749–58.
16. Soner BC, Şahin AS, Şahin TK. A survey of Turkish hospital patients' uses of herbal medicine. Euro J Integ Med. 2013; 547–52.
17. Ekor M. The growing use of herbal medicines: issues relating to adverse reactions and challenges in monitoring safety. Front Pharmacol. 2014; 4: 177.
18. Parmer V. Herbal Medicine: Its toxic effect and drug interactions. The Ind Anaesth Forum. 2005; 1-9.
19. Afrisham R, Aberomand M, Ghaffari MA, Siahpoosh A, Jamal M. Inhibitory effect of *Heracleumpersicum* and *Ziziphusjuzuba* on activity of alpha-amylase. J Bot. 2015; 1-8.
20. Matias JN, Achete G, Campanari G, Guiguer ÉL, Araújo AC, Buglio DS. et al. A systematic review of the antidepressant effects of curcumin: beyond monoamines theory. Aust New Z J Psychiat. 2021; 4867421998795.
21. Kunnumakkara AB, Bordoloi D, Padmavathi G, Monisha J, Roy NK, Prasad S, et al. Curcumin, the golden nutraceutical: multitargeting for multiple chronic diseases. Brit J Pharmacol 2017; 174(11): 1325-1348.
22. Mascarenhas MN, Flaxman SR, Boerma T, Vanderpoel S, Stevens GA. National, regional, and global trends in infertility prevalence since 1990: a systematic analysis of 277 health surveys. PLoS Med. 2012;9:e1001356
23. Chowdhury SH, Cozma AI, Chowdhury JH. Infertility. Essentials for the Canadian Medical Licensing Exam: Review and Prep for MCCQE Part I. 2nd edition. 2017; Wolters Kluwer, Hong Kong.

24. Cooper TG, Noonan E, Von Eckardstein S, Auger J, Baker HW, Behre HM, et al. World Health Organization reference values for human semen characteristics. *Human reproduction update*. 2010; (3): 231–45.
25. International Diabetes Federation. *Diabetes atlas*. 8th ed. Brussels: International Diabetes Federation; 2017.
26. Lenzen, S. Alloxan monohydrate and streptozotocin diabetes. *Diabetologia*. 2007; 51:216-226.
27. Junod A, Lambert AE, Orci L, Pictet R, Gonet AE, Renold AE. Studies of the diabetogenic action of streptozotocin. *Proc Soc Exp Biol Med*. 1967; 126(1):201-205.
28. Bolzán AD, Bianchi MS. Genotoxicity of streptozotocin. *Mutat Res*. 2002;512(2-3):121-34.
29. Elsner M, Guldbakke B, Tiedge M, Munday R, Lenzen S: Relative importance of transport and alkylation for pancreatic beta-cell toxicity of streptozotocin. *Diabetologia*. 2007; 43: 1528–1533.
30. Barratt C. L. Semen analysis is the cornerstone of investigation for male infertility. *The Practitioner*, 2007; 251(1690): 8–17.
31. Leslie SW, Soon-Souton TL, Khan MAB. Male infertility. *StatPearls*. 2023.
32. Nna, VU, Bakar ABA, Ahmad A, Mohamed M. Diabetes-induced testicular oxidative stress, inflammation, and caspase-dependent apoptosis: the protective role of metformin. *Arch Physiol Biochem*. 2020; 126(5): 377–388.
33. Tangvarasittichai S. Oxidative stress, insulin resistance, dyslipidemia and type 2 diabetes mellitus. *World J Diabet*, 2015; 6(3): 456–480.
34. Strugała, P, Dzydzan O, Brodyak I, Kucharska AZ, Kuroпка P, Liuta M, et al. Antidiabetic and antioxidative potential of the blue Congo variety of purple potato extract in Streptozotocin-induced diabetic rats. *Molecules*. 2019; 24(17): 3126.

35. Avwioro G, Iyiola S, Aghoghovwia B. Histological and biochemical markers of the liver of Wistar rats on subchronic oral administration of green tea. *N Am J Med Sci.* 2010; 2(2): 376-380.
36. Marton LT, Pescinini-E-Salzedas LM, Camargo MEC, Barbalho SM, Haber, JF, et al. The effects of Curcumin on diabetes mellitus: a systematic review. *Front endocrinol.* 2021; 12: 669448.
37. Pulido-Moran M, Moreno-Fernandez J, Ramirez-Tortosa C, Ramirez-Tortosa M. Curcumin and health. *Molecules.* 2016; 21(3): 264.
38. Mohammed A, Wudil AM, Alhassan AJ, Imam AA, Muhammad IU, Idi A. Hypoglycemic activity of *Curcuma longa* Linn root extracts on Alloxan induced diabetic rats. *The Saudi J Life Sci.* 2017; 2(2): 43-49.
39. Akpaso MI, Atangwho IJ, Akpantah A, Fischer VA, Igiri AO, Ebong PE. Effect of combined leaf extracts of *Vernonia amygdalina* (bitter leaf) and *Gongronema latifolium* (Utazi) on the pancreatic β -cells of Streptozotocin-induced diabetic rats. *J Adv Med Med Res.* 2011; 1(1): 24–34.
40. Sharma S, Kulkarni SK, Chopra K. Curcumin, the active principle of turmeric (*Curcuma longa*), ameliorates diabetic nephropathy in rats. *Clin Exp Pharm Physiol.* 2006; 33(10): 940–945.
41. Akpaso M, Igiri A, Odey PA. Comparative study on the effect of combined methanolic leaf extracts of *Vernonia amygdalina* and *Gongronema latifolium* and metformin on the pancreatic beta cells of Streptozotocin-induced diabetic Wistar rats. *Asian J Pharma Nurs Med Sci.* 2017; 5(2): 42-48.
42. Shenoy AG, Ramesh KG. Improvement of insulin sensitivity by perindopril in spontaneously hypertensive and streptozotocin-induced diabetic rats. *Ind J Pharmacol.* 2002; 34: 156-164.
43. Szudelski TS. The mechanism of alloxan and streptozotocin action in β cells of the rat pancreas. *J Physiol Res.* 2001; 50: 536-546.

44. Ding GL, Liu Y, Liu ME, Pan JX, Guo MX, Sheng JZ, et al. The effects of diabetes on male fertility and epigenetic regulation during spermatogenesis. *Asian Journal of Andrology*. 2015; 17(6): 948–953.
45. Zhong O, Ji L, Wang J, Lei X, Huang H. Association of diabetes and obesity with sperm parameters and testosterone levels: a meta-analysis. *Diabetol Metabol Syndrom*. 2021; 13(1): 109.
46. He Z, Yin G, Li QQ, Zeng Q, Duan J. Diabetes mellitus causes male reproductive dysfunction: a review of the evidence and mechanisms. *In vivo*. 2021; 35(5): 2503–2511.
47. Tsao CW, Ke PS, Yang HY, Chang TC, Liu CY. Curcumin remedies testicular function and spermatogenesis in male mice with low-carbohydrate-diet-induced metabolic dysfunction. *Int JMol Sci*. 2022; 23: 10009.
48. Alizadeh F, Javadi M, Karami AA, Gholaminejad F, Kavianpour M, Haghghian HK. *Curcumin nanomicelle* improves semen parameters, oxidative stress, inflammatory biomarkers, and reproductive hormones in infertile men: a randomized clinical trial. *Phytother Res*. 2017; 32(3): 514–521.
49. Bucak MN, Tuncer PB, Sariözkan S, Başpınar N, Taşpınar M, Coşkun K, et al. Effects of antioxidants on post-thawed bovine sperm and oxidative stress parameters: antioxidants protect DNA integrity against cryodamage. *Cryobiol*. 2010;6(7): 248-253.
50. Chanapiwat P, Kaeoket K. The effect of *Curcuma longa* extracted (curcumin) on the quality of cryopreserved boar semen. *Animal Sci J*. 2015; 12395
51. Olarenwaju J, Olatunji SY, Owolabi JO, Oluwatosin AT, Amaechi WC, Desalu AB. In vivo evidences of *Curcuma longa* on oxidative stress in STZ-induced diabetes on sperm parameters in male Wistar rats. *Ana J Afri*, 2017; 6(3): 1045-1051.
52. Ricci G, Catizone A, Esposito R, Pisanti FA, Vietri MT, Galdieri M. Diabetic rat testes: morphological and functional alterations. *Andrologia*, 2009; 41(6): 361–368.

53. Zha W, Bai Y, Xu L, Liu Y, Yang Z, Gao H, Li J. Curcumin attenuates testicular injury in rats with Streptozotocin-induced diabetes. *BioMed ResInt*, 2018; 7468019.
54. Ozbek E. Diabetes mellitus impairs sperm functions in male infertility; 2024. Accessed 12 November 2024. Available: <https://dreminozbek.com/en/diabetes-melitus-impairs-sperm-functions-and-male-fertility/#:~:text=Diabetes can disrupt endocrine and,for couples seeking to conceive.>
55. Raghif ARA. Effects of metformin on hormonal profile and seminal fluid analysis in obese infertile male. *Iraqi JMS*. 2015; 13: 295-301.
56. Naglaa ZH, Hesham, Abdel FH, et al. Impact of metformin on immunity and male fertility in rabbits with alloxan-induced diabetes. *J Am Sci*. 2010; 6: 417-426.
57. Belhan, S, Yıldırım S, Huyut Z, Özdek U, Oto G, Algül S. Effects of curcumin on sperm quality, lipid profile, antioxidant activity and histopathological changes in streptozotocin-induced diabetes in rats. *Andrologia*, 2020; 52(6): e13584.
58. Kaltsas A. Oxidative stress and male infertility: the protective role of antioxidants. *Medicina*. 2023; 59(10): 1769.
59. Ghosh S, Sayantani C, Das AK, Sil PC. Taurine ameliorates oxidative stress-induced inflammation and ER stress-mediated testicular damage in STZ-induced diabetic rats. *Food Chem Toxicol*. 2019; 124: 64-80.
60. Barsiah S, Benham-Rassouli M, Shahabipour F, Rostami S, Sabbaghi MA, Momeni Z, et al. Evaluation of testis hormonal and histopathological alterations in type I and type II diabetic rats. *J Cell Biochem*. 2019; 120(10): 16775-16785.
61. Sudjarwo SA, Sudjarwo GW, Koerniasari. Protective effect of Curcumin on lead acetate-induced testicular toxicity in Wistar rats. *Res Pharm Sci*. 2017; 12(5): 381-390.
62. Singh P, Deora K, Sankhla V, Mogra P. Curcumin rendered protection against cadmium chloride-induced testicular damage in Swiss albino mice. *J Cell Mol Biol*. 2010; 10(2): 31-38.

63. Sadhwani S. Carambola (starfruit) *Averrhoa carambola*. Accessed 17 August 2023; 2023. Available:<https://www.ayurtimes.com/cara-mbola-starfruit-averrhoa-carambola/>
64. Pharm-Huy LA, He H, Pharm-Huy C. Free radical: antioxidants in disease and health. *Int J Biomed Sci*. 2008; 4(2): 89-96.
65. Anani SE, Oku ME, Eru EM, Uruakpa KC, Bassey IF, Udo-affah GU et al. Neuroprotective effects of *Dacryodes edulis* ethanolic leaf extract on the prefrontal cortex and long-term learning and memory in Wistar rats of ketamine-induced neurotoxicity. *Asian J Res Rep Neurol*. 2024; 7(1): 86-97.
66. Eru EM, Paulinus SO, Udo-affah GU, Uruakpa KC, Oku ME, Anani SE et al. Hippocampal astrogliotic reduction in scopolamine hydrobromide-induced Alzheimer's cognitive dysfunction Wistar rats following administration of *Telfairia occidentalis* (Hoof F.) *Niger J Physiol sci*. 2021;36:241-244.
67. Anani SE, Oku ME, Eru EM, Uruakpa KC, Bassey IF, Udo-affah GU et al. Neuroprotective effects of *Dacryodes edulis* ethanolic leaf extract on the hippocampus of rats of ketamine-induced neurotoxicity. *Asian J Res Rep Neurol*. 2024; 7(1): 130-145.
68. Oku ME, Akpaso MI, Odey PA, Eru EM, Anani SE, Umoh NM. Stereological studies on ameliorative role of ethanolic extracts of *Gongronema latifolium* against streptozotocin-induced diabetic splenic tissue damage in Wistar rats. *Asian J Immunol*. 2024;7 (1): 131-148.
69. Akpaso MI, Lydia LE, Anani SE, Oku ME, Nnenna WA, Umoh NM, et al. Ameliorative effect of *Curcuma longa* ethanolic extract on the histology, hepatic glycogen content and some biochemical parameters of the liver in streptozotocin-induced hyperglycemic Wistar rats. *J Comp Altern Med Res*. 2024; 25(11): 1-16.

UNDER PEER REVIEW