

Case report

A Rare Case of Hydrocele of Canal of Nuck in an Adult Female

ABSTRACT

Background: This case report discusses a rare case of Hydrocele of canal of Nuck in an adult female and its management by laparoscopic surgery.

Presentation: A 35 year old female patient presented with gradually increasing swelling in the right groin since 2months. On examination, a 5x4cm swelling was noted in the right inguinal region, soft in consistency with absent expansive cough impulse. Ultrasound showed a 6x4.5cm multilocular, anechoic cystic lesion with internal septations in the right inguinal region. Diagnostic laparoscopy was done and hydrocele of canal of nuck was confirmed on the right side. Excision and TAPP repair using 15x10cm polypropylene mesh was done.

Discussion: During embryological development of a female foetus, the round ligament descends to the labia majora through the inguinal canal carrying along with it, a fold of parietal peritoneum called canal of Nuck. It is the female analogous to the processus vaginalis in males and normally gets obliterated by the first year of life. Failure to do so may result in a hydrocele or a hernia.

Conclusion: Hydrocele of canal of Nuck is a rarely diagnosed condition in adult females often mistaken for inguinal hernia and other cystic lesions. Surgical excision is both diagnostic and therapeutic in providing relief and preventing recurrence. It should be a differential diagnosis for inguino-labial or inguinal swelling in an adult female.

Keywords: Canal of Nuck, Female Hydrocele, TAPP, inguino-labial swelling

1. INTRODUCTION

Hydrocele of the canal of Nuck is a rare surgical condition with an incidence of 1% in female children with inguinal swellings and even more scarce in adult females with the exact incidence not known [1]. The homologous structure to canal of Nuck in males is the processus vaginalis [2]. Failure of obliteration of this structure causes fluid to accumulate within the sac leading to the formation of a hydrocele. It presents as a painless swelling in the inguinal or inguino-labial region and is often misdiagnosed as an inguinal hernia. The usual presentation is in paediatric age group but can rarely present in adulthood as well [3]. Hence, it should be considered as a differential diagnosis in cases of inguinal or inguino-labial swelling in adult females.

2. CASE REPORT

A 35 year old female patient presented with swelling in the right groin since 2 months that was gradually increasing in size. There was no history of pain over the swelling and no history of previous surgeries. On examination, a 6x4cm solitary, soft swelling was noted in the right inguinal region. It was irreducible with an absent cough impulse.

Ultrasound showed a 7.6x4.5 cm multilocular, anechoic cystic lesion with internal septations in the right inguinal region. MRI was also done which showed 7.2x4.1x1.3 cm multiloculated T1 hypointense and T2 hyperintense collection extending from the right superficial inguinal ring to the right labia majora. Patient was suspected to have an encysted hydrocele of canal of Nuck and was planned for diagnostic laparoscopy.

10mm port was created in the left mid clavicular line at the level of umbilicus and two 5mm working ports were placed in the left lower quadrant. Peritoneum opened above the ASIS and encysted hydrocele visualised. It was dissection from the surrounding structures. Serous fluid was aspirated from the cystic mass and hydrocele along with the round ligament was excised. A 10x15 cm polypropylene mesh was placed over the deep ring using TAPP approach.

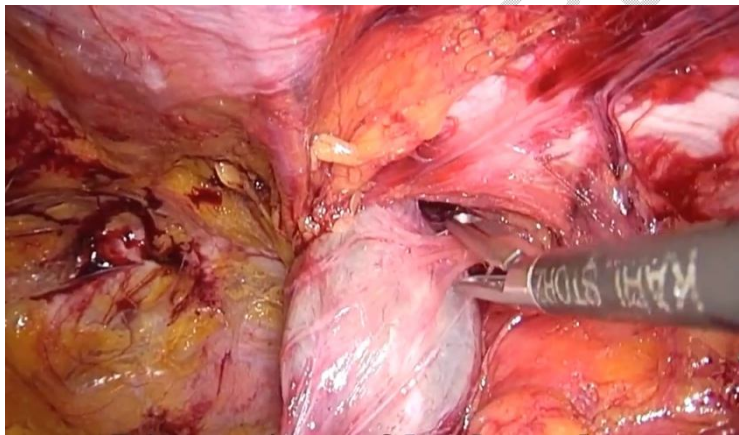


Figure 1: Intra operative Identification of the Hydrocele of canal of Nuck



Figure 2: Transabdominalpreperitoneal mesh repair of the defect

3. DISCUSSION

Hydrocele of canal of Nuck was first described by Anton Nuck. It occurs due to failure of obliteration of the processus vaginalis during embryonal development. There is persistent fluid accumulation within this processus vaginalis resulting in the formation of a hydrocele. It can be easily confused with other more common inguinal pathologies such as inguinal hernias, lipoma, lymphadenopathy or Bartholin's cyst because of its rarity. **Some patients may present with an accompanying inguinal hernia [4].**

During development of a female foetus, the round ligament descends to the labia majora through the inguinal canal carrying along with it, a fold of parietal peritoneum called the canal of Nuck. It is the female analogous to the processus vaginalis of males and normally gets obliterated by the first year of life. Failure to do so may result in a hydrocele or a hernia. The secretion of fluid by the mesothelial cells into the potential space results in a hydrocele.

Hydrocele of canal of nuck is classified into 3 types [5]

Type 1- Encysted hydrocele which occurs due to partial obliteration of the proximal portion of the Canal of Nuck. There is no communication with the peritoneal cavity.

Type 2- Hydrocele with communication between the hydrocele and the peritoneal cavity

Type 3- Combined type where there is an hourglass shaped hydrocele due to constriction by deep ring causing an encysted inferior portion and a superior portion that communicates with the peritoneal cavity.

On Ultrasound, multilocular anechoic or hypoechoic cystic lesion will be seen in the inguinal region. MRI or CT can determine communication with the peritoneal cavity. MRI shows a thin walled cystic lesion extending along the round ligament from the pelvic cavity to the inguinal region [6]

Treatment is surgical excision of the sac with concomitant closure of the defect with or without mesh. Intraoperative findings include a fluid filled sac localized to the inguinal canal or extending into the labia majora. Complete excision of the sac is necessary to prevent recurrence. **Laparoscopic TAPP resection and TEP (totally extraperitoneal) have become more popular methods of management of hydrocele of canal of Nuck [7, 8]. However, compared with TEP, TAPP allows better imaging of the lesions in the abdominal cavity[7, 9]. Timely treatment may prevent future complications as patency may lead to herniation of abdominal structures such as bowel, ovaries and urinary bladder [10]. Surgical excision is recommended if cysts become symptomatic as aspiration causes fluid re accumulation [11].** Postoperative histopathological examination may be considered especially when atypical features or septations are noted as rarely cystic lymphangioma or mesothelioma may have similar presentation [12].

4. CONCLUSION

Hydrocele of the canal of Nuck is an uncommon entity but should be considered as a differential diagnosis for inguinal and inguino-labial swellings in female patients. Its rarity, coupled with clinical similarities to other inguinal pathologies, often makes diagnosis challenging. This case underscores the significance of maintaining a high index of suspicion and utilizing imaging modalities for accurate identification. Definitive management involves surgical excision, which not only resolves the condition but also allows for histopathological evaluation to confirm the diagnosis. Greater awareness of this rare entity among clinicians

can help prevent delays in diagnosis, unnecessary interventions, and associated complications, ultimately leading to better patient care and outcomes.

CONSENT

As per international standards or university standards, patient(s) written consent has been collected and preserved by the author(s).

ETHICAL APPROVAL

As per international standards or university standards written ethical approval has been collected and preserved by the author(s).

Disclaimer (Artificial intelligence)

Option 1:

Author(s) hereby declare that NO generative AI technologies such as Large Language Models (ChatGPT, COPILOT, etc.) and text-to-image generators have been used during the writing or editing of this manuscript.

REFERENCES

1. Kochis M, Goldstein AM, Griggs C. Canal of Nuck hydrocele. *J Pediatr Surg Case Rep.* 2021;74:102049. doi: 10.1016/j.epsc.2021.102049.
2. Rees, M.A.; Squires, J.E.; Tadros, S.; Squires, J.H. Canal of Nuck hernia: A multimodality imaging review. *Pediatric Radiol.* **2017**, *47*, 893–898.
3. RajanSood, Sourabh Trivedi, ParanTanwar, Hydrocele in the canal of nuck in a young female: a rare case report, *Journal of Surgical Case Reports*, Volume 2022, Issue 7, July 2022, rjac316
4. Adhikari S, Bhatta OP. Hydrocele of the Canal of Nuck: A report of five cases. *Int J Surg Case Rep.* 2023 Oct 27;112:108993. doi: 10.1016/j.ijscr.2023.108993. Epub ahead of print. PMID: 39491851; PMCID: PMC10667887.
5. Sarkar S, Panja S, Kumar S. Hydrocele of the Canal of Nuck (Female Hydrocele): A Rare Differential for Inguino-Labial Swelling. *J Clin of Diagn Res.* 2016; 10(2):PD21-PD22.
6. Kono R, Terasaki H, Murakami N, Tanaka M, Takeda J, Abe T. Hydrocele of the canal of Nuck: a case report with magnetic resonance hydrography findings. *Surg Case Rep.* 2015 Sep 22;1:86. doi: 10.1186/s40792-015-0086-5. PMID: 26413462; PMCID: PMC4579258.
7. Russell JC. Laparoscopic closure of patent canal of Nuck for female indirect inguinal hernia. *The Journal of the American Association of Gynecologic Laparoscopists.* 2001 Feb 1;8(1):10-1.
8. Matsumoto T, et al. Laparoscopic diagnosis and treatment of a hydrocele of the canal of Nuck extending in the retroperitoneal space: a case report. *Int J Surg Case Rep.* 2014;5(11):861–4.

9. Shahid F, et al. Laparoscopic hydrocelectomy of the canal of Nuck in adult female: case report and literature review. *Int J Surg Case Rep.* 2020;66:338–41.
10. Khadim B, AlNuaimi D, Abdulghaffar S, AlKetbi R. Hydrocele of the canal of Nuck: a rare differential diagnosis for an inguinal hernia. *J Ultrason.* 2024 Feb 27;24(96):20240007. doi: 10.15557/jou.2024.0007. PMID: 38419838; PMCID: PMC10897368.
11. Gkioulos F, Theodoridou S, Abay B, Engledow AH. A Case Report of Female Hydrocele of the Canal of Nuck (Type I): A Diagnostic Challenge and Surgical Solution. *Cureus.* 2023 Oct 29;15(10):e47926. doi: 10.7759/cureus.47926. PMID: 37908696; PMCID: PMC10613587.
12. Martha A. Kaeser, Daniel W. Haun, John C.S. Cho, Norman W. Kettner, Hydrocele in the Canal of Nuck, *Journal of Medical Ultrasound*, Volume 19, Issue 4, 2011, Pages 138-140, ISSN 0929-6441.

UNDER PEER REVIEW