

Case report

Acute necrotizing colitis : a case report and literature review.

Abstract:

Necrotizing colitis is a medical and surgical emergency that can be life-threatening, commonly overlooked in young patients because of its rare occurrence.

We describe the case of a 44-year-old male who was admitted for treatment of necrosis in the sigmoid colon caused by a thrombosis in the inferior mesenteric artery, probably following a SARS-CoV-2 infection.

Keywords: *Necrotizing colitis, emergency surgery, thrombosis of the inferior mesenteric artery.*

Introduction:

Necrotizing colitis is an acute condition predominantly impacting premature neonates, characterized by considerable morbidity and mortality rates¹. Its occurrence in adults is notably lower, with decreased mortality rates². Prognosis relies mainly on urgent, multidisciplinary treatment.

Case presentation:

A 44-year-old young man with a history of SARS-Cov2 infection, admitted to the emergency department with a 4-day history of occlusion, clinical examination revealed a patient in relatively good general condition, tachycardic with a heart rate of 110 bpm and blood pressure of 100/60 mmHg afebrile, the abdomen was distended with tenderness localized to the flank and left iliac fossa.

Biological screening showed hemoglobin level at 10g/dL, WBC 16400 elements/mm³, C-reactive protein 120 mg/L.

Abdominal CT scan with injection showed necrosis of sigmoid colon due to thrombosis of inferior mesenteric artery with peritoneal fluid effusion.

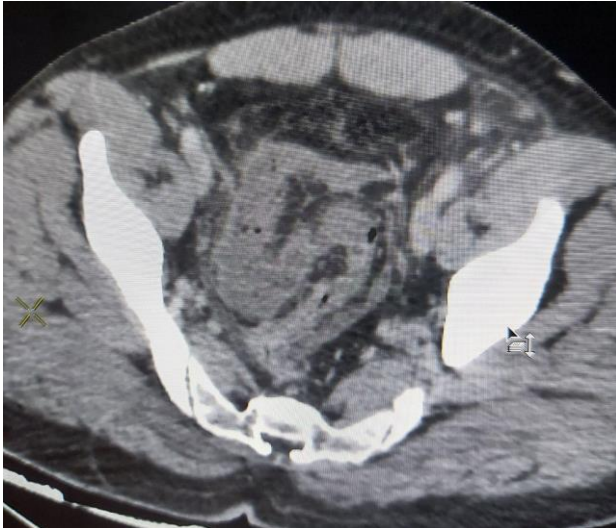


Figure 1: CT-Scan showing sigmoid necrosis

Emergency surgery was performed, surgical exploration revealed localized necrosis of the sigmoid colon, which was subsequently resected with the confection of a double stoma.

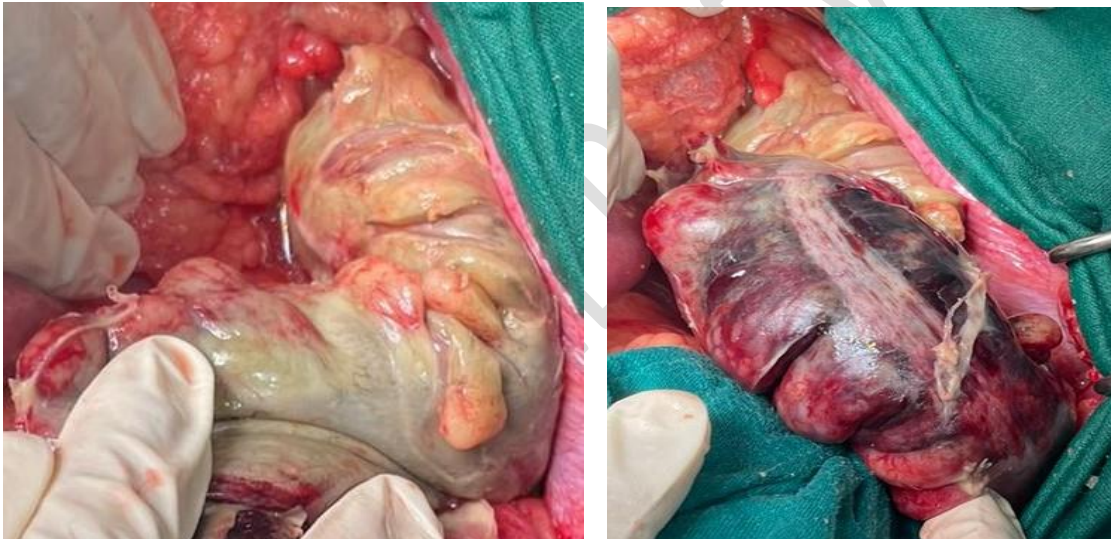


Figure 2: Image showing the necrotic sigmoid colon

Medical treatment was then instituted with curative-dose LMWH.

The follow-up was generally marked by a clinical and biological recovery. Patient was then referred to internal medicine department for etiological investigation.

Discussion:

Necrotizing colitis (NC) predominantly impacts premature neonates of low birth weight, with an incidence ranging from 0.3 to 2.4 per 1000 live births, but notably higher at approximately 10% among infants weighing less than 1500 grams^{3,4}. While NC occurrence is substantially lower in adults and carries a decreased mortality rate, it still presents significant morbidity⁵.

Several causes can lead to NC in adults. Factors such as infectious agents, inflammatory mediators, and circulatory disturbances are all implicated in its etiology and pathogenesis. A wide range of infectious bacterial causes can lead to NC, including Klebsiella, E. coli, Clostridia, and Staphylococcus epidermidis, as well as viruses like Coronaviruses, Rotaviruses².

The clinical manifestations of NC are variable and depend mainly on the severity and time course of the disease. Main symptoms are abdominal pain, vomiting and nausea, abdominal tenderness, abdominal contracture or tenderness, bowel obstruction.

Patients rarely have a fever and will usually not have a leukocytosis. In cases of severe intestinal ischemia causing transmural infarction and necrosis, abdominal wall contracture may be noted on abdominal examination and is often accompanied by metabolic acidosis and shock⁶.

Ultrasonography and radiography can be used as diagnostic tools, but a CT scan has been declared to be the first choice for the diagnosis of NC⁷. The images that can be seen are intestinal wall thickening, per colon fat infiltration, with or without peritoneal fluid. Computed tomography may suggest a vascular etiology; in the case of complete obstruction, the intestinal wall will be thin and non-enhanced, with dilatation of the lumen, possibly with thrombosis in the mesenteric vessels⁸.

Overall, a CT scan can be used to determine the severity and exact location of the injury. Also, MR angiography can be used to evaluate any suspected arteriovenous IMA malformation⁷.

The innumerable causes of colonic ischemia can be categorized into occlusive and nonocclusive pathologies. Thrombophilia and vasculitis are the most important among the occlusive causes of ischemic colitis in the young⁹.

SARS-CoV-2 has been linked to the development of coagulopathy and thromboembolic complications in severe COVID-19 patients. The presentations included pulmonary embolism, deep venous thrombosis, and rarely mesenteric ischemia. Our patient had an history of SARS-CoV-2 infection.

Treatment is multidisciplinary and involves surgery and LMWH-based medical therapy. Surgical intervention is necessary if there is intestinal necrosis or frank perforation or when there is clinical deterioration over 12–24 hours despite intensive medical support, surgical options are either resection of the necrotic segment with anastomosis, or resection and provision of a stoma².

Conclusion:

NC very rarely affects adults, its clinical presentation is widely variable, and its diagnosis is based on CT scans.

Management is urgent and relies mainly on surgery and administration of LMWH.

Consent

As per international standard or university standard, patient(s) written consent has been collected and preserved by the author(s).

Ethical approval

As per international standard or university standard written ethical approval has been collected and preserved by the author(s).

REFERENCES

1. Fick KA, Wolken AP. NECROTIC JEJUNITIS. *Lancet*. 1949;253(6552):519-521. doi:10.1016/S0140-6736(49)90847-8
2. Katara AN, Chandiramani VA, Soman R, Bhaduri A, Desai DC. Necrotizing enterocolitis in adults: a study of four cases. *Indian J Surg*. 2004;66. Accessed May 4, 2024. <https://tspace.library.utoronto.ca/handle/1807/2845>

3. Chung DH, Ethridge RT, Kim S, et al. Molecular mechanisms contributing to necrotizing enterocolitis. *Ann Surg*. 2001;233(6):835-842. doi:10.1097/00000658-200106000-00014
4. Huang FS, Warner BW. Necrotizing enterocolitis: a closer look. *Gastroenterology*. 2001;121(4):1016-1017. doi:10.1016/S0016-5085(01)70081-9
5. Mackay WD, Dawson JL. Necrotizing colitis. *Proc R Soc Med*. 1967;60(5):502. doi:10.1177/003591576706000527
6. Washington C, Carmichael J. Management of Ischemic Colitis. *Clin Colon Rectal Surg*. 2012;25(4):228. doi:10.1055/S-0032-1329534
7. Seeliger B, Agnus V, Mascagni P, et al. Simultaneous computer-assisted assessment of mucosal and serosal perfusion in a model of segmental colonic ischemia. *Surg Endosc*. 2020;34(11):4818-4827. doi:10.1007/S00464-019-07258-Z/METRICS
8. Case Study: Non - Embolistic Necrotizing Colitis - An Examination of Clinical Presentation and Management, IJSR, Call for Papers, Online Journal. Accessed May 12, 2024. <https://www.ijsr.net/getabstract.php?paperid=SR23727135155>
9. Doulberis M, Panagopoulos P, Scherz S, Dellaporta E, Kouklakis G. Update on ischemic colitis: from etiopathology to treatment including patients of intensive care unit. *Scand J Gastroenterol*. 2016;51(8):893-902. doi:10.3109/00365521.2016.1162325