

EFFECTS OF *ANCYLOSTOMA CEYLANICUM* INFECTION ON LACTATE DEHYDROGENASE ACTIVITY IN TISSUES OF *MESOCRICETUS AURATUS*

ABSTRACT

Aim: The present research aims to study the effects of *Ancylostomaceylanicum* infection on lactate dehydrogenase activity in the tissues of *Mesocricetus auratus*.

Methodology: In the current investigation, *Ancylostoma ceylanicum*, a hookworm was infected in the host, a hamster *Mesocricetus auratus* experimentally in laboratory conditions in Hyderabad from 1992 to 1996. The infected host was then studied using the parameters of Lactate Dehydrogenase activity in various tissues. The Lactate Dehydrogenase content in *M. auratus* was investigated biochemically in both the infected and control samples. **Results:** The results revealed increased levels of Lactate dehydrogenase in the intestinal and muscle tissue of the infected host. Decreased LDH content in the liver, kidney, spleen, lungs, brain and serum was found in the infected host. **Discussion:** Lower levels of Lactate Dehydrogenase in certain tissues could indicate lesser synthesis of Lactate Dehydrogenase as the anaerobic conditions prevail in the intestinal region of the host infected with hookworm infection. **Conclusion:** The present paper reveals the Lactate dehydrogenase content in *Mesocricetus auratus* infected with *Ancylostomaceylanicum* as compared to control and its significance.

KEYWORDS: *Ancylostoma ceylanicum*, Hamster, *Mesocricetus auratus*, infection, hookworm, Lactate Dehydrogenase(LDH).

INTRODUCTION

The helminthic infection that affects tropical and subtropical regions is an endoparasitic hookworm infection characteristic of an intestinal region of the host. One of the main causes of human suffering is ancylostomiasis, also known as hookworm sickness (Miller, 1979). An estimate from the WHO states that there are over 800 million hookworm-infested persons worldwide and that the annual global mortality and morbidity are around 55,000 and 1.5 million, respectively (Schofield, 1985). Common clinical symptoms associated with hookworm infection include intestinal malabsorption of nutrients (Sheehy et al., 1962; Tandon et al., 1969), hypoalbuminemia (Roche and Layrissé, 1966), and significant intestinal blood loss resulting in iron deficiency anaemia. In golden hamsters (*Mesocricetus auratus*), the hookworm parasite *Ancylostomaceylanicum* of cats, dogs, and humans has been effectively maintained. This model system has been suitably investigated to know the pathogenesis of the disease (Visen et al., 1984). Gross pathological progression is observed in hookworm infection.

One key component of the glycolytic pathway is the enzyme lactate dehydrogenase (LDH). An important energy source for all living things is LDH. Lactate Dehydrogenase isoenzymes differ at the level of quaternary structures. The oligomeric lactate dehydrogenase

molecule(MW 130,00) consists of 4 protomers of 2 types, H and M. The isoforms called isozymes are named LDH-1 through LDH-5, each having differential expression in different tissues. (Drent et al.,1996). The human sera contains these isoenzymes significantly in certain pathogenic conditions. Hence, it is important from the clinical point of view to assess the functional impairment and damage to the tissue under study. In the final reversible step of glycolysis, it converts lactate to pyruvate or pyruvate to lactate. It is essential to the conversion of lactic acid and pyruvic acid. Reactions mediated by lactate dehydrogenase are reversible. All cells that can glycolyse have lactate dehydrogenase, which is NAD-specific.

Changes in lactate dehydrogenase enzyme patterns in Chinese Hamster cells infected with Simian Virus 40 were studied by Caltrider and Leyman(1975). Lactate Dehydrogenase isoenzymes in Hamster Lung Lavage Fluid after Lung Injury were studied by Beck et al.(1983). When *A.ceylanicum* was experimentally injected into hamsters, Khan et al. (1988) examined the blood/serum parameters of the animals and changes in the quantities of cellular components and the release of enzymes into the bloodstream. Quinnell(1988) investigated the host age and the growth and fecundity of *Hymenolepis diminuta* in the rat. Thonsri et al. (2016) worked on the overexpression of LDH in infected and control tissues. An essential metabolic enzyme called lactate dehydrogenase A (LDHA) is involved in the last stage of anaerobic glycolysis. Many human cancers exhibit overexpression of LDHA in correlation with the growth of the tumour. Kapczuk et al (2018) worked on the Selected Molecular Mechanisms Involved in the Parasite–Host System, *Hymenolepis diminuta–Rattus norvegicus*. Klein et al.(2020) studied the importance of Lactate Dehydrogenase and Its Isoenzymes in animals. Studies on the infection of *Hymenolepis diminuta* with rat's intestinal helminth showed effects on exploratory behaviour and cognitive processes (Blecharz-Klin, 2022). The literature review suggests that information regarding the influence of helminth infections in the alimentary canal on the lactate dehydrogenase of various tissues of the host *Mesocricetus auratus* is inadequate. In the present study, the author has attempted to study the lactate dehydrogenase content in the tissues of hamsters (*Mesocricetus auratus*) infected with hookworm (*Ancylostomaceylanicum*).

MATERIALS AND METHODS

Adult Syrian golden hamsters *Mesocricetus auratus* weighing between 40-50gms were used for the study. They were obtained from Animal House- National Institute of Nutrition(NIN), Hyderabad. They were housed in cages and fed with rodent food pellets and water. Faecal pellets from infected hamsters were collected from the Parasitology Department, IDPL Research Centre, Hyderabad. *Ancylostomaceylanicum* infective third stage larvae(L3) were harvested according to the method of Ray et al.(1972). The infective larvae were collected from the cultures using the Baermann technique (Beane and Hubbs,1983) and counted using Scott's dilution method (1928).The hamsters were administered orally with *Ancylostomaceylanicum* infective larvae and distilled water. After infection, hamsters were maintained under proper diet and environment. Confirmation of *Ancylostomaceylanicum* infection was made by examining the ova in the faecal pellets. The strain was maintained by regular passage in hamsters once a month. Hamsters were

anaesthetised with ether and dissected and *Ancylostomaceylanicum* worms were traced and observed in the small intestine. Fresh tissues such as the liver, intestine, spleen, kidneys, lungs, muscle and brain were collected. Excess moisture was removed by placing the tissue in Whatmann's No.1 filter paper. Fresh tissues were weighted separately and transferred immediately to a homogenising medium. The homogenisation was done using an ice-jacketed glass homogeniser with a motor-driven Teflon-coated pestle. It was used for the biochemical estimations of Lactate Dehydrogenase.

The Lactate dehydrogenase content was determined by Nachlas et al. method (1960). The sample size of the number of animals used for each tissue is 6, n=6. The tissue was homogenised in ice-cold 0.25M sucrose solution in approximately 3 % homogenate. The homogenate was centrifuged at 2500 rpm for 15 min. 0.5ml homogenate with 0.4ml sodium potassium phosphate buffer (7.4), 0.5ml sodium lactate (7.4), 0.5ml INT and 0.1ml NAD constituted the incubation mixture. After incubation for 30 min at $37 \pm 1^{\circ}\text{C}$, the reaction was stopped by adding 4ml of glacial acetic acid. The formazan formed was extracted by shaking with 4ml of toluene and then keeping it overnight in the refrigerator. The intensity of the colour of formazan developed was read at 495nm after setting the spectrophotometer to zero using toluene as blank. The enzyme activity was calculated with reference to the standard formazan graph and was expressed as μ moles of formazan mg protein/hr.

RESULTS

The total Lactate Dehydrogenase content was estimated in various tissues and serum of hamsters infected with hookworm and in the control. The results are given in tables 1 and 2 and are represented through histogram 1, graph 1. The lactate dehydrogenase content was found to be highest in the kidney and least in the spleen. It was observed that there was a decrease in the lactate dehydrogenase content in the liver, spleen, lung, serum and brain of the infected host while increased lactate dehydrogenase content in the intestine, muscle and kidneys. 't' values were calculated for different tissues and serum for lactate dehydrogenase content in *Mesocricetus auratus* induced with *Ancylostomaceylanicum* infection (table no. 2) at p value of 0.05 % statistically significant.

Table 1. Lactate Dehydrogenase Content in the different tissues and serum of *Mesocricetus auratus* induced with *Ancylostomaceylanicum* infection

S.No.	Tissues	Group	Probability	Units	% Change
1	Liver	Control	5.609 ± 0.375	mg/ g	(30.112 %)
	Liver	Infected	3.920 ± 0.144	mg/g	
2	Intestine	Control	4.816 ± 0.224	mg/g	(27.637%)
	Intestine	Infected	6.147 ± 0.076	mg/g	
3	Muscle	Control	3.557 ± 0.108	mg/g	(37.925 %)
	Muscle	Infected	4.906 ± 0.378	mg/g	
4	Kidney	Control	4.570 ± 0.371	mg/g	(56.369%)
	Kidney	Infected	7.146 ± 0.391	mg/g	
5	Spleen	Control	1.550 ± 0.052	mg/g	(17.613%)
	Spleen	Infected	1.277 ± 0.091	mg/g	
6	Lung	Control	4.390 ± 0.357	mg/g	(29.066 %)
	Lung	Infected	3.114 ± 0.053	mg/g	
7	Brain	Control	5.510 ± 0.259	mg/g	(23.811 %)
	Brain	Infected	4.198 ± 0.098	mg/g	
8	Serum	Control	5.216 ± 0.442	μ /ml	(45.618 %)
	Serum	Infected	2.836 ± 0.111	μ /ml	

Size of the sample of the number of animals used for each tissue is 6, n=6

For tissues, values are expressed as mg lactate / g wet weight of tissue

For serum, values are expressed as μ glucose/ml of serum

± indicates the standard deviation for control and experimental

Figures in parenthesis is percent change over control.

Table 2 . 't' values calculated for different tissues and serum for lactate dehydrogenase content in *Mesocricetus auratus* induced with *Ancylostomaceylanicum* infection

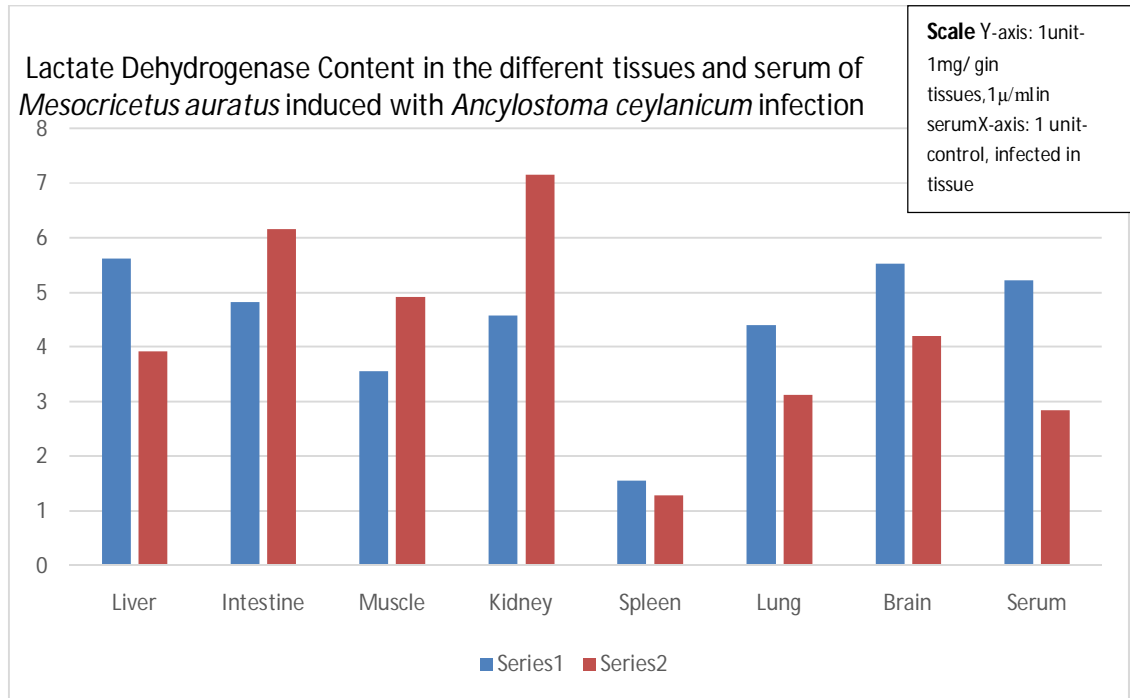
S.No.	Tissues	t-value	Values
1.	Liver	9.383	mg/ g
2.	Intestine	12.676	mg/g
3.	Muscle	7.709	mg/g
4.	Kidney	10.689	mg/g
5.	Spleen	5.809	mg/g
6.	Lung	7.925	mg/g
7.	Brain	10.581	mg/g
8.	Serum	11.719	μ /ml

Size of the sample of the number of animals used for each tissue is 6, n=6

For tissues, values are expressed as mg lactate / g wet weight of tissue

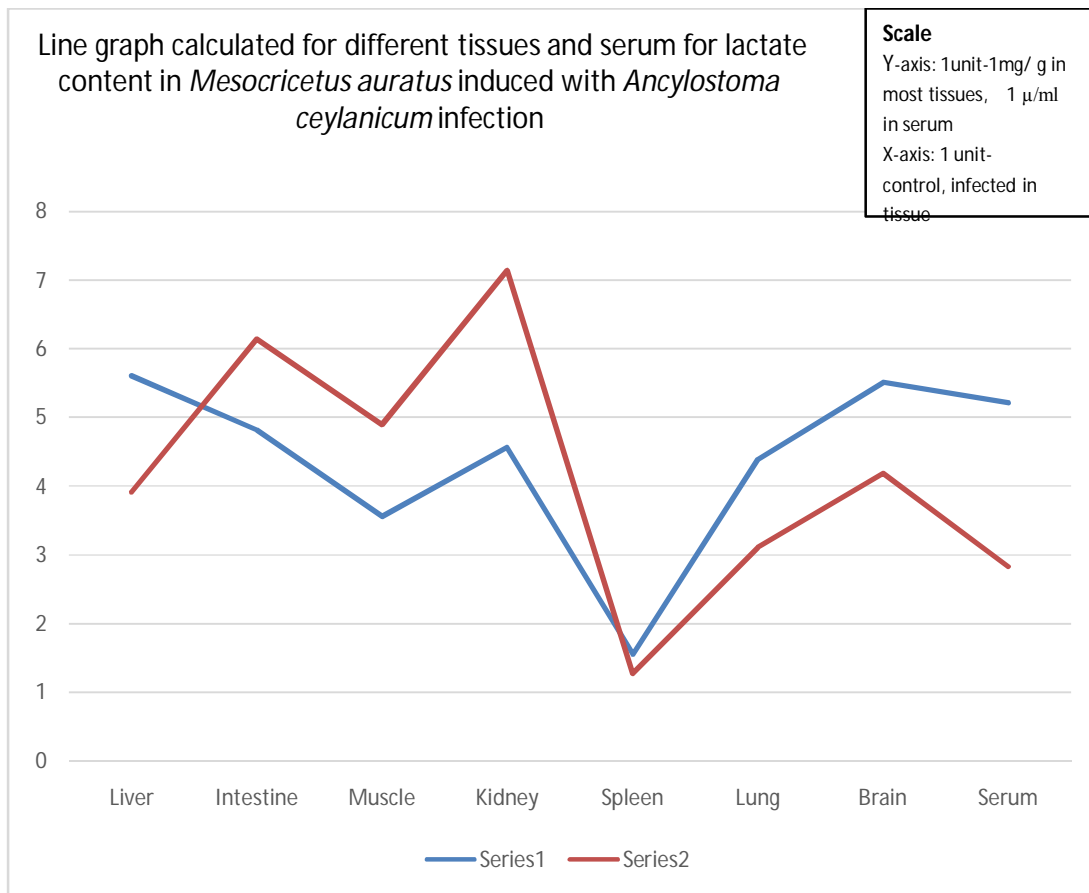
For serum, values are expressed as μ glucose/ml of serum

Histogram 1 Lactate Dehydrogenase Content in the different tissues and serum of *Mesocricetus auratus* induced with *Ancylostomaceylanicum* infection



Y axis: Lactate Dehydrogenase Content in mg/g (µ/ml in serum) X axis: Control and Infected Tissues: Liver, Intestine, Muscle, Kidney, Spleen, Lung, Brain and Serum

Graph No. 1. Line Graph calculated for different tissues and serum for lactate content in *Mesocricetus auratus* induced with *Ancylostomaceylanicum* infection



Y axis: Lactate Dehydrogenase Content in mg/g (μ /ml in serum) X axis: Control and Infected Tissues: Liver, Intestine, Muscle, Kidney, Spleen, Lung, Brain and Serum

Size of the sample of the number of animals used for each tissue is 6, n=6

For tissues, values are expressed as mg lactate / g wet weight of tissue

For serum, values are expressed as μ glucose/ml of serum

DISCUSSION

The results of the present study suggest that organs differ in the LDH enzyme activity during hookworm, *Ancylostomaceylanicum* infection in *Mesocricetus auratus*. It was observed that there was a decrease in the level of lactate dehydrogenase content in the liver, spleen, lung, brain and serum of the infected host. It may be presumed that the decreased LDH content is due to parasitic stress.

The increased LDH content was found in kidneys in the present study. Thus, lactic acid through gluconeogenesis i.e. kidney synthesises glucose which is then available for use by the glycolytic tissues, thus completing the cycle.

The increase in lactate dehydrogenase content in the intestine and muscle tissue in the present study suggests that the rapid conversion of pyruvate to lactate indicates rapid degradation of polysaccharides. A fairly high concentration of lactate dehydrogenase content means that more carbohydrate is channelled towards lactate production.

Infection with *Ancylostomaceylanicum* resulted in significant biochemical and histological abnormalities in golden hamsters (*Mesocricetus auratus*) (Mukherjee et al.,1988). In contrast to the liver, the major site of infection, the jejunum, exhibited substantial changes due to hookworm infection. In the jejunal tissues, there was an increase in the levels of lactate dehydrogenase suggesting that the glycolytic machinery was activated during hookworm infection (Mukherjee et al.,1988). The results of the present study conform with the studies carried out by Mukherjee et al(1988).

In some helminths under aerobic conditions, lactate is converted to pyruvate, which is incorporated into the tricarboxylic acid cycle to generate energy and under anaerobic conditions, the reoxidation of NADH to NAD occurs by the production of lactate by lactate dehydrogenase thus ensuring uninterrupted glycolysis even in the absence of oxygen by generation of NAD. Parasitic helminths seem able to fix carbon dioxide and produce lactate.

In the present study, quantitative estimation of lactate is carried out in golden hamsters induced with *Ancylostomaceylanicum* infection and increased LDH content was found in intestine, muscles and kidneys. The Lactate dehydrogenase activity in *Mesocricetus auratus* was altered due to infection by *Ancylostomaceylanicum*. *Ancylostomaceylanicus* also inflicted structural, functional and pathological changes in the various tissues of golden hamsters (*Mesocricetus auratus*). Many researchers have investigated the pathogenicity in the hamsters under helminth infection. (Bannon and Friedell(1966),; Tuetz(1976);(1982); Schmidt et al.(1982); Maxwell et al.(1985); Khan et al.(1988); Srivastava et al.(1988); Mukerjee et al.(1988;1992) .

CONCLUSION

Endoparasitic helminths of vertebrates host especially those living in the alimentary canal affect the host directly by absorbing the readily available digested food and injuring the alimentary canal's wall. As the host is deprived of its digested food, the absorption of other nutrient molecules is interfered with due to the presence of the parasites. The role of lactate dehydrogenase in parasite metabolism is studied in the present investigation revealing its relevance to the host's metabolism during the parasitic infection.

Declaration

As a researcher, I have put considerable effort into researching and preparing the research article. The article does not require ethical approval and consent.

Disclaimer(Artificial Intelligence)

The author, Dr. P. S. Rajani, declares that generative AI technologies Gemini of Google and AI of Grammarly and paraphrasing tools were used during the writing and editing of this manuscript.

REFERENCES

1. Bannon, P.D. and Friedell, G.H.(1966). Values for plasma constituents in normal and tumour bearing golden hamsters, *Lab. Anim. Care*, 16:417-420.
2. Beane, R.D. and Hubbs, N.T.(1983). The Baermann Technique for estimating prostostromylos infection in bighorn sheep: Effect of laboratory procedures. *Journal of Wildlife Diseases*, 19(1):7-9.
3. Beck, B.D., Gerson, B., Feldman, H.A., Brain, J.D.(1983). Lactate dehydrogenase isoenzymes in hamster lung lavage fluid after lung injury. *Toxicol Appl Pharmacol.*, 71(1):59-71. doi: 10.1016/0041-008x(83)90045-5.
4. Blecharz Klin, K., Świerczyńska, M., Piechal, A., Wawer, A., Joniec Maciejak, I., Pyrzanowska, J., Wojnar, E., Zawistowska Deniziak, A., Sulima Celińska, A., Młocicki, D., Mirowska Guzel, D.(2022). Infection with intestinal helminth (*Hymenolepis diminuta*) impacts exploratory behavior and cognitive processes in rats by changing the central level of neurotransmitters. *PLoS Pathog.* Mar 14;18(3):e1010330. doi: 10.1371/journal.ppat.1010330.
5. Caltrider, N. D. and Lehman, J.M.(1975). Changes in lactate dehydrogenase enzyme pattern in Chinese Hamster cells infected with Simian Virus 40. *Cancer Res.*, 35 (8): 1944–1949.
6. Drent, M., Cobben, N.A., Henderson, R.F., Wouters, E.F., Van Dieijen-Visser M.(1996). Usefulness of lactate dehydrogenase and its isoenzymes as indicators of lung damage or inflammation. *Eur Respir J.* 9(8):1736-42.
7. Kapczuk, P., Kosik Bogacka, D., ŁanochaArendarczyk, N., Gutowska, I., Kupnicka, P., Chlubek, D., Baranowska Bosiacka, I.(2018). Selected Molecular Mechanisms Involved in the Parasite–Host System *Hymenolepis diminuta–Rattus norvegicus*. *Int. J. Mol. Sci.* 19, 2435. <https://doi.org/10.3390/ijms19082435>.
8. Khan, M.M., Srivastava, A.K., Katiyar, J.C. Mishra, A. and Ghatak, S.(1988). *Ancylostomaceylanicum*: Studies on host metabolism using golden hamsters as experimental model. *Rivista di parassitologia*, 5(49(1): 112-117.
9. Klein R, Nagy O, Tóthová C, ChovanováF.(2020). Clinical and Diagnostic Significance of Lactate Dehydrogenase and Its Isoenzymes in Animals. *Vet Med Int.*, Jun 15;2020:5346483. doi: 10.1155/2020/5346483.
10. Maxwell, K.O., Wish, C., Murphy, J.C. and Fox, J.G.(1985). Serum chemistry reference values in two strains of Syrian hamsters, *Lab. Anim. Sci.* 35:67-70.
11. Miller, T. A. (1979). Hookworm infection in man. *Adv. Parasitol.* 17, 315-384.
12. Mukherjee, S., Tekwani, B. L., Tripathi, L.M., Maitra, S.C., Visen, P.K.S., Katiyar, J.C. and Ghatak, S.(1988). Biochemical and Histopathological Alterations in Golden Hamster during Infection with *Ancylostomaceylanicum*'. *Experimental and Molecular Pathology*, 49: 50-61.
13. Mukerjee, S., Upreti, R.K., Tekwani, B.L. and Kidwai, A.M.1992). Biochemical analysis of jejunal brush border membrane of golden hamsters, Pathogenic modulations due to ancylostomiasis, *Indian J. Biochem. Biophysics*, 29(1): 82-86.
14. Nachlas, M.M., Margulies, S. I. and Seligman, A.M.(1960). A colometric method for the estimation of succinate dehydrogenase activity, *J Bio Chem*, 235: 499-509.

15. Quinnell, RJ (1988). Host age and the growth and fecundity of *Hymenolepis diminuta* in the rat. *Journal of Helminthology*, 62 (2). 158 - 162. ISSN 0022-149X.
16. Ray, D.K., Bhopale, K.K. and Shrivastava, V.S.(1972). Migration and growth of *Ancylostomaceylanicum* in golden hamster *Mesocricetus auratus*, *J Helmin*, 46:357-362.
17. Roche, M., and Layrisse, M. (1966). The nature and causes of hookworm anaemia. *Amer. J. Trop. Med. Hyg.* 15:1032-1100.
18. Schmidit, R.E., Eason,R.L., Hubbard,G.B., Young, J.T. and Eisenbrandt, D.L. (1982). Pathology of Ageing hamsters, CRC press, inc. Boca Raton, Florida.
19. Schofield W.N. (1985). Predicting basal metabolic rate, new standards and review of previous work. *Hum Nutr Clin Nutr.* 39 Suppl 1:5-41. PMID: 4044297.
20. Scott, J.A.(1928). An experimental study of the development of *Ancylostoma caninum* in normal and abnormal hosts, *Am J Hyg*, 8:158-209.
21. Sheehy, T. W., Meroney, W. H., Cox, R. S., J.R, and Soler, J. E. (1962). Hookworm disease and malabsorption. *Gastroenterology*, 42, 148-156.
22. Srivastava, J.K., Suman Gupta and Katiyar, J.C.(1988). Effects of CDRI compounds on energy metabolism of *Ancylostomaceylanicum* and *Nippostrongylus brasiliensis*, *Ind. J. Expt. Biology*, 27(8):735-738.
23. Tandon, B. N., Kohli, R. K., Saraya, A. K., Ramchandran, K., and Prakash, O. (1969). Role of parasites in the pathogenesis of intestinal malabsorption in hookworm disease. *Gut*, 10, 293-298.
24. Thomas, E. D., Buckner, C. D., Clift, R.A., Fefer, A., Leonard Johnson, F., Neiman, P.E., Sale, G.E., Sanders, J. E., Singer, W., Shulman, H., Storb, R. and Weiden, P.L.(1979). Marrow Transplantation for Acute Nonlymphoblastic Leukemia in First Remission. *N Engl J Med*,301:597-599.DOI: 10.1056/NEJM197909133011109, 301 (11)
25. Thonsri, Unchalee&Seubwai, Wunchana&Waraasawapati, Sakda &Sawanyawisuth, Kanlayanee&Vaeteewoottacharn, Kulthida&Boonmars, Thidarat&Cha'on, Ubon. (2016). Overexpression of lactate dehydrogenase A in cholangiocarcinoma is correlated with poor prognosis. *Histology and histopathology.* 32. 11819. 10.14670/HH-11-819.
26. Tietz, N.W.(1976). "Fundamentals of Clinical Chemistry". Saunders Philadelphia, Pennsylvania.
27. Visen, P. K. S., Katiyar, J. C., and Sen, A. B. (1984). Studies on infectivity, longevity and fecundity of *Ancylostomaceylanicum* in golden hamsters. *J. Helminthol.* 58: 159-163.