

## Studies of the lactate dehydrogenase content in tissues of *mesocricetus auratus* infected with *ancylostomaceylanicum*

### ABSTRACT

The helminthic infection that affects tropical and subtropical regions is an endoparasitic hookworm infection characteristic of an intestinal region of the host. Hookworm infections have been reported in several lab animals. The hookworm has a specific hook-like structure at the anterior end which helps the parasite to extract nutrients from the host. Metabolic disorders and severe disruptions in tissue structure and function are caused by hookworm infection. In the current investigation, *Ancylostomaceylanicum*, a hookworm was infected in the host, a hamster *Mesocricetus auratus* experimentally. The infected host was then studied by taking the parameter of Lactate Dehydrogenase activity in various tissues. The Lactate Dehydrogenase content in *M. auratus* was investigated in both the infected and control samples. The total Lactate Dehydrogenase content was estimated biochemically in the hamsters and results revealed that the intestinal and muscle tissue had enhanced levels. The results showed decreased LDH content in the liver, kidney, spleen, lungs, brain and serum. Lower levels of Lactate Dehydrogenase in certain tissues could indicate lesser synthesis of Lactate Dehydrogenase as the anaerobic conditions prevail in the intestinal region of the host infected with hookworm infection. Determining the total amount of Lactate Dehydrogenase in the host tissues, *M. auratus*, can help determine the pathogenicity level of an *A. ceylanicum* infection. The present paper reveals the intricacies of the Lactate dehydrogenase level in the infected Hamster and its relevance in enzyme biochemistry.

KEYWORDS: *Ancylostomaceylanicum*, Hamster, *Mesocricetus auratus*, infection, hookworm

### INTRODUCTION

One of the main causes of human suffering is ancylostomiasis, also known as hookworm sickness (Miller, 1979). A recent estimate from the WHO states that there are over 800 million hookworm-infested persons worldwide, and that the annual global mortality and morbidity are around 55,000 and 1.5 million, respectively (Schofield, 1985). Common clinical symptoms associated with hookworm infection include intestinal malabsorption of nutrients (Sheehy et al., 1962; Tandon et al., 1969), hypoalbuminemia (Roche and Layrisse, 1966), and significant intestinal blood loss resulting in iron deficiency anemia. In golden hamsters (*Mesocricetus auratus*), the hookworm parasite *Ancylostomaceylanicum* of cats, dogs, and humans has been effectively maintained. This model system has been suitably investigated for understanding the pathogenesis of the disease (Visen et al., 1984). Gross pathological progression is observed in hookworm infection. One key component of the glycolytic pathway is the enzyme lactate dehydrogenase (LDH). An important energy source for all living things is LDH. Lactate Dehydrogenase isoenzymes differ at the level of quaternary structures. The oligomeric lactate dehydrogenase molecule (MW 130,00) consists of 4 protomers of 2 types, H and M. Only the tetrameric molecule possesses catalytic activity. These protomers of lactate dehydrogenase would then be a hybrid containing various proportions of each of the protomer so that five isoenzymes are formed in the following ways: HHHH, HHHM, HHMM, HMMM, and MMMM. The pattern of isozymes in different tissues is found differently. The human sera contains significantly in certain pathogenic conditions. Hence, it is important from the clinical point of view to assess the functional impairment and damage to the tissue under study. In the final reversible step of glycolysis, it converts lactate to pyruvate or pyruvate to lactate. It is essential to the conversion of lactic acid and pyruvic acid. Reactions mediated by lactate dehydrogenase are reversible. All cells that can glycolyse have lactate dehydrogenase, which is NAD-specific. Under anaerobic circumstances, lactate is produced from the normal end product of glycolysis, pyruvate, in Aerobic

### REVIEW OF LITERATURE

The review of literature shows the research in the areas of Lactate dehydrogenase in the host by various researchers. Some of the prominent research has been analysed. Changes in lactate dehydrogenase enzyme patterns in Chinese Hamster cells infected with Simian Virus 40 were studied by Caltrider and Leyman (1975). Lactate Dehydrogenase isoenzymes in Hamster Lung Lavage Fluid after Lung Injury were studied by Beck et al. (1983). When *A. ceylanicum* was experimentally injected into hamsters, Khan et al. (1988) examined the blood/serum parameters of the animals and noticed changes in the quantities of cellular components as well as the release of enzymes into the bloodstream. Quinnell (1988) investigated the host age and the growth and fecundity of *Hymenolepis diminuta* in the rat. Thonsri et al. (2016) investigated the overexpression of LDH in infected and control tissues. An essential metabolic enzyme called lactate dehydrogenase A (LDHA) is involved in the last stage of anaerobic glycolysis. Many human cancers exhibit overexpression of LDHA in correlation with the growth of tumor. An essential metabolic enzyme called lactate dehydrogenase A (LDHA) is involved in the last stage of anaerobic glycolysis. Using the immunohistochemical method, the expression of LDHA was examined in 82 human and 60 hamster CCA tissues. A method was used to measure the plasma LDH of healthy controls (n = 40) and CCA patients (n = 29). Kapczuk et al. (2018) worked on the Selected Molecular Mechanisms Involved in the Parasite-Host System, *Hymenolepis diminuta*-*Rattus norvegicus*. Klein et al., 2020 studied the importance of Lactate Dehydrogenase and Its Isoenzymes in animals. Studies on the infection of *Hymenolepis diminuta* with rat's intestinal helminth showed effects on exploratory behaviour and cognitive processes (Blecharz-Klin, 2022). The literature review suggests that information regarding the influence of helminth infections in the alimentary canal on the lactate dehydrogenase of various tissues of the host *Mesocricetus auratus* is inadequate. In the present study, the author has attempted to study the lactate dehydrogenase content in the tissues of hamsters (*Mesocricetus auratus*) infected with hookworm (*Ancylostomaceylanicum*).

### METHODOLOGY

The Lactate dehydrogenase content was determined using the Barker and Summerson (1941) modified by Huckabee (1961). 2ml of protein-free supernatant, 5 ml of freshly prepared lithium lactate standard solution and a reagent blank (2ml of distilled water) were taken in three separate centrifuge tubes. To all the tubes 1 ml of 20% copper sulphate solution was added and were made to 10 ml by adding double distilled water. 1 g of calcium hydroxide was added to each tube. All the tubes were left for 30 min with frequent shakings. Then the tubes were centrifuged for 15 mts at 2,500 rpm. 1 ml of supernatant from each of the centrifuge tubes was taken in 3 separate tubes. Into each test tube, 6 ml of chilled analarsulphuric acid was added. All the tubes were boiled in

Comment [h1]: experimental

Comment [h2]: too much emphasis on the introduction

Comment [h3]: rephrase, capture the aim of the study.

Comment [h4]: What informed the decision to study the lactate dehydrogenase content? In other words what is the justification for this study.

Comment [h5]: How? Give reasons

Comment [h6]: The study showed.....

Comment [h7]: How?

Comment [h8]: A reference of 1985 cannot be quoted as recent.

Comment [h9]: No reference cited.

Comment [h10]: Literature review should be merged with introduction.

Comment [h11]: Summarize

Comment [h12]: Materials and Methods is more appropriate

### Review Form 3

a water bath for 5 min and cooled to 20°C. 2 drops of 4% copper sulphate solution were added to all the tubes. 0.5 ml of parahydroxy diphenyl reagent was added and shaken thoroughly. All the tubes were incubated at 30±1°C for 30 min and then boiled for 90 sec and were allowed to cool to room temperature. The colour was read at 720 nm. against blank in spekol. The values were expressed as mg lactate/g wet weight of the tissue.

### RESULTS

The total Lactate Dehydrogenase content was estimated in various tissues and serum of hamsters infected with hookworm and in the control. The results are given in table no.1, 2 and are represented through histogram no.1, graph no.1. The results obtained in the various tissues of the control animals are indicated as liver 5.609±0.375, intestine 4.816±0.224, muscle 3.557±0.108, kidney 4.570±0.371, spleen 1.550±0.052, lung 4.390±0.357, brain 5.510±0.259 μ moles of formazan /mg protein/hr and in serum 216±0.442 μ moles of formazan/ml/hr.

Table 1. Lactate Content in the different tissues and serum of *Mesocricetus auratus* induced with *Ancylostomaceylanicum* infection

circumstances

S.No.	Tissues	Group	Probability	% Change
1	Liver	Control	5.609 ± 0.375	(30.112 %)
	Liver	Infected	3.920 ± 0.144	
2	Intestine	Control	4.816 ± 0.224	(27.637%)
	Intestine	Infected	6.147 ± 0.076	
3	Muscle	Control	3.557 ± 0.108	(37.925 %)
	Muscle	Infected	4.906 ± 0.378	
4	Kidney	Control	4.570 ± 0.371	(56.369%)
	Kidney	Infected	7.146 ± 0.391	
5	Spleen	Control	1.550 ± 0.052	(17.613%)
	Spleen	Infected	1.277 ± 0.091	
6	Lung	Control	4.390 ± 0.357	(29.066 %)
	Lung	Infected	3.114 ± 0.053	
7	Brain	Control	5.510 ± 0.259	(23.811 %)
	Brain	Infected	4.198 ± 0.098	
8	Serum	Control	5.216 ± 0.442	(45.618 %)
	Serum	Infected	2.836 ± 0.111	

For tissues, values are expressed as mg lactate / g wet weight of tissue

For serum, values are expressed as μ glucose/ml of serum

**Comment [h13]:** First state the experimental animals, acclimatization protocol, animal grouping and how infection was induced in the animals. Also provide a statement and reference on ethical consideration. State how long the experiment lasted. Provide information on Animal Sacrifice, before going on to state biochemical analysis (LDH activity assay)

**Comment [h14]:** State the Statistical Analysis used before moving to result.

**Comment [h15]:** delete

**Comment [h16]:** delete

**Comment [h17]:** provide the statistical differences between control and test groups and not values, these values will be seen in your tables.

**Comment [h18]:** What do you mean by probability? Provide the units for LDH on the table not as footnote, and state the number of animals used e.g. n=4

**Comment [h19]:** Table not well presented. Please refer to published articles in this journal to see how results are presented.

### Review Form 3

± indicates the standard deviation for control and experimental

Figures in parenthesis is percent change over control.

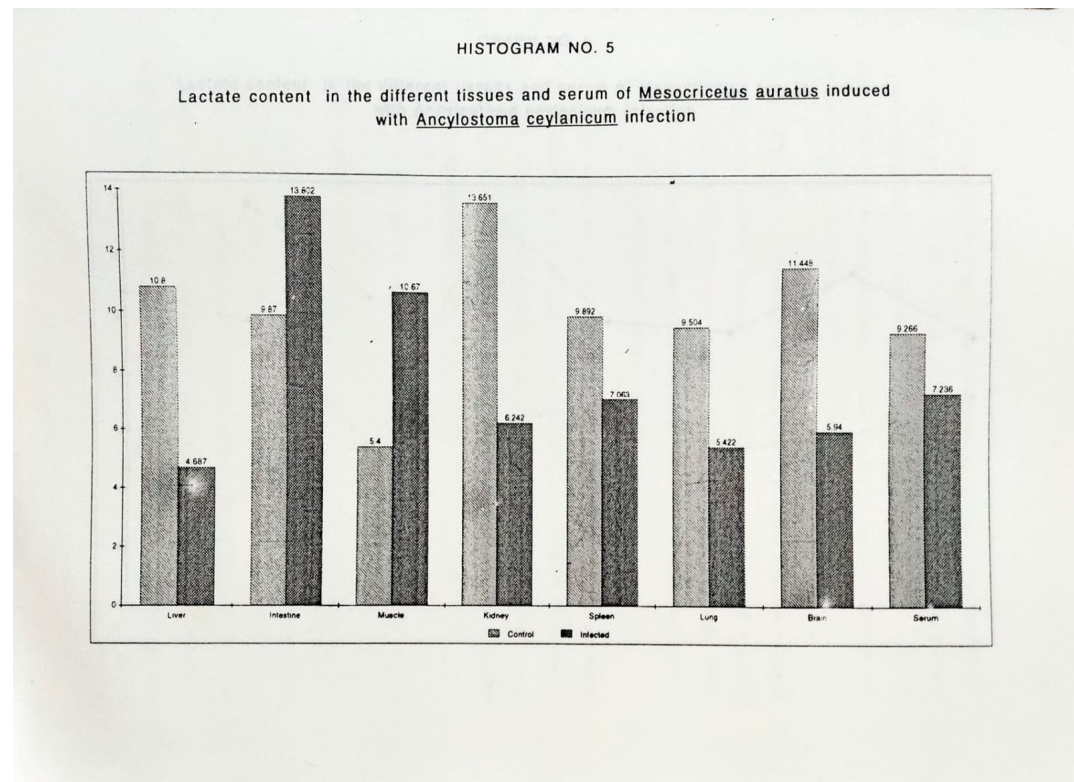
Table 2 .t' values calculated for different tissues and serum for lactate dehydrogenase content in *Mesocricetus auratus* induced with *Ancylostomaceylanicum* infection

S.No.	Tissues	t-value	Probability	Remarks
1.	Liver	9.383	P <0.05	Significant
2.	Intestine	12.676	P <0.05	Significant
3.	Muscle	7.709	P <0.05	Significant
4.	Kidney	10.689	P <0.05	Significant
5.	Spleen	5.809	P <0.05	Significant
6.	Lung	7.925	P <0.05	Significant
7.	Brain	10.581	P <0.05	Significant
8.	Serum	11.719	P <0.05	Significant

Comment [h20]: Same as above in table 1

Histogram 1

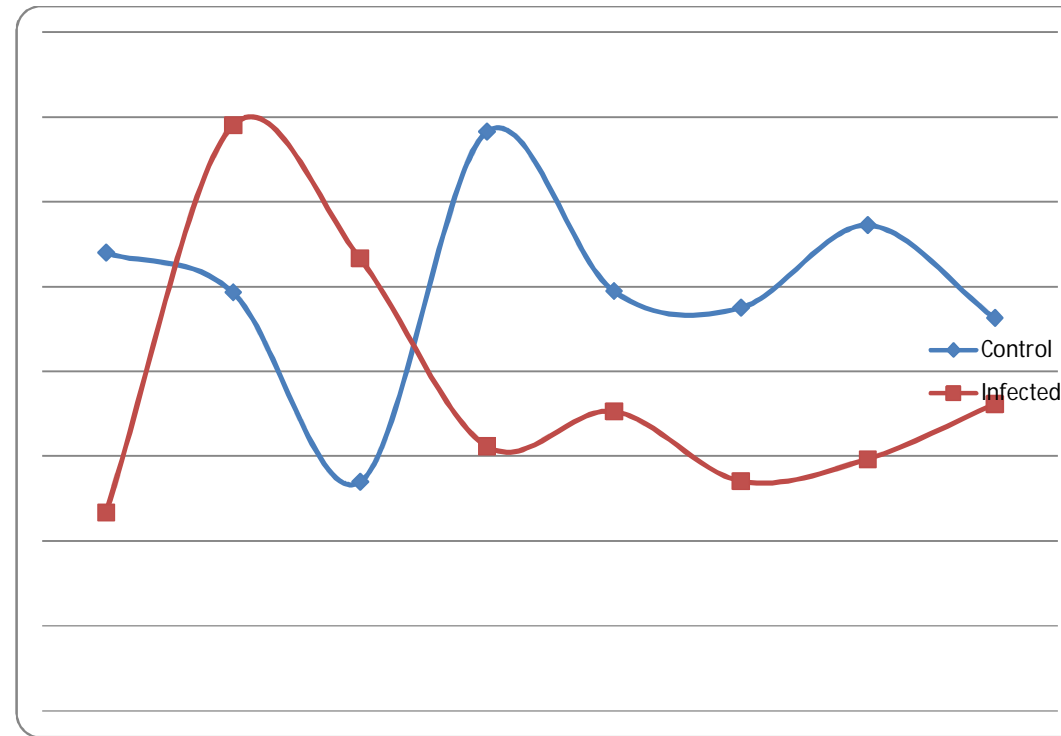
Review Form 3



Graph No. 1. Histogram calculated for different tissues and serum for lactate content in *Mesocricetus auratus* induced with *Ancylostomaceylanicum* infection

Comment [h21]: Why snapped result?

### Review Form 3



Comment [h22]: No footnote

### DISCUSSION

The results of the present study suggest that organs differ in the LDH enzyme activity during hookworm infection. It was observed that there was a decrease in the level of lactate content in the liver, kidney, spleen, lung and brain of the infected host which suggests that the lactic acid is not being accumulated. Since accumulated lactate has to be excreted or metabolised and the host, being an aerobic animal in which lactate excretion is impossible, the only alternative left is its metabolism, therefore the lactate may be converted into pyruvate or may enter the gluconeogenic pathway. Lactate level in the serum of infected hamsters which is depleted over the control (Thomas et al. 1979) indicates its utilization in the metabolism. Further, the decrease in the level of lactate dehydrogenase activity in the tissues (liver, brain, kidney, spleen, lung) and serum may be presumed that the decreased lactate content may not be due to its conversion to pyruvate but due to increased rate of production. Venous blood of the skeletal muscle under all conditions contains more lactate than arterial blood, thus this skeletal muscle always makes a net contribution of blood lactate. The process of glycolysis in glycolytic and other tissues results in increased accumulation of lactic acid, indicating loss of glycogen and glucose. Since lactic acid is not excreted in the urine and does not accumulate continuously in the blood during stress there must be processes to dispose of some of the lactate formed.

Comment [h23]: Reference

During strenuous activity, blood lactate level rises as much of the muscle lactate passes into the blood and then to the liver where it is resynthesised to glucose and glycogen. The remaining lactate is oxidised to carbon dioxide and water. Glycolytic and other tissues contribute lactate to the blood. Roughly 10% (500ml/min) of the heart's output passes through the hepatic artery. Further 20% of the heart's production passes through the kidneys thus about 1/3 of the blood lactate at any one time can be used for gluconeogenesis. In the liver about 40% of the lactate and 10% in the kidney received is converted to glucose. Thus, lactic acid through gluconeogenesis i.e. (liver, kidney) synthesise glucose which is then available for use by the glycolytic tissues thus completing the cycle. Studies on the increase of lactate content in intestine, muscle tissue suggests that the increase may be due to the rapid conversion of pyruvate to lactate indicating rapid degradation of polysaccharides. A fairly high concentration of lactate is suggestive of the fact that more carbohydrate is channeled towards lactate production. Infection with *Ancylostomaceylanicum* resulted in significant biochemical and histological abnormalities in golden hamsters (*Mesocricetus auratus*) (Mukherjee et al., 1988). In contrast to the liver, the major site of infection, the jejunum, exhibited substantial changes. While the jejunum's biochemical makeup remained mostly unchanged, hookworm infection increased the activity of a few lysosomal enzymes. Variations in the activity of the marker enzymes from the jejunal tissue resulted in significant damage to the mitochondrial and microsomal membranes. In the jejunal tissues, there was an increase in the levels of lactate dehydrogenase, phosphofructokinase, and hexokinase, suggesting that the glycolytic machinery was activated during hookworm infection. These results are in confirmation of the present study.

The estimation of lactate content can also offer some idea about the acidity and alkalinity in the body fluids etc. Because of the role of the liver and kidney in converting lactic and pyruvic acids into glucose and glycogen, the determination of the lactate and pyruvate content gives information as to why the total carbohydrate, glycogen and glucose content has increased or decreased. Lactic acid content in the golden hamster has been estimated by Thomas et al (1979). In parasitic helminths, lactate without being further metabolized is excreted out. Lactate is found to be an important metabolic end product in many of the parasitic helminths. In some helminths under aerobic conditions, lactate is converted to pyruvate, which is incorporated into the tricarboxylic acid cycle to generate energy and under anaerobic conditions, the reoxidation of NADH to NAD occurs by the production of lactate by lactate dehydrogenase thus ensuing uninterrupted glycolysis even in the absence of oxygen by generation of NAD. Parasitic helminths seem able to fix carbon dioxide and produce lactate. In the present study quantitative estimation of lactate is carried out in golden hamsters induced with *Ancylostomaceylanicum* infection. Several physiological changes occur in the host. Gastrointestinal helminth infection inflicts a variety of structural, functional and pathological changes in the various tissues of golden hamsters (*Mesocricetus auratus*). Various researchers have investigated the pathogenicity in the hamsters under helminth infection. Bannon and Friedell(1966); Tuetz(1976);(1982); Schmidt et al.(1982); Maxwell et al(1985); Khan et al(1988); Srivastava et al(1988); Mukerjee et al.(1988;1992).

## Review Form 3

### CONCLUSION

Endoparasitic helminths of vertebrates host especially those living in the alimentary canal affect the host directly by absorbing the readily available digested food and injuring the alimentary canal's wall. As the host is deprived of its digested food, the absorption of other nutrient molecules is interfered with due to the presence of the parasites. The role of lactate dehydrogenase in parasite metabolism is studied in the present investigation revealing its relevance to the host's metabolism during the parasitic infection.

### REFERENCES

1. Caltrider, N. D. and Lehman, J.M.(1975). Changes in lactate dehydrogenase enzyme pattern in Chinese Hamster cells infected with Simian Virus 40. *Cancer Res.*, 35 (8): 1944–1949.
2. Beck, B. D., Gerson, B., Feldman, H. A. and Brain, J. D.(1983). Lactate Dehydrogenase Isoenzymes in Hamster Lung Lavage Fluid after Lung Injury was studied by Barbara et al.(1983). *Toxicology and Applied Pharmacology*, 71, 59-71.
3. Mukherjee, S., Tekwani, B. L., Tripathi, L.M., Maitra, S.C., Visen, P.K.S., Katiyar, J.C. and Ghatak, S.(1988). Biochemical and Histopathological Alterations in Golden Hamster during Infection with *Ancylostomaceylanicum*. *Experimental and Molecular Pathology*, 49, 50-61.
4. Blecharz Klin, K., Świerczyńska, M., Piechal, A., Wawer, A., Joniec Maciejak, I., Pyrzanowska, J., Wojnar, E., Zawistowska Deniziak, A., Sulima Celińska, A., Młocicki, D., Mirowska Guzel, D. Infection with intestinal helminth (*Hymenolepisdiminuta*) impacts exploratory behavior and cognitive processes in rats by changing the central level of neurotransmitters. *PLoS Pathog.* 2022 Mar 14;18(3):e1010330. doi: 10.1371/journal.ppat.1010330. PMID: 35286352; PMCID: PMC8947016.
5. Barker, S.B. and Summerson, W.H. (1941) The Colorimetric Determination of Lactic Acid in Biological Material. *Journal of Biological Chemistry*, 138, 535-554. <http://www.jbc.org/content/138/2/535.full.pdf>.
6. Huckabee, W.E.(1961). Abnormal resting blood lactate. I. The significance of hyperlactatemia in hospitalized patients. *Am J Med.* 1961 Jun;30:840-8. doi: 10.1016/0002-9343(61)90172-3. PMID: 13716482.
7. Thomas, E. D., Buckner, C. D., Clift, R.A., Fefer, A., Leonard Johnson, F., Neiman, P.E., Sale, G.E., Sanders, J. E., Singer, W., Shulman, H., Storb, R. and Weiden, P.L.(1979). Marrow Transplantation for Acute Nonlymphoblastic Leukemia in First Remission. *N Engl J Med*,1979;301:597-599.DOI: 10.1056/NEJM197909133011109. [VOL. 301 NO. 11](#)
8. Miller, T. A. (1979). Hookworm infection in man. *Adv. Parasitol.* 17, 315-384. (Schofield, 1985).
9. Tandon, B. N., Kohli, R. K., Saraya, A. K., Ramchandran, K., and Prakash, O. (1969). Role of parasites in the pathogenesis of intestinal malabsorption in hookworm disease. *Gut*, 10, 293-298.
10. Sheehy, T. W., Meroney, W. H., Cox, R. S., J.R, and Soler, J. E. (1962). Hookworm disease and malabsorption. *Gastroenterology* 42, 148-156.
11. Shonk, C. E., and Boxer, G. E. (1964). Enzyme patterns in human tissues. 1. Methods for the determination of glycolytic enzymes. *Canad. Res.* 24, 709-721.
12. Visen, P. K. S., Katiyar, J. C., and Sen, A. B. (1984). Studies on infectivity, longevity and fecundity of *Ancylostomaceylanicum* in golden hamsters. *J. Helminthol.* 58, 159-163.
13. Roche, M., and Layrisse, M. (1966). The nature and causes of hookworm anaemia. *Amer. J. Trop. Med. Hyg.* 15, 1032-1100.
14. Maxwell, K.O., Wish, C., Murphy, J.C. and Fox, J.G.(1985). Serum chemistry reference values in two strains of Syrian hamsters, *Lab. Anim. Sci.* 35:67-70.
15. Bannon, P.D. and Friedell, G.H.(1966). Values for plasma constituents in normal and tumour bearing golden hamsters, *Lab. Anim. Care*, 16:417-420.
16. Mukerjee, S., Tekwani, B.L.,Tripathi, L.M., Maitra, S.C., Visen, P.K., Katiyar, J.C. and Ghatak, S.(1988). Biochemical and histopathological alterations in golden hamsters during infection with *Ancylostomaceylanicum*. *Exp. Mol-Pathol.*, 49(1): 50-51.
17. Mukerjee, S., Upreti, R.K., Tekwani, B.L. and Kidwai, A.M.1992). Biochemical analysis of jejunal brush border membrane of golden hamsters, Pathogenic modulations due to ancylostomiasis, *Indian J. Biochem. Biophysics*, 29(1): 82-86.
18. Khan, M.M., Srivastava, A.K., Katiyar, J.C. Mishra, A. and Ghatak, S.(1988). *Ancylostomaceylanicum*: Studies on host metabolism using golden hamsters as experimental model. *Rivista di parassitologia*, 5(49(1): 112-117.
19. Tietz, N.W.(1976). "Fundamentals of Clinical Chemistry". Saunders Philadelphia, Pennsylvania.
20. Schmidt, R.E., Eason,R.L., Hubbard,G.B., Young, J.T. and Eisenbrandt, D.L. (1982). Pathology of Ageing hamsters, CRC press, inc. Boca Raton, Florida.
21. Srivastava, J.K., Suman Gupta and Katiyar, J.C.(1988). Effects of CDRI compounds on energy metabolism of *Ancylostomaceylanicum* and *Nippostrongylusbrasiliensis*, *Ind. J. Expt. Biology*, 27(8):735-738.
22. Klein R, Nagy O, Tóthová C, Chovanová F. Clinical and Diagnostic Significance of Lactate Dehydrogenase and Its Isoenzymes in Animals. *Vet Med Int.* 2020 Jun 15;2020:5346483. doi: 10.1155/2020/5346483. PMID: 32607139; PMCID: PMC7313120.
23. Thonsri, Unchalee&Seubwai, Wunchana&Waraasawapati, Sakda &Sawaryawisuth, Kanlayanee&Vaeteewoottacharn, Kulthida&Boonmars, Thidarat&Cha'on, Ubon. (2016). Overexpression of lactate dehydrogenase A in cholangiocarcinoma is correlated with poor prognosis. *Histology and histopathology.* 32. 11819. 10.14670/HH-11-819.
24. Quinnell, RJ (1988). Host age and the growth and fecundity of *Hymenolepisdiminuta* in the rat. *Journal of Helminthology*, 62 (2). 158 - 162. ISSN 0022-149X

Comment [h25]: What are these relevance of LDH?

Comment [h26]: ?

Comment [h27]: Author did not follow the guidelines on the format on reference presentation'