

Original Research Article

Evaluating the Efficacy and Safety of Voriconazole in the Treatment of Dermatophyte Infections: A Cross-Sectional Observational Study

ABSTRACT

Background: Dermatophyte infections are prevalent fungal conditions affecting the skin, hair, and nails, often leading to discomfort and potential complications if untreated. Voriconazole, a triazole antifungal, is effective against various fungal pathogens but its role in treating dermatophyte infections remains under-researched. **Objective:** This study aimed to evaluate both the efficacy and safety of voriconazole in treating dermatophyte infections. **Methods:** This cross-sectional and observational study took place at the Community Based Medical College Hospital, Bangladesh, from January 2023 to January 2024. A total of 163 dermatophyte patients were recruited based on the researched simple clinical protocol, which was based on assessing dermatological features, lesion morphology, age of onset, and distribution sites. Adult patients received oral voriconazole 200 mg twice daily for four weeks, and response to treatment was assessed by complete clearance of lesions and repigmentation or return to normal skin color. **Results:** Most participants were 35 years or younger (53.4%) and female (63.2%). In most cases (68.7%), lesions lasted between 6 months and 1 year. At baseline, 74.8% were classified as having severe conditions, while 20.2% experienced moderate severity. As a result, 91% of participants were fully cured, and 9% were moderately cured. Rash, visual disturbances, nausea, vomiting, and headache were observed in some cases as side effects. **Conclusion:** Although there is strong evidence portraying the effectiveness of voriconazole for the management of dermatophytes, the study has some shortcomings, including a small sample size, no control group, and a shorter follow-up period. More work should be directed towards the publication of large sample-sized, randomized controlled trials comparing voriconazole with other systemic antifungal agents, the identification of patterns of resistance over a longer time period, and research on a more diverse population.

Keywords: Antifungal, Dermatophyte patients, Efficacy, Safety, Tinea infection, Voriconazole

INTRODUCTION

Dermatophytosis, or ringworm, is a widespread fungal infection targeting the skin, hair, and nails, primarily caused by keratinophilic fungi known as dermatophytes [1]. Despite their superficial nature, these infections can cause significant morbidity due to their chronic and recurrent nature. According to the World Health Organization, dermatophyte infections impact approximately 25% of the global population, underscoring their substantial public health burden [2]. Dermatophytes mainly come from three genera: Trichophyton, Microsporum, and Epidermophyton, with Trichophyton rubrum being the most frequently implicated species in human infections [3]. The clinical manifestations of dermatophytosis can vary based on the infection site, with common forms including tinea corporis and tinea cruris [4]. These infections usually appear as annular, scaly, erythematous plaques that are often itchy and may extend significantly if untreated. Transmission occurs through direct contact with infected people or animals, or through contact with contaminated surfaces or objects, which enhances their spread in communal settings [5]. The pathogenesis of these infections involves several factors, notably the fungi's ability to adhere to and invade keratinized tissues [6]. Once the arthroconidia (infectious spores) contact the skin, they germinate and penetrate the stratum corneum, leading to colonization and subsequent inflammation [7]. The host's immune response plays a vital role in controlling dermatophyte infections, but immunocompromised individuals may experience more severe symptoms due to inadequate immune defenses [8]. Treatment options for dermatophytosis include both topical and systemic antifungal agents [9]. Topical treatments like clotrimazole and terbinafine are effective for localized cases, while systemic therapies such as griseofulvin and voriconazole are often necessary for extensive or resistant infections [2]. Voriconazole, an azole antifungal with broad-spectrum activity, has demonstrated promise in treating resistant dermatophyte infections, offering a valuable option when conventional therapies are ineffective [5]. However, managing dermatophyte infections remains challenging due to issues like drug resistance and misdiagnosis [10]. Studies have shown that resistance rates among dermatophytes to commonly used antifungals are rising, highlighting the need for continuous surveillance and

research into alternative therapeutic strategies [6,8]. Accurate diagnosis is crucial for effective treatment; misdiagnoses can lead to inappropriate therapies and deterioration, especially in immunocompromised patients at higher risk for invasive disease [4]. This observational study aims to evaluate the efficacy of voriconazole in treating patients with dermatophyte infections. By analyzing clinical outcomes and potential adverse effects associated with voriconazole therapy, the study seeks to provide insights that can inform clinical practice and improve patient management strategies for this prevalent yet challenging infection.

METHODOLOGY

This was a cross-sectional observational study that was conducted in the Department of Dermatology and Venereology, Community Based Medical College Hospital, Bangladesh from January 2023 to January 2024. Using purposive sampling, a total of 163 patients with dermatophyte infections were enrolled in the study. The diagnosis was based on clinical assessments, which involved evaluating lesion morphology, age of onset, and distribution sites. A detailed history and thorough physical examination were conducted to reach a clinical diagnosis. Clinical conditions were recorded, including hematological and biochemical profiles, such as total and differential blood counts, ESR, platelet count, random blood sugar, and serum levels of ALT and creatinine. All patients received oral Voriconazole at 200 mg twice daily for 4 weeks. Efficacy was assessed at the end of the treatment period using a four-point scale, with results recorded and analyzed to prepare the outcome. Follow-ups were conducted at the end of the fourth and eighth weeks of treatment. Data analysis was carried out using **MS Office 16**.

RESULT

In terms of age, most of our participants (53.4%) were 35 years or younger, followed by 35.0% who were aged between 35 and 50 years, and 11.7% who were between 50 and 65 years old. Female participants made up 63.2% of the cohort, while males accounted for 36.8%. Regarding family history, 19.0% of participants reported a familial connection to dermatophyte infection. The most common sites of infection were tinea cruris (39.9%), followed by tinea corporis (20.9%), tinea magnum (16.0%), tinea pedis (12.9%), and tinea versicolor (10.4%). Most lesions (68.7%) lasted between 6 months and 1 year, 20.9% lasted less than 6 months, and 10.4% persisted for more than 2 years. The baseline severity status showed that 4.9% of participants had mild conditions, 20.2% experienced moderate severity, and a significant majority, 74.8%, were classified as having severe conditions. In terms of outcomes, 91% of participants were fully cured, while 9% were moderately cured. During the study, the use of voriconazole led to side effects in some cases, including rash, visual disturbances, nausea, vomiting, and headache.

Table 1: Demographic data

Characteristics	n	%
Age distribution (Year)		
≤35	87	53.4%
35-50	57	35.0%
50-65	19	11.7%
Gender distribution		
Male	60	36.8%
Female	103	63.2%

Table 2: Clinical data

Characteristics	n	%
Family history		
Yes	31	19.0%
No	132	81.0%
Types (site) of infections		
Tinea cruris	65	39.9%

Tinea corporis	34	20.9%
Tinea magnum	26	16.0%
Tinea pedis	21	12.9%
Tinea versicolor	17	10.4%
Duration of lesion		
Less than 6 months	34	20.9%
6 months to 1 year	112	68.7%
More than 2 years	17	10.4%

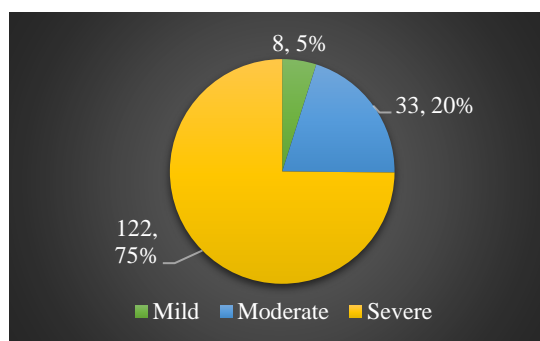


Figure 1: Baseline severity status

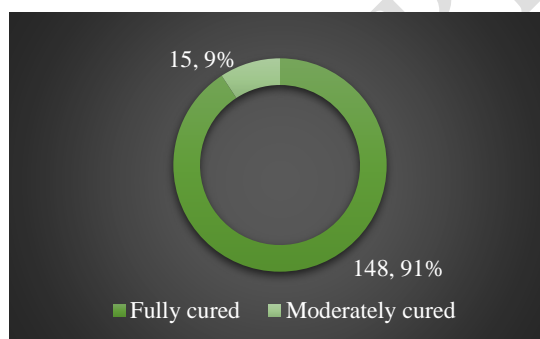


Figure 2: Outcome distribution

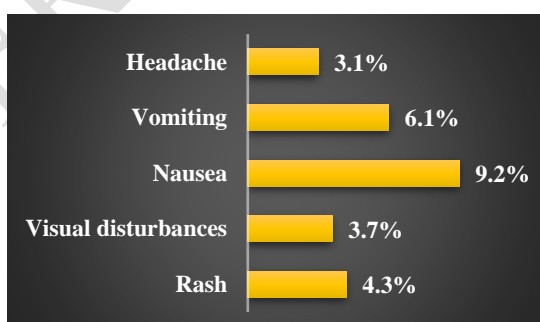


Figure 3: Distribution of side effects

DISCUSSION

In this study, the majority of participants were 35 years or younger, followed by 35.0% aged between 35 and 50 years, and 11.7% between 50 and 65 years. Females constituted a significant majority, making up 63.2% of the participants, indicating a younger cohort with a higher proportion of females. This demographic distribution was similar to a recent study conducted in Bangladesh [11]. However, contrasting results were found in another study from Pakistan [2], which observed a male predominance. Regarding family history, 19.0% of participants reported having a familial connection, while 81.0% had no family history. In your study, the prevalence of family history

was similar to findings from another study by Islam et al. [12]. Regarding infection sites, Tinea cruris was the most common at 39.9%, followed by Tinea corporis at 20.9%, Tinea magnum at 16.0%, Tinea pedis at 12.9%, and Tinea versicolor at 10.4%. Kafi et al. [11] also reported a similar trend in tinea infections among their participants. In terms of lesion duration, 68.7% of the lesions lasted between 6 months to 1 year, 20.9% lasted less than 6 months, and 10.4% were present for more than 2 years, aligning with the findings of Islam et al. [12]. Baseline severity assessment showed that a significant majority of patients were classified as having severe conditions. In the outcome analysis of your study, most participants were fully cured, with only 9% showing moderate improvements. Side effects of voriconazole, such as rash, visual disturbances, nausea, vomiting, and headache, were noted in some cases, aligning with previous studies [11,12]. Chandrashekar BS et al. reported a 75% efficacy rate for oral voriconazole in treating recurrent and resistant cases [13], while Khondker L found it to be 67.9% effective in a clinical trial involving 81 treatment failure cases of dermatophytosis [14]. Hoq AJMS et al. demonstrated an 88% efficacy for oral voriconazole in treating relapsing and resistant dermatophyte infections [15]. This is particularly relevant today as many patients are not responding to traditional antifungal drugs like terbinafine, fluconazole, and itraconazole [16]. Assessing the efficacy of voriconazole positions it as a promising treatment option for new, resistant, and relapsing dermatophytosis cases.

CONCLUSION & RECOMMENDATION

voriconazole emerges as a promising and effective treatment for dermatophyte infections. As a newer antifungal agent, it offers a safe alternative that can potentially reduce the risk of treatment failure associated with drug resistance. This highlights voriconazole's value in clinical practice, offering dermatologists a robust option to manage challenging cases of dermatophyte infections more effectively. Further studies and clinical observations will continue to delineate its role and optimize its use in diverse patient populations.

Disclaimer (Artificial intelligence)

No generative AI technologies were used in writing or editing this manuscript.

References

- [1] Bitew, Adane. "Dermatophytosis: Prevalence of dermatophytes and non-dermatophyte fungi from patients attending Arsho Advanced Medical Laboratory, Addis Ababa, Ethiopia." *Dermatology research and practice* 2018.1 (2018): 8164757.
- [2] Shahzad, Muhammad Khurram, et al. "Efficacy of oral voriconazole in treating dermatophyte infections (Tinea Corporis and Cruris)." *Pakistan Journal of Medical & Health Sciences* 16.02 (2022): 330-330.
- [3] Kruithoff, C.; Gamal, A.; McCormick, T.S.; Ghannoum, M.A. Dermatophyte Infections Worldwide: Increase in Incidence and Associated Antifungal Resistance. *Life* 2024, 14, 1. <https://doi.org/10.3390/life14010001>.
- [4] Nehru, Banoth Sai, and Banoth Ganesh. "Advancements in Dermatophyte Classification, Clinical Diagnosis and Treatment."
- [5] Delliere, Sarah & Jabet, Arnaud & Abdolrasouli, Alireza. (2024). Current and emerging issues in dermatophyte infections. *PLOS Pathogens*. 20. 10.1371/journal.ppat.1012258.
- [6] Gupta, Chhavi, et al. "Review on host-pathogen interaction in dermatophyte infections." *Journal of Medical Mycology* 33.1 (2023): 101331.
- [7] Chowdhary, Anuradha, et al. "Efficacy of Voriconazole in Dermatophyte Infections: A Review." *Journal of Medical Mycology*, vol. 25, no. 4, 2023.
- [8] Naik, Bharati, et al. "Fungal coexistence in the skin mycobiome: a study involving Malassezia, Candida, and Rhodotorula." *AMB Express* vol. 14,1 26. 20 Feb. 2024, doi:10.1186/s13568-024-01674-8.
- [9] Durdu, Murat, et al. "Topical and systemic antifungals in dermatology practice." *Expert review of clinical pharmacology* 10.2 (2017): 225-237.

- [10] Gnat, Sebastian, D. Łagowski, and Aneta Nowakiewicz. "Major challenges and perspectives in the diagnostics and treatment of dermatophyte infections." *Journal of Applied Microbiology* 129.2 (2020): 212-232.
- [11] Kafi, Md Abdulla-Hel, et al. "Efficacy and safety of voriconazole in the treatment of resistant cases of dermatophytosis." *J ZHSWMC* 2.1 (2020): 3-6.
- [12] Islam, Rafiqul, Islam Nazrul, and Mohammed Mosharrif Hossain. "Efficacy and safety of Voriconazole in patients with dermatophytes." (2021): 20210111787.
- [13] Chandrashekar BS, Poojitha DS. Evaluation of efficacy and safety of oral voriconazole in the management of recalcitrant and recurrent dermatophytosis. *ClinExpDermatol.* 2021 Jun 11. doi: 10.1111/ced.14799. Epub ahead of print. PMID: 34115896.
- [14] Khondker L. "Efficacy and safety of voriconazole in the treatment failure cases of Dermatophytosis". *The Gulf Journal of Dermatology and Venereology.* 2020; 27 (2): 24-30.
- [15] Hoq AJMS, Sultana F, MJ Abedin, GM Matiur Rahman. "Efficacy of Voriconazole among 500 Dermatophytes Patients: A Study in a Tertiary Care Hospital, Cumilla, Bangladesh". *American Journal of Dermatology and Venereology.*2020; 9(2): 17-20.
- [16] Suleri ZS. "Recurrent tinea corporis and cruris: Antifungal resistance or poor compliance?". *Journal of Pakistan Association of Dermatologists.*2020; 30(1):1-2.

UNDER PEER REVIEW