

Comparison of profile attractiveness after compensatory filler in different regions of the face in individuals with chin deficiency

ABSTRACT

Objective: The present study aimed to evaluate and compare the profile attractiveness after compensatory filler in different regions of the face of individuals with chin deficiency. **Material and Methods:** The sample consisted of 24 patients with chin deficiency treated compensatorily with facial fillers. The patients were divided into 3 groups: Group C- Chin: 11 patients (1 man, 10 women), with a mean age of 31.27 years (s.d.=9.72), who received chin filler with iPRF. Group CN- Chin and Nose: 9 patients (2 men, 7 women), with a mean age of 32.33 years (s.d.=8.17), who, in addition to filler the chin with iPRF, also received rhinomodeling. Group CNL- Chin, Nose and Lips: 4 patients (4 women), with a mean age of 29.00 years (s.d.=4.24), who received, in addition to filler the chin with iPRF and rhinoplasty, filler of the lips with iPRF. The attractiveness of the profile before and after the filler was evaluated in profile photographs with scores from 1 to 10, with 1 being less attractive and 10 the most attractive. The evaluation was performed by 82 individuals, 45 specialists in Orthodontics or Orofacial Harmonization (27 female, 18 male, mean age 39.11 years, s.d.=9.06) and 37 laypeople (27 female, 10 male, mean age of 39.88 years, s.d.=15.97). The comparison between groups C, CN and CNL was performed by the one-way ANOVA and Tukey tests and for the comparison between specialists and laypeople, the independent t-test was used. **Results:** There was a statistically significant difference in the profile attractiveness among the different types of compensatory facial filler. After filler, the CNL group became the most attractive, followed by the CN group and lastly and the least attractive was the profile of the C group. The amount of improvement with the compensatory filler was greater in the CNL group, followed by the CN group and lesser in the C group. In the evaluation performed by laypeople, the improvement and attractiveness of the profile after filler were significantly greater than in the specialists' assessment. **Conclusion:** The filler of the chin, nose and lips resulted in a greater attractiveness of the facial profile, followed by the filler of the chin and nose, and lastly, the filler of the chin only.

Keywords: *Class II malocclusion. Face. Dermal Fillers. Facial filling. Chin. Lips. Nose.*

1. INTRODUCTION

For a long time, diagnosis in Orthodontics was guided mainly by occlusion and cephalometry, which were considered the guides for the treatment plan, and this often compromised balance and facial aesthetics [1-6].

Nowadays, patients are much more concerned with aesthetics, and the main complaint in Class II patients has been in relation to the deficiency of the facial profile [7]. Several authors agree that facial analysis is paramount over all other diagnostic data, and that the treatment plan should seek better functional and aesthetic results [8-14].

Several studies have sought to determine the facial features responsible for a more pleasing aesthetic appearance, and have observed that the components associated with the ideal profile are mainly the mouth and chin and that the convexity of the profile compromises facial pleasantness [7, 10, 13, 15, 16].

Individuals with mandibular deficiency present the most aesthetically significant skin changes. The greatest changes observed, in the vast majority of cases, are in the lower lip, mentolabial sulcus and chin [10, 17].

The main complaints of patients are in relation to the lower third of the face: increased facial convexity, mandibular deficiency and decreased chin-neck line [10, 17].

To eliminate unrealistic expectations regarding the results of compensatory orthodontic treatments, where occlusion correction is observed but integumentary deficiencies remain, leaving an unpleasant profile [3, 4, 6, 18], some authors have suggested an approach with other compensatory therapies to complement orthodontic treatment [19-24].

The popularization of Orofacial Harmonization in Dentistry has made this compensatory improvement of skeletal and integumentary problems more frequent and possible.

Chin augmentation, lip augmentation and rhinoplasty with fillers are the most sought-after procedures by patients, as they provide improvements to the facial profile in several aspects. These procedures can be performed separately or together. They make the profile more harmonious and positively influence facial aesthetics, increasing the balance between tissues and making the face more attractive [25].

There are currently no studies in the literature that compare the improvement in the attractiveness of the facial profile when the procedures are performed only on the chin, when they involve the chin and nose, and when they include the chin, nose, and lips. Therefore, the present study aimed to evaluate and compare the improvement in the attractiveness of the facial profile of patients with chin deficiency after compensatory facial filling in different regions of the face.

2. MATERIAL AND METHODS

This cross-sectional study was approved by the Human Research Ethics Committee of the Ingá University Center, UNINGÁ, Maringá, Brazil (protocol CAAE 13664719.8.0000.5220) and all patients signed an informed consent form

to participate in the study.

The sample size calculation was based on a significance level of alpha of 5% (0.05) and a beta of 20% (0.20) to achieve a test power of 80% to detect a minimum difference of 1.2 with a mean standard deviation of 1.79 for the attractiveness of the profile evaluated in photographs, in a previous study [26]. Thus, the sample size calculation resulted in the need for at least 36 evaluators in each group.

The sample consisted of photographic images of the profiles of 24 leucoderma patients treated at the Intelligent Education School, located in the Uningá Campus in Londrina, PR, Brazil. The patients selected for the sample were patients over 18 years of age with chin deficiencies who had previously been treated with facial fillers as a compensatory measure in different regions of the face. Patients who did not have standardized photographs were excluded from the sample. The soft tissue facial convexity angle was used to assess chin deficiency, and measurements were taken from facial profile photographs prior to filling. The soft tissue facial convexity angle is determined by the soft nasion (N'), soft subnasale (Sn') and soft pogonion (Pg') points [27]. A mean normal angle has a value of 165° (ranging from 164° to 167°) [27]. Angles less than 164° indicate a chin deficiency, or mandibular retrognathia. For inclusion in the sample, all patients had to have a soft tissue facial convexity angle in the initial photograph of less than 160°.

The sample was divided into 3 groups:

Chin Group (C): 11 patients (1 man, 10 women), with a mean age of 31.27 years (s.d.=9.72), who received chin filling with iPRF (Figure 1).

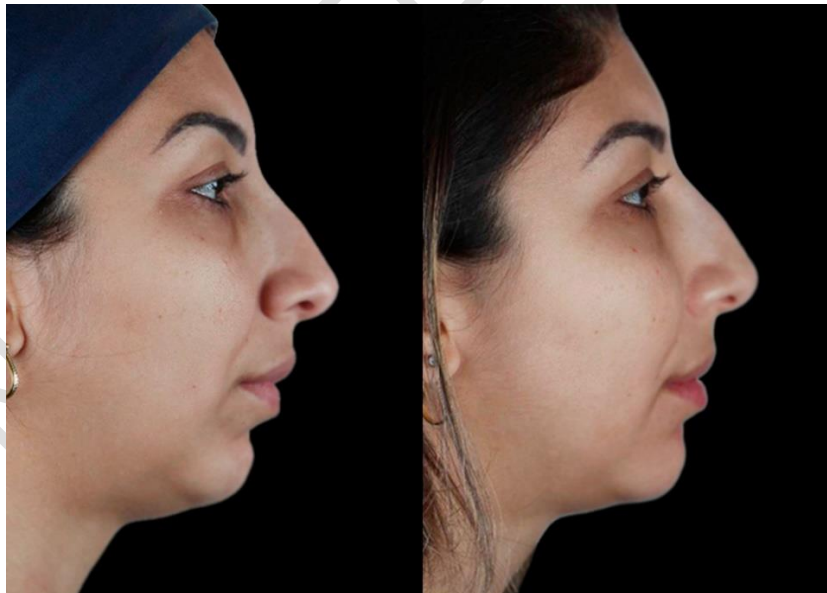

Figure 1- Left side, photo of the patient before filling. Right side, photo of the patient immediately after filling in the chin region.

Chin and Nose Group (CN): 9 patients (2 men, 7 women), with a mean age of 32.33 years (s.d.=8.17), who received filling in the chin and nose with IPRF (Figure 2).

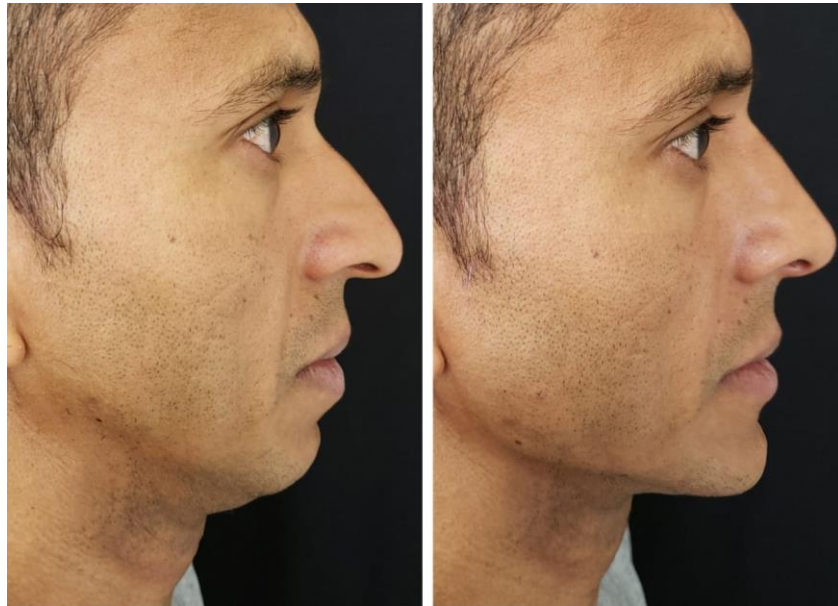

Figure 2- Left side, photo of the patient before filling. Right side, photo of the patient immediately after filling in the chin and nose region.

Chin, Nose and Lips Group (CNL): 4 patients (4 women), with a mean age of 29.00 years (s.d.=4.24), who received IPRF filling in the three regions that make up the facial profile, chin, nose and lips (Figure 3).

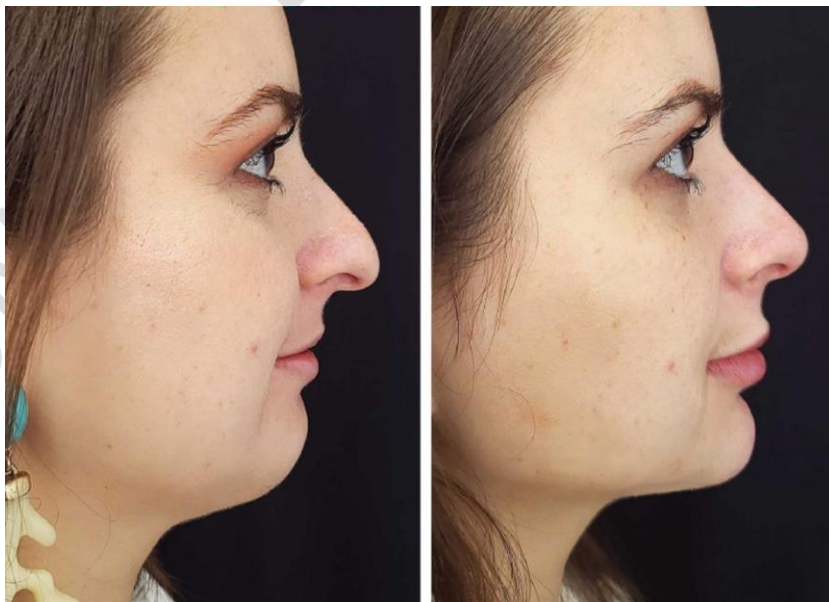

Figure 3 - Left side, photo of the patient before filling. Right side, photo of the patient immediately after filling in the chin, nose and lip region.

The fillings, in all patients, were performed by a single Orofacial Harmonization (RF) specialist trained in performing these procedures.

The protocol for obtaining the i-PRF (Platelet Rich Fibrin) used in the sample fillings was performed immediately before the compensatory procedure. The patients had a blood sample (18 ml) collected by venipuncture. The blood was immediately centrifuged once, to obtain the Platelet Rich Fibrin. The collection was performed in a white-top tube, without the addition of any anticoagulant, and centrifuged according to the Choukroun protocol [28], at 3000 rpm for 10 minutes in the Kasvi centrifuge (Kasvi, São José dos Pinhais, PR, Brazil).

After centrifugation, the tubes were carefully removed from the centrifuge and the i-PRF was transferred to sterile 1 ml syringes (Descarpack, São Paulo, SP, Brazil). This isolated product, i-PRF, was the filler used in all patients in the sample to compensate for profile deformities.

Before injecting the filler, aspiration was performed to avoid any arterial obstruction. There were no complications during the procedures performed on the patients in the sample. The chin was filled at specific points [29]. The technique was performed with a 27G needle, in a supraperiosteal plane, as described by Braz et al. [29]. At the lowest point of the chin and in the labial sulcus, 0.3 ml of fibrin was injected, and between the labial sulcus and the lowest point of the chin, 0.2 ml was injected at two points lateral to the midline, totaling a final volume of 1 ml of filler (Figure 4).

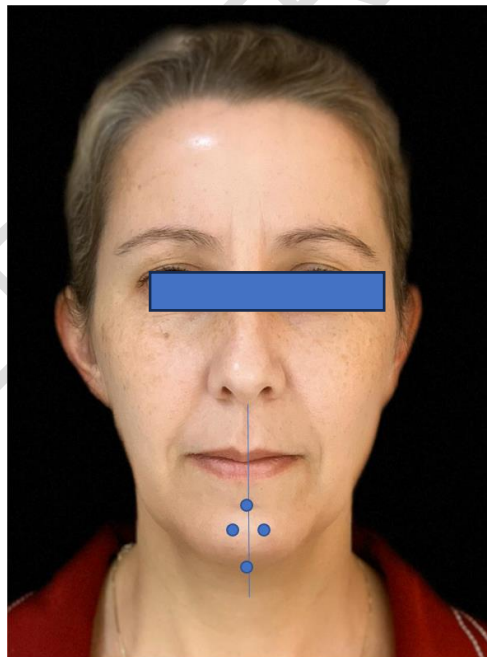

Figure 4- Points that received filling on the chin.

In the nose, the regions that received the filler were the tip, the root, the columella and the nasal septum. The technique was performed with a 27G needle, in small boluses, located in two regions of 0.05 ml supra tip, 0.3 ml in the region of the anterior nasal spine, just bone, two boluses of 0.2 ml in the nasal

root, in a subcutaneous plane and a retroinjection of 0.1 ml in the columella, totaling a final volume of 0.9 ml, always taking care to aspirate before injecting the filler, in order to avoid any vascular complications (Figure 5).

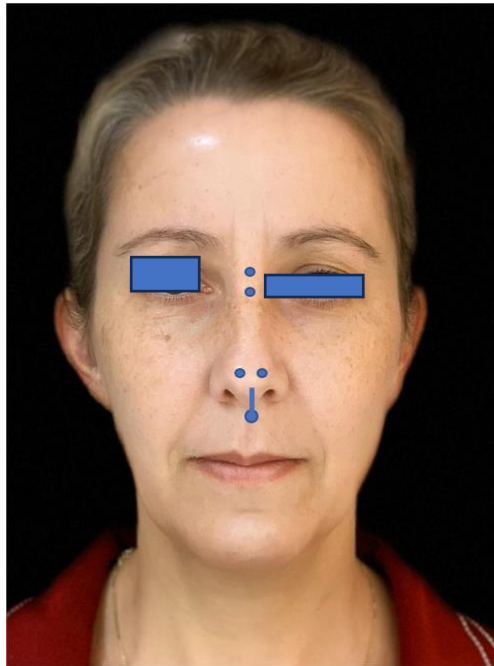

Figure 5- Points that received filling on the nose.

The patients in the sample who received lip fillers had their proportions reestablished through the injection of platelet-rich fibrin into the region of the labial philtrum, using the retroinjection technique, with 0.1 ml in each philtrum and, in the upper and lower lips, 4 boluses, injected into the region of the tubercles, with 0.2 ml in each tubercle, totaling 1 ml of filler in the region comprising the lip [29] (Figure 6).

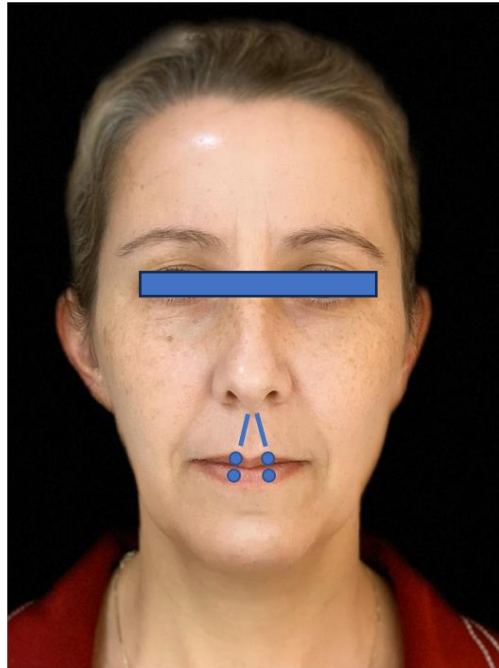


Figure 6- Points that received lip filling.

Patients were photographed before and immediately after filling, always by the same operator. The camera used to take the photographs was a Canon Rebel T5i (Canon, Tokyo, Japan) with a 100mm macro focal lens (Canon, Tokyo, Japan) and a Godox TT 560II speedlight flash. The photographs were taken from a lateral perspective, with the patient standing, looking at the horizon, with a mirror in front of him/her with his/her natural head position and a true vertical line. The distance between the camera and the face was 1.5 m in all the photos, which did not need to be cropped to assess the changes in the profile before and after the procedure.

The photos were arranged side by side, before being the left side, and after, the right side.

A questionnaire was created using Google Forms, with 24 before and after images of the treated patients, where the evaluators were asked to assign scores from 1 to 10 for the facial profiles before and after the procedure. The evaluators could look at the photos for as long as they needed and go back and change the scores if they wished.

The evaluators were not identified by name, however, they recorded information about age, gender and professional training.

The questionnaire link was sent via WhatsApp to several groups containing dentists specializing in Orthodontics and/or Orofacial Harmonization and laypeople.

In total, 82 evaluators responded to the survey, 54 women and 28 men. The attractiveness scores were compared between specialists and laypeople not linked to the dental field, in addition to the comparison between the C, CN and CNL groups.

The group of specialist evaluators was composed of 45 dentists specialized in Orthodontics and/or Orofacial Harmonization, 27 women and 18 men, with an average age of 39.11 years (s.d.=9.06).

The group of lay evaluators was composed of 37 individuals, 27 women and 10 men, with an average age of 39.88 years (s.d.=15.97).

2.1. Error study

To verify the reliability of the results, after 1 month, 15 randomly selected evaluators were asked to re-evaluate the attractiveness of the facial profiles. The scores obtained in the first and second evaluations were subjected to the Kappa concordance test. The results demonstrated a coefficient of 0.86, indicating an almost perfect strength of agreement [30].

2.2. Statistical analysis

The normality of the data was verified by the Shapiro-Wilk test.

The comparability of the groups with different types of fillers and of expert and lay evaluators in relation to age and gender distribution was performed by the independent t-test and chi-square test, respectively.

The comparison of the attractiveness of the profile between the groups with different types of compensatory facial fillers (C, CN and CNL) before and after and of the changes with the procedures was performed by the one-way ANOVA and Tukey tests. The intragroup comparison before and after the procedure was performed by the dependent t-test.

The comparison between the groups of expert and lay evaluators was performed by the independent t-test.

The tests were performed with the aid of the Statistica for Windows software (version 10.0, Statsoft, Tulsa, Oklahoma, USA) and the data were considered significant for $P < 0.05$.

3. RESULTS

There was comparability of age and gender distribution between groups C, CN and CNL (Table 1) and between expert and lay evaluators (Table 2).

There was a significant improvement in profile attractiveness after compensatory facial filling in all groups evaluated (Table 3). There was a statistically significant difference in profile attractiveness between the different regions of compensatory facial filling (Table 3). Before the procedure (T1), group CNL had a less attractive profile, followed by group CN and group C. After filling (T2), group CNL became the most attractive, followed by group CN and last and least attractive was the profile of group C. The amount of improvement with compensatory filling (T2-T1) was smaller in group C, followed by group CN and greater in group CNL (Table 3).

The improvement in profile attractiveness was statistically significant after facial filling (Table 4). In the evaluation before (T1) the procedure, laypeople gave a lower score of attractiveness of the facial profile than the experts, and in the evaluation after the filling (T2), the experts were more critical than laypeople, giving a lower score of attractiveness of the facial profile (Table 4). In the evaluation made by laypeople, the improvement in the attractiveness of the profile was significantly greater than in the evaluation made by experts (Table 4).

Table 1. Comparison of age and gender distribution between groups C, CN and CNL.

Variables	C (n=11)	CN (n=9)	CNL (n=4)	P
	Mean (SD)	Mean (SD)	Mean (SD)	
Age	31.27 (9.72)	32.33 (8.17)	29.00 (4.24)	0.811 [†]
Gender				X ² = 1.46
Males	1	2	0	DF = 2
Females	10	7	4	p = 0.480* ^α

[†] independent t test ^α chi-square

Table 2. Comparison of age and gender distribution between specialists and laypeople.

Variables	Specialists (N=45)	Laypeople (N=37)	P
	Mean (SD)	Mean (SD)	
Age	39.11 (9.06)	39.88 (15.97)	0.784 [†]
Gender			X ² = 1.51
Males	18	10	DF = 1
Females	27	27	p = 0.217* ^α

[†] independent t test ^α chi-square

Table 3. Results of the comparison between groups with compensatory facial filling in (C, CN and CNL) before, after and improvement with the procedures (one-way ANOVA and Tukey test) and intragroup comparison before and after the procedure (dependent t-test).

Facial profile attractiveness	C (n=902)		CN (n=738)		CNL (n=328)		P
	Mean	SD	Mean	SD	Mean	SD	
Before (T1)	3.89 ^A	1.88	3.48 ^B	1.87	3.02 ^C	1.76	0.000* £
After (T2)	7.08 ^A	2.06	8.11 ^B	1.64	8.29 ^C	1.55	0.000* £
P	0.000* ¥		0.000* ¥		0.000* ¥		
Changes (T2-T1)	3.19 ^A	2.47	4.63 ^B	2.46	5.27 ^C	2.45	0.000* £

* Statistically significant at P<0.05

£ one-way ANOVA

¥ dependent t test

Different letters in the same row indicate the presence of a statistically significant difference between the groups, determined by the Tukey test.

Table 4. Results of the comparison of profile attractiveness (before, after, and change with compensatory filling) between experts and laypeople (independent t-test) and of the intragroup comparison before and after filling (dependent t-test).

Facial profile attractiveness	Specialists		Laypeople		P
	Mean	SD	Mean	SD	
Before (T1)	3.75	1.93	3.41	1.80	0.000* £
After (T2)	7.14	1.88	8.31	1.73	0.000* £
P	0.000* ¥		0.000* ¥		
Changes (T2-T1)	3.39	2.51	4.90	2.46	0.000* £

* Statistically significant at $P < 0.05$

£ independent t test

¥ dependent t test

4. DISCUSSION

Regarding the sample of this research, patients who sought treatment to improve their facial profile were selected. The complaints they reported were related to morphological deficiencies observed in patients with chin deficiency, lip projection, mentolabial sulcus, profile convexity and reduced chin-neck line [10, 31].

Janson et al. [32] reported that malocclusions such as Class II directly alter the facial profile of the patients involved and the correct diagnosis of these malocclusions added to the advances that have emerged over time in Dentistry serve as a basis to this day for orthodontic treatment and also for new procedures including facial harmonization.

Orthodontics alone does not always present changes in soft tissue that lead to current aesthetic demands, therefore, Orofacial Harmonization can contribute very positively, working together with other specialties to achieve results that would not be possible, in a minimally invasive way. Patients with chin deficiency could have been treated orthodontically, however, the sample consisted of patients who had already received the compensatory procedure performed to address the patient's aesthetic complaint, which possibly would not be possible with orthodontics alone.

The mean age and compatibility of the distribution of genders between the groups were taken into consideration so that there would be no difference in the assessment of attractiveness, since younger patients could respond better with less treatment, in addition to generally presenting greater attractiveness [33]. Likewise, in relation to gender, treatment in men or women could have different results since they have different needs in relation to the morphology, beauty and attractiveness of the face [34].

Care was also taken to check the compatibility between the evaluators of the work so that there would be no divergence in relation to the perception of beauty due to differences in the evaluators due to age and/or gender [35].

The majority of the cases in the sample were female patients, an aspect that we observe daily in the dental clinic. Concern for facial beauty and attractiveness seems to be something that women take much more into consideration than men [36].

The groups were also compatible in terms of age. The average age of the cases evaluated was 29 to 32 years. This rules out any possibility of interference that we would have if there were a comparison between the profile of a younger patient with that of an older patient, since the older patient presents more relevant aspects in relation to facial aging, with greater ptosis and imbalance between the facial thirds [34, 37-39], which could influence the results.

The differences between the groups evaluated, therefore, did not present significant differences that could influence the attractiveness rating of the profile. The distribution between the groups in relation to the age and gender of the treated patients was quite homogeneous.

The method chosen to evaluate the attractiveness of the profile was lateral photographs [34], with the patient in a natural head position [40-42], before and after the filler procedure. In the lateral view, the balance between the thirds and the convexity of the face is better observed. Observing such delicate curves, which are influenced by the shape of the nose, the thickness of the upper and lower lip and also the contour of the mandibular groove, is something that requires details that our eyes can see. Silhouette analyses, commonly used in profile assessment [43], do not allow for the assessment of such delicate curves as we can observe in photographs [26, 44]. Furthermore, it has previously been proven that there are no differences between assessments of facial profile attractiveness performed with silhouettes and with profile photographs [26].

The evaluation of photographs before and after the filling procedure was the methodology used in the study because it allows for a detailed assessment of the characteristics of the soft tissues. It is easier to perceive changes in the deepening of the grooves and the volumization of the treated regions through lateral photographs [34, 37], especially in this case, where we had lay evaluators, who do not have the perception of details that professionals in the field have to assess the profile of the face in a veiled image, without details. The arrangement of the photographs side by side also makes it easier to observe how much the profile improved or worsened after the procedure.

From the results found among the sample groups with compensatory facial filling in different regions of the face (C, CN and CNL) before and after the filling procedures, initially the CNL group was evaluated with a lower attractiveness score, followed by the CN group and then the chin group (Table 3). Likewise, after the filling, the group that had the best averages for profile attractiveness were the CNL groups, followed by the CN group and, finally, the group that only received treatment on the chin (Table 3).

All patients in the sample, in the three groups, received higher scores for profile attractiveness after the filling performed [37], both by the expert evaluators and by the lay evaluators (Table 4). The improvement in profiles after treatment with fillers was unanimous, proving what is said in many studies that say that the perception of beauty is something natural and independent of experience on the subject [35, 45-49].

Pacteau [46] also says that there are 7 key features on an individual's face

that, in milliseconds, through scanning the observer's eyes, the brain subconsciously processes facial beauty. He also says that of these 7 points, 4 of them, we, professionals who work with facial fillers and botulinum toxin, can modify the shape of the face, eyebrows, nose and mouth. This shows the importance of using filler techniques to meet the aesthetic complaints of our patients regarding the attractiveness and beauty of the face [46, 47]. Since 2003, researchers have collaborated to globally understand how to restructure a face and increase attractiveness by understanding facial volumes [50, 51]. Restoring harmony, symmetry, and balance by observing volumes and modifying contours yields natural results and avoids excessive filling [34, 51].

In recent years, researchers have been studying the face from various perspectives, with very careful approaches, observing the interrelationship between each tissue (bone, muscle, fat, and skin) and facial morphology. They also analyze how these structures, alone or together, can interfere with beauty and attractiveness. They relate bone and subcutaneous tissue atrophy to premature facial aging [34, 51]. Wrinkles appear and tissues shift, compromising facial contours due to a lack of bone, subcutaneous, and cutaneous volumes [51].

It is recommended that when planning treatment, the professional should have a dual view of the situation of the face that will be treated. First, they should be able to identify where support or volume is lacking and then they should be able to have a view of the treated face before it receives the treatment [34]. Instituting facial filler treatment in the wrong tissue will generate an unnatural result. To correct facial morphological deficiencies, three-dimensional treatments are suggested, with specific facial fillers for each facial plane that appears to lack adequate volume [33].

The demand for non-surgical facial aesthetic procedures that improve attractiveness and require little time away from routine activities has been increasing every day [34]. Advances in technology and the development of safe filler materials that allow for the modification of facial contours, providing natural results [34, 52], have made it possible to achieve optimal results in patients with skeletal impairment who would otherwise require orthognathic surgery and have expanded the possibilities of aesthetic results not only in surgical patients, but in the entire population [51, 52].

Fitzgerald, Carqueville and Yang [51] wrote a very enlightening paper on how we can work with fillers in different facial types, treating the regions of anatomical deficiencies, or due to genetic patterns, as in the case of patients with chin deficiency, or due to the loss of facial harmony related to tissue atrophy resulting from aging and improving the balance of the face, increasing attractiveness and reducing signs of aging. The authors mention that the lack of support in the structure of the face leads to changes in the entire morphology and the underlying tissues, without adequate bone support, undergo ptosis and express greater changes in the soft tissues, such as a deeper nasolabial fold, a longer upper lip, a deep mental groove, affecting the entire balance of the lower third and facial convexity. In short, the lack of bone volume contributes to all these changes that are the complaints of our patients in our daily lives [51].

Regenerative technology with iPRF, rich in growth factors, is a very versatile option with incredible therapeutic potential for use in facial volumizing procedures. A 100% autologous biomaterial, used without any type of adverse

reaction or allergic reactions and that allows to achieve three-dimensional results in the restructuring of the face [53, 54], achieving the desired volumization and with natural results [55, 56]. Filling with autologous material provides immediate volumization of the tissues in addition to improving the quality of the skin and the contours of the face. The only limitation of this filler that we chose for the sample is the fact that it does not maintain the volume of the material injected into the tissues [57], a fact that we already knew and, in fact, the choice for this material was to have a prediction of the final result (mockup) before choosing a more durable filler material and to take advantage of the therapeutic properties in relation to the improvement of the dermal quality that IPRF offers through the increase in the proliferation of fibroblasts and deposition of extracellular matrix [54].

Facial filling has been gaining ground and acting as a great adjuvant in obtaining the aesthetic results that patients seek [34, 52]. Several studies show how these changes in image improve the quality of life and contribute to the psychological well-being and general health of individuals and their families [33, 58].

Several studies show that facial attractiveness is greatly influenced by the nose, lips and chin [59, 60]. This was proven by the results of the present study. The cases in which imperfections in the chin, nose and lips were corrected were considered the most attractive (Table 3). Even when we treat these structures in isolation, we have an impact on the convexity of the face, which can be seen in the patient's profile. This was also demonstrated by the significant improvement in the facial profile of all groups evaluated (Table 3).

The lack of bone support in the nasal region, for example, generates changes in the philtrum, which becomes long, and in the upper lip, which loses volume and projection. Filling this region improves the convexity of the profile, since it modifies the nasolabial angle and, consequently, the upper lip. Maintaining the bone support of the nasal region is vital for the contour of the face and convexity of the profile, in addition to being extremely necessary to preserve the good positioning of the soft tissues of the middle and lower third of the face [51]. A small correction in the anatomy of the nose can make a big difference in appearance, both before and after filling [34, 61, 62]. Restoring the columns of the upper philtrum and Cupid's bow with fillers also improves the facial profile and attractiveness [34].

Finally, the chin, a structure that is the main deficiency in patients with mandibular retrusion and deficiency, plays a fundamental role in the harmony and beauty of the face, especially about facial profile. The three-dimensional aspect of projection, height and width of the chin makes surgical planning for this region difficult, since the surgical focus is only on the projection and length of the chin, unlike working with facial fillers, where the professional can correct the entire perioral region involved in the contour of the chin, for example, the marionette groove, pre- and post-jowl groove, in addition to altering the projection, width and height of the chin. When several dentoalveolar alterations are involved, it is suggested that orthognathic surgery is the best option. The advantage of treatments with facial fillers is the fact that it is possible to achieve a great non-surgical improvement in the facial profile, in a minimally invasive manner, with good cost-benefit, a postoperative period that does not interfere with daily

activities, minimal patient anxiety and is painless [34]. In the clinic, we come across patients who do not agree to undergo orthognathic surgery for various reasons. In the case of patients with chin deficiencies, improving the aesthetics of the chin with facial fillers is an alternative that has been very well accepted, including so that the patient has an idea of what it would be like if he or she underwent orthognathic surgery and can decide on it later [52].

5. CONCLUSION

Facial fillers promoted a significant improvement in facial profile attractiveness in all the different regions performed. However, filling the chin, nose and lips resulted in greater attractiveness of the facial profile, followed by filling the chin and nose, and lastly, filling the chin only.

ETHICAL APPROVAL

All authors hereby declare that all experiments have been examined and approved by the appropriate ethics committee and have therefore been performed in accordance with the ethics standards laid down in the 1964 Declaration of Helsinki.

Disclaimer (Artificial intelligence)

Authors hereby declare that NO generative AI technologies such as Large Language Models (ChatGPT, COPILOT, etc) and text-to-image generators have been used during writing or editing of manuscripts.

REFERENCES

- [1] Arnett GW, Bergman RT. Facial keys to orthodontic diagnosis and treatment planning--Part II. *Am J Orthod Dentofacial Orthop.* 1993;103(5),395-411.
- [2] Arnett GW, Bergman RT. Facial keys to orthodontic diagnosis and treatment planning. Part I. *Am J Orthod Dentofacial Orthop.* 1993;103(4),299-312.
- [3] Talass MF, Talass L, Baker RC. Soft-tissue profile changes resulting from retraction of maxillary incisors. *Am J Orthod Dentofacial Orthop.* 1987;91(5),385-94.
- [4] Holdaway RA. A soft-tissue cephalometric analysis and its use in orthodontic treatment planning. Part I. *Am J Orthod.* 1983;84(1),1-28.
- [5] Worms FW, Speidel TM, Bevis RR, Waite DE. Posttreatment stability and esthetics of orthognathic surgery. *Angle Orthod.* 1980;50(4),251-73.
- [6] Downs WB. Analysis of the dentofacial profile. *Angle Orthod.* 1956;26,191-212.
- [7] Viegas MM, Pereira PM, Proença L. Assessment of the aesthetic perception of the facial profile in different panels of observers. *Rev Port Estomatol Med Dent Cir Maxilofac.* 2016;57(4),252-7.
- [8] Brandão JRMCB. Evaluation of chin prominence in the aesthetic perception of patients, orthodontists and surgeons. Aracajú: Universidade Federal de Sergipe; 2017.
- [9] Czarnecki ST, Nanda RS, Currier GF. Perceptions of a balanced facial profile. *Am J Orthod Dentofacial Orthop.* 1993;104(2),180-7.
- [10] Capelozza Filho L. Diagnóstico em ortodontia. Maringá: Editora Dental Press; 2004.
- [11] Pithon MM, Nascimento CC, Barbosa GC, Coqueiro Rda S. Do dental esthetics have any influence on finding a job? *Am J Orthod Dentofacial Orthop.* 2014;146(4),423-9.
- [12] Caldas LD. Aesthetic perception of the stoma-mentous dimension for facial harmony. Aracajú: Federal University of Sergipe; 2014.
- [13] Reis SAB, Abrão J, Claro CAdA, Capelozza Filho L. Evaluation of the determinants of facial profile aesthetics. *Dental Press J Orthod.* 2011;16(1),57-67.
- [14] Macedo A, Moro A, Scavone Jr H, Martins LF. A análise facial no diagnóstico e planejamento ortodôntico. *Ortodontia SPO.* 2008;41(2),148-53.
- [15] Khosravanifard B, Rakhshan V, Raeesi E. Factors influencing attractiveness of soft tissue profile. *Oral Surg Oral Med Oral Pathol Oral Radiol.* 2013;115(1),29-37.
- [16] Naini FB, Donaldson AN, McDonald F, Cobourne MT. Assessing the influence of lower facial profile convexity on perceived attractiveness in the orthognathic patient, clinician, and layperson. *Oral Surg Oral Med Oral Pathol Oral Radiol.* 2012;114(3),303-11.
- [17] Reis SAB, Abrão J, Capelozza Filho L, Claro CAdA. Numeric facial analysis of the profile in Pattern I Brazilians. *R Dental Press Ortodon Ortop Maxilar.* 2006;11(6),24-34.
- [18] Steiner CC. Cephalometrics for you and me. *Am J Orthod.* 1953;39(10),729-55.
- [19] Lee LH, Jun JH, Danganan M *et al.* Orthognathic surgery for the Asian patient

and the influence of the surgeon's background on treatment. *Int J Oral Maxillofac Surg.* 2011;40(5),458-63.

[20] Seo KK. Chap. 17 nose. In: Carruthers J, Carruthers A, editors. *Soft Tissue Augmentation*. Philadelphia: Elsevier; 2012. p. 112-22.

[21] Lee SK, Kim HS. Recent trend in the choice of fillers and injection techniques in Asia: a questionnaire study based on expert opinion. *J Drugs Dermatol.* 2014;13(1),24-31.

[22] Tanaka Y. Oriental nose occidentalization and perinasal shaping by augmentation of the underdeveloped anterior nasal spine. *Plast Reconstr Surg Glob Open.* 2014;2(8),e197.

[23] Wang JH, Jang YJ, Park SK, Lee BJ. Measurement of aesthetic proportions in the profile view of Koreans. *Ann Plast Surg.* 2009;62(2),109-13.

[24] Oh HS, Kang SY, Kim KY, Yang WY. Anthropometric analysis on facial profile alterations following augmentation rhinoplasty with nasal tip plasty. *J Korean Soc Aesthet Plast Surg* 2010;16,144-50.

[25] Ramos KAR. Perception of the aesthetic impact in the evaluation of changes in the macro and microaesthetics of the smile by dental surgeons, dental students and lay people. Lisbon: Portuguese Catholic University; 2013.

[26] Pithon MM, Silva IS, Almeida IO *et al.* Photos vs silhouettes for evaluation of profile esthetics between white and black evaluators. *Angle Orthod.* 2014;84(2),231-8.

[27] Godt A, Müller A, Kalwitzki M, Göz G. Angles of facial convexity in different skeletal Classes. *Eur J Orthod.* 2007;29(6),648-53.

[28] Choukroun J, Adda F, Schoeffler C, Vervelle A. Une opportunité en paro-implantologie: Le PRF. *Implantodontie.* 2001;42,55-62.

[29] Braz A, Humphrey S, Weinkle S *et al.* Lower Face: Clinical Anatomy and Regional Approaches with Injectable Fillers. *Plast Reconstr Surg.* 2015;136(5 Suppl),235S-57S.

[30] Landis JR, Koch GG. The measurement of observer agreement for categorical data. *Biometrics.* 1977;33(1),159-74.

[31] Brandão A. Avaliação da relação entre morfologia facial e oclusão em jovens brasileiros leucodermas, portadores de má oclusão classe II, divisão 1. *R Dental Press Ortodon Ortop Maxilar.* 1997;2(4),80-1.

[32] Janson G, Castello Branco N, Aliaga-Del Castillo A, Henriques JFC, de Morais JF. Soft tissue treatment changes with fixed functional appliances and with maxillary premolar extraction in Class II division 1 malocclusion patients. *Eur J Orthod.* 2018;40(2),214-22.

[33] Gassia V, Raspaldo H, Niforos FR, Michaud T. Global 3-dimensional approach to natural rejuvenation: recommendations for perioral, nose, and ear rejuvenation. *J Cosmet Dermatol.* 2013;12(2),123-36.

[34] Swift A, Remington K. BeautiPHication: a global approach to facial beauty. *Clin Plast Surg.* 2011;38(3),347-77, v.

[35] Jones D, Hill K. Criteria of facial attractiveness in five populations. *Hum Nat.* 1993;4(3),271-96.

[36] Teixeira SA. Production and social consumption of beauty. *Horiz Antropol.* 2001;7(16),189-220.

37] Magri IO, Maio M. Remodeling of the midface with fillers. *Rev Bras Cir Plást.* 2016;31(4),573-7.

[38] Raspaldo H, Gassia V, Niforos FR, Michaud T. Global, 3-dimensional approach to natural rejuvenation: part 1 - recommendations for volume restoration and the periocular area. *J Cosmet Dermatol.* 2012;11(4),279-89.

[39] Cohen SR, Womack H. Injectable Tissue Replacement and Regeneration: Anatomic Fat Grafting to Restore Decayed Facial Tissues. *Plast Reconstr Surg Glob Open.* 2019;7(8),e2293.

[40] Rino Neto J, Freire-Maia BA, Paiva JB. Method of recording the natural position of the head to obtain lateral cephalometric radiography: considerations and importance of the method in orthodontic-surgical diagnosis. *R Dental Press Ortodon Ortop Maxilar.* 2003;8(3),61-71.

[41] Dvortsin DP, Ye Q, Pruim GJ, Dijkstra PU, Ren Y. Reliability of the integrated radiograph-photograph method to obtain natural head position in cephalometric diagnosis. *Angle Orthod.* 2011;81(5),889-94.

[42] Solow B, Tallgren A. Natural head position in standing subjects. *Acta Odontol Scand.* 1971;29(5),591-607.

[43] Mendes LM, Janson G, Zingaretti Junqueira-Mendes CH, Garib DG. Long-term profile attractiveness in Class II Division 1 malocclusion patients treated with and without extractions. *Am J Orthod Dentofacial Orthop.* 2019;155(3),362-71.

[44] Barrer JG, Ghafari J. Silhouette profiles in the assessment of facial esthetics: a comparison of cases treated with various orthodontic appliances. *Am J Orthod.* 1985;87(5),385-91.

[45] Millard DR. *Principilization of plastic surgery.* Boston: Lippincott Williams & Wilkins; 1987.

[46] Pachteau F. *The symptom of beauty.* Cambridge: Harvard University Press; 1994.

[47] Klopfer PH. Sensory physiology and esthetics. *Am Sci.* 1970;58(4),399-403.

[48] Cunningham MR, Roberts AR, Barbee AP, Druen PB, Wu CH. Their ideas of beauty are, on the whole, the same as ours": Consistency and variability in the cross-cultural perception of female physical attractiveness. *J Pers Soc Psychol* 1995;68(2),261-79.

[49] Langlois JH, Roggman LA, Casey RJ *et al.* Infant preferences for attractive faces: Rudiments of a stereotype? *Dev Psychol.* 1987;23(3),363-9.

[50] Gierloff M, Stohring C, Buder T *et al.* Aging changes of the midfacial fat compartments: a computed tomographic study. *Plast Reconstr Surg.* 2012;129(1),263-73.

[51] Fitzgerald R, Carqueville J, Yang PT. An approach to structural facial rejuvenation with fillers in women. *Int J Womens Dermatol.* 2019;5(1),52-67.

[52] Corotti K. A Ortodontia e a harmonização orofacial. In: Barros TP, Ferrão Jr JP, editors. *Atualidades em harmonização orofacial.* Ribeirão Preto: Editora Tota; 2018. p. 13-30.

[53] Garcia C, Pino A, Jimenez N *et al.* In vitro characterization and clinical use of platelet-rich plasma-derived Endoret-Gel as an autologous treatment for atrophic scars. *J Cosmet Dermatol.* 2019;

- [54] Anitua E, Pino A, Troya M, Jaén P, Orive G. A novel personalized 3D injectable protein scaffold for regenerative medicine. *J Mater Sci Mater Med.* 2017;29(1),7.
- [55] Fedyakova E, Pino A, Kogan L *et al.* An autologous protein gel for soft tissue augmentation: in vitro characterization and clinical evaluation. *J Cosmet Dermatol.* 2019;18(3),762-72.
- [56] Jimenez Gomez N, Pino Castresana A, Segurado Miravalles G *et al.* Autologous platelet-rich gel for facial rejuvenation and wrinkle amelioration: A pilot study. *J Cosmet Dermatol.* 2018;18(5),1353-60.
- [57] Liu J, Qu W, Li R, Zheng C, Zhang L. Efficacy of autologous platelet- rich gel in the treatment of deep grade II burn wounds. *Int J Clin Exp Med.* 2018;11(3),2654-9.
- [58] Wise JB, Greco T. Injectable treatments for the aging face. *Facial Plast Surg.* 2006;22(2),140-6.
- [59] Almeida MD, Farias ACR, Bittencourt MAV. Influência do posicionamento sagital mandibular na estética facial. *Dental Press J Orthod.* 2010;15(2),87-96.
- [60] Sena LMF, Damasceno EALAL, Farias ACR, Pereira HSG. The influence of sagittal position of the mandible in facial attractiveness and social perception. *Dental Press J Orthod.* 2017;22(2),77-86.
- [61] Sheen J, Sheen A. *Aesthetic rhinoplasty.* 2nd ed. St Louis: Quality Medical Publishing; 1997.
- [62] Danieal RK. *Rhinoplasty, an atlas of surgical techniques.* . New York: Springer Science & Business; 2002.