

Original Research Article

Impact Assessment of Restraint Stress and Cadmium Chloride Administration on the Liver Function of Female Wistar Rats.

ABSTRACT

Cadmium (Cd) and prolonged exposure to stress are associated with adverse health outcomes. Various studies have shown the impacts of stress and metal exposures on liver function. Cd are non-redox metals, one of the important mechanisms underlying their toxicity is oxidative stress induction as a result of the generation of reactive species and/or depletion of the antioxidant defense system. Cadmium and psychological stressor are known to cause effects on liver individually. The study aimed to assess the impact of restraint stress and cadmium chloride administration on oxidative stress and liver functions in female Wistar rats. 24 female Wistar rats (180-220g) were randomly divided into 4 groups (n=5 each): Control (CTL), Restraint stress (RSS), Cadmium chloride (CCC), Restraint+Cadmium (RSC). Experimental groups were administered a daily dose of 100 mg/kg/BW of Cadmium chloride and subjected to restraint stress via wire mesh for 30 minutes daily for the period of 21 days. All rats were anaesthetized and sacrificed 24 hours after the last procedures. Blood was collected through cardiac puncture for biochemical analysis. Liver tissue were collected, a part homogenized and analyzed for biochemical assays and a part for histological analysis. Results showed that the weight gain difference and antioxidant enzymes decreased significantly ($p<0.05$) in RSC group when compared with the control. The findings also revealed that cadmium and restraint stress exposure induced hepatotoxicity with a significant difference in liver function markers. AST and ALT significantly increased ($p<0.05$) in RSC group when compared to RSS and CCC groups. Furthermore, ALP and TP showed significant increase ($p<0.05$) in RSC group when compared with other groups. The histological architecture of the livers was also distorted by restraint stress exposure and cadmium chloride administration. Overall, the findings established that both psychological and environmental stressors affect liver health, through different pathways.

KEYWORDS: *Liver, Cadmium chloride, Restraint stress, Antioxidant enzymes, Liver function.*

1. Introduction

Heavy metals contamination has emerged as a major global environmental concern owing to the growth in industrialization, urbanization and utilization of chemical compounds in various industries [1]. Several adverse effects are caused by its primary impacts on the hematological, hepatic, renal, and central

neurological systems [2]. Heavy metals, due to their biotoxicity, bioaccumulation and environmental persistence have been shown to have significant effect on the quality of life [3]. It is a hazardous environmental pollutant with no nutritional value, and has numerous detrimental impacts on the body [4]. Cadmium is dissipated in the environment through several anthropogenic processes, such as mining, smelting, Ni/Cd batteries, pigments, plastic stabilizers, and phosphate fertilizers and compost [5]. Like all other metals, cadmium (Cd) persists indefinitely in the environment because of its non-biodegradability [6]. Cadmium exposure can be through contaminated food or water, tobacco smoking or inhalation [7]. For example, smokers may absorb approximately 1 µg of Cd from 20 cigarettes. Chronic, low-dose Cd exposure has been associated with a range of health issues, including hepatic damage, renal toxicity, central and peripheral neurotoxicity, pulmonary disease, and skin conditions like hyperkeratosis and acanthosis [8]. Additionally, studies have shown that Cd toxicity stimulates the production of reactive oxygen species (ROS) and the induction of oxidative stress in different organs [8] [9]. Moreover, Cd exposure stimulates lipid-peroxidation-induced tissue damage [10].

Restraint stress is a method to induce neurological responses in an animal by restricting its free movement. Stress is a highly individualized response of an organism to external or internal challenges which the individual cannot control or can control with difficulty [11]. The stress response manifests itself in significant behavioural changes, physiological changes and biochemical changes [12]. In the acute stress, when the animals are exposed to short, single experience of stress, there are profound changes in stress responsiveness and behavior [13]. Chronic stress models are in the form of repeated exposure on a daily basis. The use of laboratory animals has been instrumental in investigating the consequences of chronic stress. The adaptive response to stress is essentially a neuroendocrine reaction mediated via the hypothalamo-pituitary-adrenal (HPA) axis [14].

Restraint stress is a non-painful, emotional stressor. It is one of the most widely used experimental methods used to induce neuropsychiatric disorders such as depression and anxiety [15]. This method involves the immobilization of animals, typically rodents in a confined space, which induces both physical and psychological stress responses [16]. In this procedure, the animals are placed inside a plastic tube, which prevents them from moving freely. This creates an inescapable state of physical and mental stress for the animals [17]. Stress is well known to contribute to the development of both neurological and psychological diseases.

Among the numerous organs affected by heavy metal exposure, the liver stands out due to their crucial roles in metabolism and excretion of xenobiotics [18]. However, prolonged exposure to cadmium can overwhelm the detoxification capacity of these organs, leading to hepatotoxicity characterized by hepatic damage and liver impaired function [19]. The mechanism of this damage is primarily caused by oxidative stress by lowering the action of endogenous anti-oxidants and also by inducing the production of reactive oxygen species (ROS) [9]. Recent studies have shown that experimental stress (e.g., restraint, uncontrollable shock, and noise) may be associated with a variety of alterations of the immune system in

mice and rats [20]. These changes include altered leukocyte margination, macrophage activation, and cytokine secretion.

Stress has also been shown to alter antitumor drug efficacy, wound healing, viral immunity, and cell-mediated immunity [21] [22]. Recognizing that growing evidence indicates an important role for an altered immune system and hypothalamic-pituitary-adrenal axis response in xenobiotic-induced toxicity [23]. Independently, exposure to stress and cadmium can impact liver health. However, while the biological effects of acute stress have been extensively studied and are quite well characterized, the effect of chronic stress have received little attention on some physiological and biochemical parameters despite the fact that chronic stress is more frequent [24]. Therefore, this study seeks to evaluate the effect of cadmium chloride administration and restraint stress exposure on the oxidative stress and liver function of female Wistar rats.

2. Material and Methods

2.1 Chemicals and Compounds

Cadmium chloride were acquired from Kermel, China. Normal saline, chloroform, and distilled water was purchased from Science laboratory, LAUTECH, Oyo state, Nigeria. Buffered formalin and Phosphate buffer saline was purchased from Department of Anatomy and Department of Science Laboratory Technology, LAUTECH, Oyo, Nigeria respectively.

2.2 Maintenance of animals

Female Wistar rats (24) weighing approximately 180-220g were procured. The animals were acclimatized for 14 days and unrestricted access to clean water and animal feed prior to experiments. The animals procured were kept in a typical laboratory environment (12/12 h light/dark) schedule were maintained. All animals received humane care in compliance with the guidelines of the International Standards for the Care and Use of Laboratory Animals.

2.3 Experimental protocol

Twenty-four (24) Wistar rats were randomly divided into four groups containing six (6) rats per group. Group I represent the control group while groups II, III, IV served as the experimental groups. The group designate are: I = Control group (CTL), II = Restraint stress (RSS) III = Cadmium chloride Alone (CCC), and IV = Cadmium + Restraint stress (RSC). Group I was given only feed pellet and water, Group II were subjected to restraint stress using wire mesh for 30 minutes daily, Group III were administered 100mg/kg body weight of cadmium, while Group IV was administered 100mg/kg/b.w of cadmium chloride and restrained for 30 minutes daily. The experimental duration was 21 days. Dose was selected based on the previously standardized doses for cadmium.

2.4 Cadmium Preparation

A quantified powdered 50g of cadmium chloride was dissolved in 100mls of distilled water and administered orally (0.0025 x b.w) using a beaded oral cannula. Doses were prepared daily.

2.5 Sample Collection

Twenty-four hours after the last oral administration of cadmium and restraint stress exposure, the animals were each per time placed inside a dessicator containing a chloroform soaked cotton wool for anaesthesia. Blood samples were obtained by cardiac puncture and left for 30 minutes to coagulate then centrifuged at 2500 revolutions per minutes using a centrifuge for 10 minutes. Serum samples were separated and stored at -80°C till analysis. After blood collection, liver tissue was harvested for biochemical studies. Liver were carefully removed, washed in ice-cold (20 mM Tris-HCl, 0.14 M NaCl buffer, pH 7.4) and homogenized immediately. The homogenates were centrifuged at 2500 revolutions per minutes for 10 minutes. The supernatants were used for the various biochemical determinations.

A part of the livers were also excised and prepared for histological examination using the Heamatoxylin and Eosin staining method.

2.6 Biochemical Tests

2.6.1 Evaluation of Liver Markers

Serum liver transaminase enzyme (ALT and AST) activities were measured using kits from Human (Magdeburg, Germany). Spinreact (Barcelona, Spain) kits were used to assess alkaline phosphatase (ALP). Albumin, and total protein were measured using commercial kits obtained from Human (Magdeburg, Germany). All were determined using a spectrophotometer (BM, Magdeburg, Germany, model 5010) in accordance with the methods recommended by the manufacturer.

2.6.2 Evaluation of Hepatic Antioxidant Parameters

Using commercial kits purchased from Bio-diagnostic (Cairo, Egypt), glutathione peroxidase (GPx), catalase (CAT), malondialdehyde (MDA), superoxide dismutase (SOD) and Nitric oxide (NO) activities in liver tissues were evaluated spectrophotometrically in accordance with the enclosed pamphlets.

2.7 Statistical analysis

The study's numerical data were expressed as mean \pm standard error of mean (Mean \pm SEM). A one-way Analysis of variance (ANOVA) with SPSS (version 16.0) was used to compare within groups and Duncan *post-hoc* test was used for multiple comparison. $p < 0.05$ was considered statistically significant.

3. RESULTS AND DISCUSSION

3.1 Result

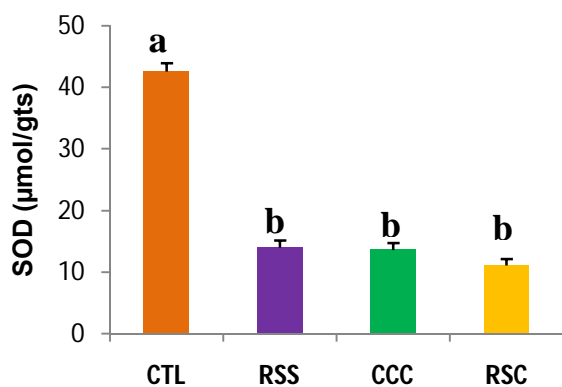
Table 1: Effect of cadmium chloride and restraint stress exposure on the liver weight and body weight gain in female Wistar rats

Weight (g)	CTL	RSS	CCC	RSC
Liver weight	5.28 ± 0.18 ^a	6.60 ± 0.24 ^b	6.35 ± 0.47 ^b	5.33 ± 0.24 ^a
Body (weight gain)	50.60 ± 2.14 ^a	5.60 ± 0.69 ^b	21.30 ± 1.53 ^c	0.50 ± 0.04 ^d

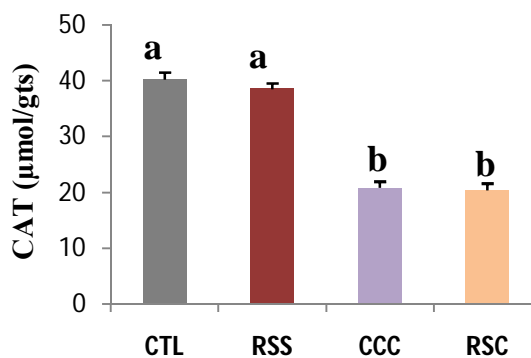
Values are express as Mean ± SEM (n=6). Mean group with superscript of different letters are significantly ($p < 0.05$) different from one another.

Result showed significant ($p < 0.05$) increase in the liver weight but a significant ($p < 0.05$) decrease in the body weight gain of RSS and CCC groups when compared to the control. RSC significantly ($p < 0.05$) decreased in body weight gain when compared with RSS and CCC.

A



B



C

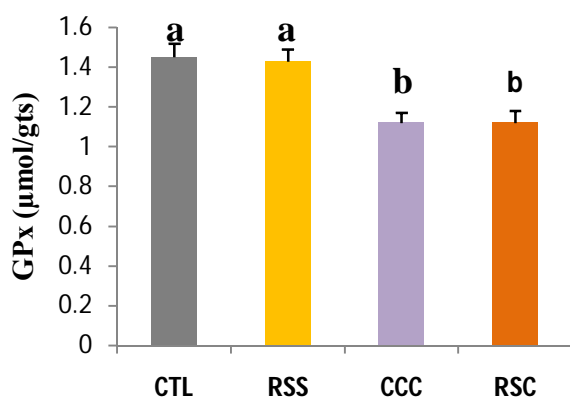


Fig.1A-C: Effect of cadmium chloride and restraint stress exposure on liver antioxidant system in female Wistar rats

Values are express as Mean \pm SEM (n=6). Mean group with superscript of different letters are significantly ($p<0.05$) different from one another.

Result showed significant decrease ($p<0.05$) in SOD of RSS and CCC groups when compared to the control. There was no significant difference ($p<0.05$) in RSC when compared with RSS and CCC groups. Furthermore, result showed no significant difference ($p<0.05$) in CAT and GPx of RSS group when compared to the Control but CCC group showed significant decrease ($p<0.05$) when compared to control. RSC was significant decreased when compared to RSS but showed no significance to CCC group.

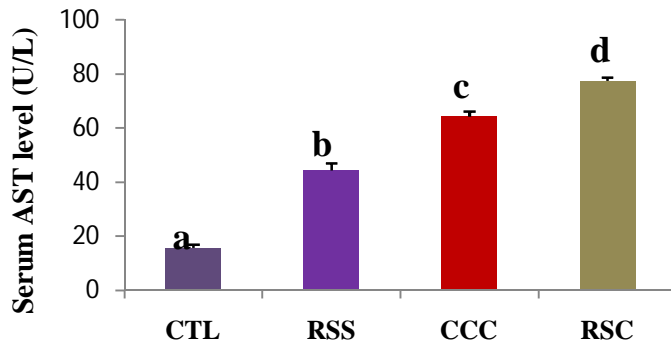
Table 2: Effect of cadmium chloride and restraint stress exposure on liver antioxidant system in female Wistar rats

Oxidative stress	CTL	RSS	CCC	RSC
MDA (nmol/gts)	30.56 \pm 1.22 ^a	33.33 \pm 1.45 ^a	48.75 \pm 1.78 ^b	60.22 \pm 1.68 ^c
NO (μ mol/gts)	1.40 \pm 0.05 ^a	0.70 \pm 0.09 ^b	0.42 \pm 0.08 ^c	0.45 \pm 0.09 ^c

Values are express as Mean \pm SEM (n=6). Mean group with superscript of different letters are significantly ($p<0.05$) different from one another.

Result showed no significant difference ($p<0.05$) in MDA of RSS group when compared to the Control but CCC group showed a significant increase ($p<0.05$) when compared to control. RSC group showed significant increase ($p<0.05$) in MDA levels when compared to CCC and RSS. NO showed significant decrease ($p<0.05$) in RSS and CCC groups when compared to the control. RSC showed no significant difference ($p<0.05$) in NO when compared to CCC but showed a significant ($p<0.05$) decrease when compared with the RSS group.

A



B

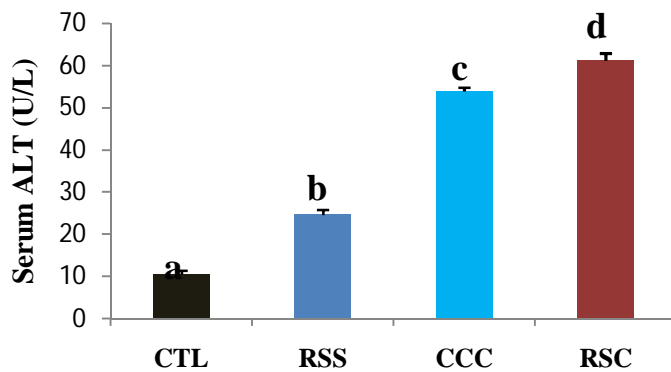


Fig. 2A-B: Effect of cadmium chloride and restraint stress exposure on liver function test (AST & ALT) in female Wistar rats.

Values are express as Mean \pm SEM (n=6). Mean group with superscript of different letters are significantly ($p < 0.05$) different from one another.

Result showed significant increase ($p < 0.05$) in both AST and ALT of RSS and CCC groups when compared to the control group. RSC significant increased ($p < 0.05$) in AST and ALT when compared with RSS and CCC.

Table 3: Effect of cadmium chloride and restraint stress exposure on liver function markers in female Wistar rats

Functions	CTL	RSS	CCC	RSC
ALP (U/L)	10.70 \pm 1.00 ^a	17.94 \pm 1.01 ^b	18.80 \pm 1.78 ^b	23.80 \pm 0.60 ^c
ALB (mg/dl)	2.27 \pm 0.19 ^a	2.46 \pm 0.16 ^a	2.43 \pm 0.17 ^a	2.07 \pm 0.04 ^a

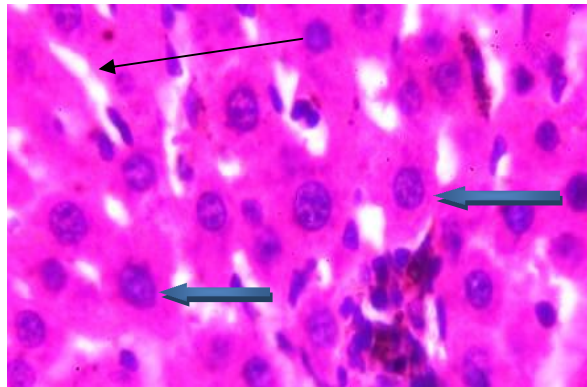
TP (mg/dl)	6.46 ± 0.38 ^a	5.61 ± 0.25 ^a	4.53 ± 0.17 ^b	4.69 ± 0.10 ^b
------------	--------------------------	--------------------------	--------------------------	--------------------------

Values are express as Mean ± SEM (n=6). Mean group with superscript of different letters are significantly (p<0.05) different from one another.

Result showed no significant difference (p<0.05) in TP of RSS group when compared to the Control but CCC group showed significant increase (p<0.05) when compared to control. RSC group showed significant increase (p<0.05) in ALP when compared to RSS and CCC groups. TP showed significant decrease in RSC when compared to RSS but showed no significance difference when compared to CCC. ALB showed no significance across all groups.

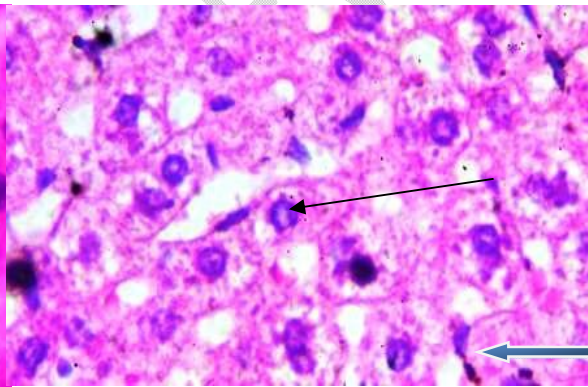
Histological Results

Plate 1. CONTROL



X400

Plate 2. CDCL ALONE



X400

Plate 3. RS ALONE

Plate 4. CDCL + RS

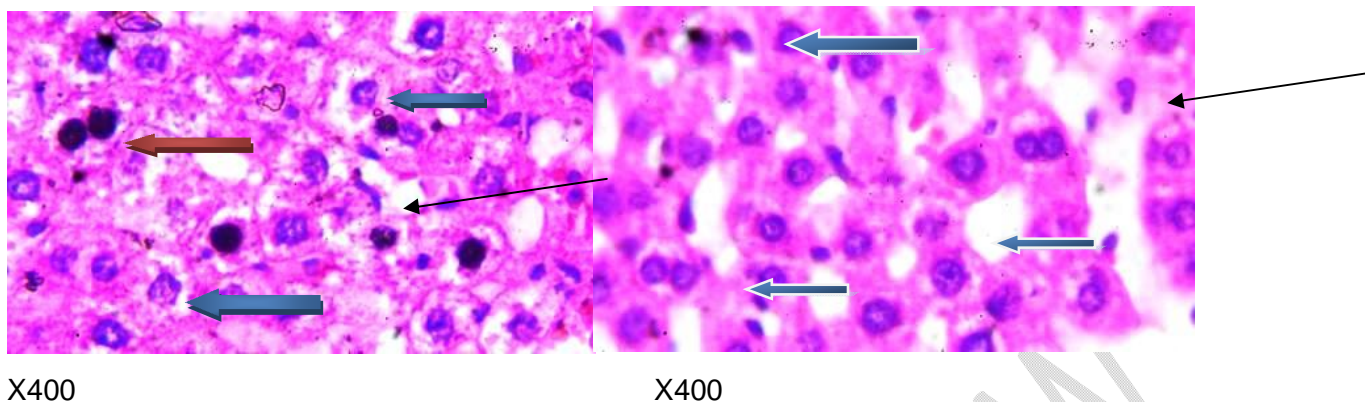


Fig. 3: Effect of cadmium chloride and restraint stress exposure on liver histology in female Wistar rats.

Plate 1: Photomicrograph of a liver section stained by Haematoxylin and Eosin showing normal central venules, the morphology of the hepatocytes appear normal (blue arrow), the sinusoids appear normal and not infiltrated (slender arrow).

Plate 2: Photomicrograph of a liver section stained by Haematoxylin and Eosin showing mild peri vascular infiltration of inflammatory cells (black arrow), the morphology of the hepatocytes show severe hepatic steatosis, severe cytoplasmic fat infiltration (blue arrow), the sinusoids appear normal and not infiltrated (slender arrow).

Plate 3: Photomicrograph of a liver section stained by Haematoxylin and Eosin showing mild peri vascular infiltration of inflammatory cells (black arrow), the morphology of some the hepatocytes show hyperchromatic nuclei (red arrow) and severe hepatic steatosis, severe cytoplasmic fat infiltration and necrosis (blue arrow). The sinusoids appear normal and not infiltrated (slender arrow).

Plate 4: Photomicrograph of a liver section stained by Haematoxylin and Eosin showing normal central venules. The morphology of the hepatocytes seen appear normal (blue arrow), the sinusoids appear normal and not infiltrated (slender arrow).

3.2 Discussion

Stress, is often characterized as an adaptive response which could either be physical, mental, or emotional, towards events capable of causing shifts in the homeostatic mechanism of an organism, allowing it to maximize its chances of survival when facing a stressor [25]. The stress response is an important element in adaptation to environmental changes [26] but provokes a variety of physiological and biochemical changes that may alter the response of the body to xenobiotics [27]. According to Wang and Denhardt. [28] have shown that acute stress, in the form of physical restraint, enhances the delayed-type hypersensitivity response. Increase in stress level has been linked to excessive reactive oxygen species production, leading to impaired liver integrity and cellular membrane function [29]. The different internal organs of animals perform different functions and this is so because, apart from structural differences, the chemical (enzymatic and non-enzymatic) constituents of the different organs vary, thereby giving rise to different chemical reactions in the cells of the affected organs [30].

Exposure to cadmium chloride and external stressor individually significantly ($p < 0.05$) increased the weight of the liver of the female Wistar rats (Table 1). It has been reported that organ weights are considered an important criterion for the evaluation of organ toxicity [31]. In table 1, Cadmium exposure led to an increase in liver weight probably due to induced oxidative stress and inflammation, causing hepatocyte injury and compensatory hypertrophy [32]. Similarly, the restraint stress group also showed increased liver weight, as stress hormones like glucocorticoids (cortisol) alter metabolic pathways, promoting gluconeogenesis and reported studies fat accumulation in the liver [33]. However, the combination of cadmium and restraint stress did not show a significant difference compared to the control group, but it significantly decreased ($p < 0.05$) relative to both the cadmium and restraint stress groups. This suggests that neither factor significantly affects liver metabolism or engages the HPA axis leading to cellular growth, indicating resilience of the cellular growth to stress or a lack of hepatotoxic effects on the liver weights [34]. This result is consistent with Ref. [35] showing that specific stressors and compounds do not negatively impact liver morphology.

Furthermore, the body weight gain showed significant ($p < 0.05$) decrease in restraint and cadmium group when compared to control (Table 1). RSC group further showed significant decrease when compared to restraint group and cadmium group. Restraint stress triggers the HPA axis, increasing glucocorticoid release, which suppresses appetite and induces protein catabolism [36] [37]. Similarly, cadmium exposure induces oxidative stress and disrupts metabolic functions [38]. Together, these stressors exacerbate oxidative damage and metabolic inefficiency, with the RSC group displaying the most substantial weight reduction, consistent with studies showing amplified cellular damage under combined stress conditions [39]

Oxidative stress is a physiological imbalance between reactive oxygen species (ROS) production and anti-oxidant defense mechanisms, often resulting in cellular damage and metabolic disturbances [40]. It is a critical factor in multiple pathologies. Exposure to environmental toxins like cadmium and chronic stress are linked to increased oxidative damage [41]. Heavy metals has been known to induce oxidative stress by disrupting redox homeostasis, while psychological stress may exacerbates this damage [42]. In fig.1A-C, the study revealed that cadmium exposure alone impairs SOD, CAT, and GPx activities, which could compromise antioxidant defenses and enhance oxidative stress in the liver. Restraint stress alone, while decreasing SOD, did not affect CAT and GPx, suggesting a less severe impact on overall antioxidant defense. Notably, the combined exposure (RSC) did not exacerbate the oxidative stress response compared to cadmium alone, implying that cadmium's effect may overshadow the additional impact of restraint stress on these antioxidants. This aligns with Ref. [43] demonstrating cadmium's potent oxidative effects and suggests that in cases of co-exposure, cadmium likely acts as the primary driver of oxidative damage.

Malondialdehyde is a byproduct of lipid peroxidation, which occurs when oxidative stress damages cell membranes [44]. In table 2, Cadmium chloride majorly elevated the hepatic MDA levels with an exacerbated effect observed in the combined treatment groups (RSC). The significant elevation in MDA within the CCC and RSC groups aligns with cadmium's known pro-oxidant properties, which increase lipid peroxidation by disrupting cellular antioxidant defenses [45]. These findings indicate that cadmium chloride exposure alone induces significant oxidative stress, but this effect intensified when combined with restraint stress, confirming an additive impact on lipid peroxidation. Moreover, Nitric oxide depletion across cadmium and RSC groups reflects impaired Nitric oxide synthesis and stability, likely due to oxidative interactions that deplete nitric oxide level, reducing vascular and cellular resilience [46]. The results align with previous studies indicating cadmium's capacity to induce oxidative damage via lipid peroxidation, further exacerbated when combined with physical stress [47].

Cadmium and stressors' hepatotoxicity has been related to the elevation in the levels of serum liver enzymes Aspartate Aminotransferase (AST), Alanine Aminotransferase (ALT) and Alkaline Phosphatase (ALP) and alterations in hepatic cholesterol metabolism [48]. In fig 2A-B, the results showed a significant increase ($p < 0.05$) in both AST and ALT levels in the restraint stress (RSS) and cadmium (CCC) groups compared to the control group. Additionally, there was a significant increase ($p < 0.05$) in AST and ALT levels in the restraint stress + cadmium (RSC) group compared to both the RSS and CCC groups. Restraint stress is known to elevate serum AST and ALT levels, likely through an overproduction of glucocorticoids and catecholamines (e.g., cortisol and adrenaline) from the adrenal glands [49]. This hormonal surge disrupts cellular homeostasis and increases the production of reactive oxygen species (ROS), which can damage liver cells and compromise their integrity [50]. Damaged hepatocytes release transaminase enzymes into the bloodstream, resulting in elevated enzyme levels as markers of liver damage [51]. Studies have shown that oxidative stress and inflammatory pathways activated under restraint stress are mediated by factors such as nuclear factor kappa B (NF- κ B) and increased lipid peroxidation, which further contributes to hepatocyte injury [52]. Cadmium on the other hand induces hepatotoxicity primarily through oxidative stress and lipid peroxidation, leading to significant cellular damage. Cadmium exposure disrupts antioxidant defenses by depleting glutathione and altering the activity of antioxidant enzymes like superoxide dismutase and catalase. Consequently, excessive ROS accumulate within hepatocytes, damaging cellular components like lipids, proteins, and DNA, which ultimately results in cell death and the release of AST and ALT into the blood [53].

The RSC group further demonstrated an even more significant increase in AST and ALT levels compared to the RSS and CCC groups alone suggesting a synergistic effect, where the oxidative stress from restraint combine with cadmium's toxic properties leads to exacerbated liver damage. Cadmium exposure alone can upregulate stress-related pathways, but when combined with restraint stress, the additional glucocorticoid and catecholamine release intensifies ROS production and overwhelms the liver's antioxidant defenses, resulting in severe hepatocyte damage [54]. This was aligned with Ref. [55]

indicating that cadmium exposure combined with additional stressors like heat or psychological stress amplifies liver enzyme elevation and cellular damage due to compounded oxidative stress and inflammation.

Furthermore, albumin levels are similar across all groups, with no statistically significant ($p < 0.05$) differences noted (Table 3). This suggests that neither restraint stress nor cadmium exposure affects albumin synthesis or degradation. Studies typically find that albumin levels remain stable under stress, except under conditions of severe liver dysfunction, malnutrition, or chronic illness [56]. The lack of variation in albumin levels here aligns with past findings, as transient stressors, such as acute restraint or cadmium exposure, are generally insufficient to disrupt albumin synthesis [57]. Restraint stress and cadmium exposure independently elevate alkaline phosphate levels (Table 3), likely due to increased liver metabolic activity in response to stress [58]. The highest alkaline phosphate levels in the RSC group suggest an additive effect of these stressors, highlighting their cumulative impact on liver function. This is consistent with studies reporting that combined stressors amplify metabolic responses [59]. Total protein levels, however, are significantly impacted by cadmium alone, with minimal change under restraint stress alone. The substantial reduction in total protein in both cadmium and RSC groups suggests cadmium's inhibitory effect on protein synthesis, possibly through oxidative stress mechanisms known to disrupt protein synthesis and degradation [60]. Restraint stress, while elevating alkaline phosphate appears to contribute little to protein catabolism, as reflected by total protein levels.

The histological examination in fig.3, revealed that central venules of the liver slides is normal in Plate 1 (Control) but the liver tissue showed a mild perivascular infiltration of inflammatory cells in the liver tissues of CCC group (Plate 2). Sinusoids appear normal and not infiltrated in the cadmium and restraint stress group. The morphology of the hepatocytes of cadmium exposure showed severe hepatic steatosis, severe cytoplasmic fat infiltration while. This could be because, the mild perivascular infiltration suggests a localized inflammatory response. Hepatocyte injury can release damage-associated molecular patterns (DAMPs), attracting immune cells to the area [61]. These cells may be involved in repairing tissue or clearing damaged cells. In response to hepatocyte injury and steatosis, the liver may release cytokines and chemokines that promote inflammation and recruit inflammatory cells [62]. Even mild infiltration can indicate an ongoing repair process or a response to injury.

In the Restraint stress, the morphology of some the hepatocytes showed hyperchromatic nuclei and severe hepatic steatosis, severe cytoplasmic fat infiltration and necrosis (Plate 3). Studies have shown that, under restraint stress, there may be an increase in lipogenesis and a decrease in fatty acid oxidation [63]. This imbalance results in the accumulation of lipids within hepatocytes, leading to severe steatosis and cytoplasmic fat infiltration [64]. The combination of oxidative stress, lipid accumulation, and possibly inflammation can lead to cellular injury and necrosis. Cadmium + Restraint stress group it shows that the morphology of the hepatocytes seen appear. Hepatocytes are highly adaptable and capable of

responding to stress [65]. They may activate protective pathways, such as upregulating antioxidant defenses (e.g., glutathione), which help neutralize reactive oxygen species (ROS) generated by cadmium exposure and restraint stress [10]. Also, the extent of injury often depends on the duration and concentration of cadmium exposure. If the exposure was sub-lethal or the restraint stress was manageable, the liver may successfully avoid significant damage [66].

CONCLUSION

Cadmium exposure and restraint stress independently cause significant oxidative stress, liver toxicity, and metabolic disruption, as indicated by increased organ weight, elevated biochemical markers of liver damage. The combined exposure to cadmium and restraint stress further intensifies exacerbated these effects, suggesting a synergistic impact that leads to more pronounced liver injury and oxidative stress. Histological findings also support these outcomes, showing structural liver damage, fat accumulation, and localized inflammation.

DISCLAIMER (ARTIFICIAL INTELLIGENCE)

I hereby declare that NO generative AI technologies such as Large Language Models (ChatGPT, COPILOT, etc) and text-to-image generators have been used during writing or editing of manuscripts.

INSTITUTIONAL REVIEW BOARD STATEMENT

The international guidelines for the use of animals in research, teaching and testing were employed. The regulations were adhere to throughout the process of research.

INFORMED CONSENT STATEMENT

Not applicable

REFERENCE

1. Vardhan, K. H., Kumar, P. S., & Panda, R. C. (2019). A review on heavy metal pollution, toxicity and remedial measures: Current trends and future perspectives. *Journal of Molecular Liquids*, 290, 111197.
2. Jaiswal, A., Verma, A., & Jaiswal, P. (2018). Detrimental effects of heavy metals in soil, plants, and aquatic ecosystems and in humans. *Journal of Environmental Pathology, Toxicology and Oncology*, 37(3).
3. Ali, H., Khan, E., & Ilahi, I. (2019). Environmental chemistry and ecotoxicology of hazardous heavy metals: environmental persistence, toxicity, and bioaccumulation. *Journal of chemistry*, 2019(1), 6730305.

4. Adekanmi, A. T. (2021). Health hazards of toxic and essential heavy metals from the poultry waste on human and aquatic organisms. *Animal Feed Science and Nutrition-Production, Health and Environment*.
5. Chowdhury, F. N., & Rahman, M. M. (2024). Source and Distribution of Heavy Metal and Their Effects on Human Health. In *Heavy Metal Toxicity: Human Health Impact and Mitigation Strategies* (pp. 45-98). Cham: Springer Nature Switzerland.
6. Zhou, Y., Ashokkumar, V., Amobonye, A., Bhattacharjee, G., Sirohi, R., Singh, V., Flora, G., Kumar, V., Pillai, S., Zhang, Z. and Awasthi, M.K., (2023). Current research trends on cosmetic microplastic pollution and its impacts on the ecosystem: A review. *Environmental Pollution*, 320, p.121106.
7. Fatima, G., Raza, A. M., Hadi, N., Nigam, N., & Mahdi, A. A. (2019). Cadmium in human diseases: It's more than just a mere metal. *Indian Journal of Clinical Biochemistry*, 34(4), 371-378.
8. Hong, H., Xu, J., He, H., Wang, X., Yang, L., Deng, P., Yang, L., Tan, M., Zhang, J., Xu, Y. and Tong, T., (2022). Cadmium perturbed metabolomic signature in pancreatic beta cells correlates with disturbed metabolite profile in human urine. *Environment international*, 161, p.107139.
9. Unsal, V., Dalkiran, T., Çiçek, M., & Kölükçü, E. (2020). The role of natural antioxidants against reactive oxygen species produced by cadmium toxicity: a review. *Advanced pharmaceutical bulletin*, 10(2), 184-202.
10. Elmallah, M. I., Elkhadragey, M. F., Al-Olayan, E. M., & Abdel Moneim, A. E. (2017). Protective effect of *Fragaria ananassa* crude extract on cadmium-induced lipid peroxidation, antioxidant enzymes suppression, and apoptosis in rat testes. *International journal of molecular sciences*, 18(5), 957.
11. Russell, G., & Lightman, S. (2019). The human stress response. *Nature reviews endocrinology*, 15(9), 525-534.
12. Miller, G. E., Chen, E., & Parker, K. J. (2011). Psychological stress in childhood and susceptibility to the chronic diseases of aging: moving toward a model of behavioral and biological mechanisms. *Psychological bulletin*, 137(6), 959.
13. Chen, Y., Arsenault, R., Napper, S., & Griebel, P. (2015). Models and methods to investigate acute stress responses in cattle. *Animals*, 5(4), 1268-1295.
14. Herman, J.P., McKlveen, J.M., Ghosal, S., Kopp, B., Wulsin, A., Makinson, R., Scheimann, J. and Myers, B., (2016). Regulation of the hypothalamic-pituitary-adrenocortical stress response. *Comprehensive physiology*, 6(2), p.603.
15. Singaravelu, S. K. (2022). *Timing matters: the impact of repeated restraint stress on NGF induced sensitization of spinal dorsal horn neurons in an animal model of myofascial low back pain* (Doctoral dissertation).

16. Bali, A., & Jaggi, A. S. (2015). Preclinical experimental stress studies: protocols, assessment and comparison. *European journal of pharmacology*, 746, 282-292.
17. Bower, C. (2022). The Role of the Practice Environment. In *Companion Animal Behaviour Problems: Prevention and Management of Behaviour Problems in Veterinary Practice* (pp. 65-75). GB: CABI.
18. Topić Popović, N., Čižmek, L., Babić, S., Strunjak-Perović, I., & Čož-Rakovac, R. (2023). Fish liver damage related to the wastewater treatment plant effluents. *Environmental science and pollution research*, 30(17), 48739-48768.
19. Balali-Mood, M., Naseri, K., Tahergorabi, Z., Khazdair, M. R., & Sadeghi, M. (2021). Toxic mechanisms of five heavy metals: mercury, lead, chromium, cadmium, and arsenic. *Frontiers in pharmacology*, 12, 643972.
20. Verbitsky, A., Dopfel, D., & Zhang, N. (2020). Rodent models of post-traumatic stress disorder: behavioral assessment. *Translational psychiatry*, 10(1), 132.
21. Englinger, B., Pirker, C., Heffeter, P., Terenzi, A., Kowol, C. R., Keppler, B. K., & Berger, W. (2018). Metal drugs and the anticancer immune response. *Chemical reviews*, 119(2), 1519-1624.
22. Tang, F., Tie, Y., Tu, C., & Wei, X. (2020). Surgical trauma-induced immunosuppression in cancer: recent advances and the potential therapies. *Clinical and translational medicine*, 10(1), 199-223.
23. Zhang, C., Xu, D., Luo, H., Lu, J., Liu, L., Ping, J., & Wang, H. (2014). Prenatal xenobiotic exposure and intrauterine hypothalamus–pituitary–adrenal axis programming alteration. *Toxicology*, 325, 74-84.
24. Golbidi, S., Frisbee, J. C., & Laher, I. (2015). Chronic stress impacts the cardiovascular system: animal models and clinical outcomes. *American Journal of Physiology-Heart and Circulatory Physiology*.
25. Finan, P. H., Zautra, A. J., & Wershba, R. (2011). The dynamics of emotion in adaptation to stress. *The handbook of stress science: Biology, psychology, and health*, 16, 209-220.
26. Kristensen, T. N., Ketola, T., & Kronholm, I. (2020). Adaptation to environmental stress at different timescales. *Annals of the new York Academy of Sciences*, 1476(1), 5-22.
27. Farag, M. R., & Alagawany, M. (2018). Erythrocytes as a biological model for screening of xenobiotics toxicity. *Chemico-biological interactions*, 279, 73-83.
28. Wang, K. X., & Denhardt, D. T. (2008). Osteopontin: role in immune regulation and stress responses. *Cytokine & growth factor reviews*, 19(5-6), 333-345.
29. Ezhilarasan, D. (2018). Oxidative stress is bane in chronic liver diseases: Clinical and experimental perspective. *Arab Journal of Gastroenterology*, 19(2), 56-64.

30. Sultana, K., Jayathilakan, K., & Sajeevkumar, V. A. (2022). Chemistry of Animal Tissues. In *Advances in Food Chemistry: Food Components, Processing and Preservation* (pp. 385-437). Singapore: Springer Nature Singapore.
31. van Berlo, D., Woutersen, M., Muller, A., Pronk, M., Vriend, J., & Hakkert, B. (2022). 10% Body weight (gain) change as criterion for the maximum tolerated dose: A critical analysis. *Regulatory Toxicology and Pharmacology*, *134*, 105235.
32. Zou, H., Sun, J., Wu, B., Yuan, Y., Gu, J., Bian, J., Liu, X. and Liu, Z., (2020). Effects of cadmium and/or lead on autophagy and liver injury in rats. *Biological Trace Element Research*, *198*, pp.206-215.
33. van Berlo, D., Woutersen, M., Muller, A., Pronk, M., Vriend, J., & Hakkert, B. (2022). 10% Body weight (gain) change as criterion for the maximum tolerated dose: A critical analysis. *Regulatory Toxicology and Pharmacology*, *134*, 105235.
34. Panossian, A.G., Efferth, T., Shikov, A.N., Pozharitskaya, O.N., Kuchta, K., Mukherjee, P.K., Banerjee, S., Heinrich, M., Wu, W., Guo, D.A. and Wagner, H., (2021). Evolution of the adaptogenic concept from traditional use to medical systems: Pharmacology of stress-and aging-related diseases. *Medicinal research reviews*, *41*(1), pp.630-703.
35. Everds, N.E., Snyder, P.W., Bailey, K.L., Bolon, B., Creasy, D.M., Foley, G.L., Rosol, T.J. and Sellers, T., (2013). Interpreting stress responses during routine toxicity studies: a review of the biology, impact, and assessment. *Toxicologic pathology*, *41*(4), pp.560-614.
36. Maniam, J., & Morris, M. J. (2012). The link between stress and feeding behaviour. *Neuropharmacology*, *63*(1), 97-110.
37. Jeong, J. Y., Lee, D. H., & Kang, S. S. (2013). Effects of chronic restraint stress on body weight, food intake, and hypothalamic gene expressions in mice. *Endocrinology and metabolism*, *28*(4), 288.
38. Nemmiche, S. (2017). Oxidative signaling response to cadmium exposure. *Toxicological sciences*, *156*(1), 4-10.
39. Ortega, A. D. S. V., & Szabó, C. (2021). Adverse effects of heat stress on the intestinal integrity and function of pigs and the mitigation capacity of dietary antioxidants: a review. *Animals*, *11*(4), 1135.
40. He, L., He, T., Farrar, S., Ji, L., Liu, T., & Ma, X. (2017). Antioxidants maintain cellular redox homeostasis by elimination of reactive oxygen species. *Cellular Physiology and Biochemistry*, *44*(2), 532-553.
41. Genchi, G., Sinicropi, M. S., Lauria, G., Carocci, A., & Catalano, A. (2020). The effects of cadmium toxicity. *International journal of environmental research and public health*, *17*(11), 3782.
42. Garza-Lombó, C., Posadas, Y., Quintanar, L., Gonsebatt, M. E., & Franco, R. (2018). Neurotoxicity linked to dysfunctional metal ion homeostasis and xenobiotic metal exposure: redox signaling and oxidative stress. *Antioxidants & redox signaling*, *28*(18), 1669-1703.

43. Cao, Y., Zhao, M., Ma, X., Song, Y., Zuo, S., Li, H., & Deng, W. (2021). A critical review on the interactions of microplastics with heavy metals: Mechanism and their combined effect on organisms and humans. *Science of the Total Environment*, 788, 147620.
44. Jadoon, S., & Malik, A. (2017). A review article on the formation, mechanism and biochemistry of MDA and MDA as a biomarker of oxidative stress. *Int. J. Adv. Res*, 5, 811-818.
45. Almenara, C. C., Oliveira, T. F., & Padilha, A. S. (2020). The role of antioxidants in the prevention of cadmium-induced endothelial dysfunction. *Current pharmaceutical design*, 26(30), 3667-3675.
46. Ghezzi, P., Floridi, L., Boraschi, D., Cuadrado, A., Manda, G., Levic, S., D'Acquisto, F., Hamilton, A., Athersuch, T.J. and Selley, L., (2018). Oxidative stress and inflammation induced by environmental and psychological stressors: a biomarker perspective. *Antioxidants & redox signaling*, 28(9), pp.852-872.
47. Garcia-Caparros, P., De Filippis, L., Gul, A., Hasanuzzaman, M., Ozturk, M., Altay, V., & Lao, M. T. (2021). Oxidative stress and antioxidant metabolism under adverse environmental conditions: a review. *The Botanical Review*, 87, 421-466.
48. Goodarzi, Z., Karami, E., Yousefi, S., Dehdashti, A., Bandegi, A. R., & Ghanbari, A. (2020). Hepatoprotective effect of atorvastatin on Cadmium chloride induced hepatotoxicity in rats. *Life sciences*, 254, 117770.
49. Killilea, M. (2018). *Stress-induced exacerbation of LPS/GaIN liver injury* (Doctoral dissertation, National University of Ireland Galway).
50. Llanos, P., & Palomero, J. (2022). Reactive Oxygen and Nitrogen Species (RONS) and Cytokines—Myokines Involved in Glucose Uptake and Insulin Resistance in Skeletal Muscle. *Cells*, 11(24), 4008.
51. Contreras-Zentella, M. L., & Hernández-Muñoz, R. (2016). Is liver enzyme release really associated with cell necrosis induced by oxidant stress?. *Oxidative medicine and cellular longevity*, 2016(1), 3529149.
52. Jia, R., Li, Y., Cao, L., Du, J., Zheng, T., Qian, H., Gu, Z., Jeney, G., Xu, P. and Yin, G., (2019). Antioxidative, anti-inflammatory and hepatoprotective effects of resveratrol on oxidative stress-induced liver damage in tilapia (*Oreochromis niloticus*). *Comparative Biochemistry and Physiology Part C: Toxicology & Pharmacology*, 215, pp.56-66.
53. Mohamed, J., Nafizah, A. N., Zariyantey, A. H., & Budin, S. (2016). Mechanisms of diabetes-induced liver damage: the role of oxidative stress and inflammation. *Sultan qaboos university medical journal*, 16(2), e132.
54. Heining, K. Aging is selected for, adaptive and programmed. 17. The stress axis of aging.
55. Ghezzi, P., Floridi, L., Boraschi, D., Cuadrado, A., Manda, G., Levic, S., D'Acquisto, F., Hamilton, A., Athersuch, T.J. and Selley, L., (2018). Oxidative stress and inflammation induced by environmental and psychological stressors: a biomarker perspective. *Antioxidants & redox signaling*, 28(9), pp.852-872.

56. Gremese, E., Bruno, D., Varriano, V., Perniola, S., Petricca, L., & Ferraccioli, G. (2023). Serum albumin levels: a biomarker to be repurposed in different disease settings in clinical practice. *Journal of Clinical Medicine*, 12(18), 6017.
57. Flora, S. J., & Agrawal, S. (2017). Arsenic, cadmium, and lead. In *Reproductive and developmental toxicology* (pp. 537-566). Academic Press.
58. Chen, H., Zhu, C., & Zhou, X. (2023). Effects of lead and cadmium combined heavy metals on liver function and lipid metabolism in mice. *Biological trace element research*, 201(6), 2864-2876.
59. Preiser, J. C., Ichai, C., Orban, J. C., & Groeneveld, A. B. J. (2014). Metabolic response to the stress of critical illness. *British journal of anaesthesia*, 113(6), 945-954.
60. Genchi, G., Sinicropi, M. S., Lauria, G., Carocci, A., & Catalano, A. (2020). The effects of cadmium toxicity. *International journal of environmental research and public health*, 17(11), 3782.
61. Mihm, S. (2018). Danger-associated molecular patterns (DAMPs): molecular triggers for sterile inflammation in the liver. *International journal of molecular sciences*, 19(10), 3104.
62. Del Campo, J. A., Gallego, P., & Grande, L. (2018). Role of inflammatory response in liver diseases: Therapeutic strategies. *World journal of hepatology*, 10(1), 1.
63. Lee, S.B., Kim, H.G., Lee, J.S., Kim, W.Y., Lee, M.M., Kim, Y.H., Lee, J.O., Kim, H.S. and Son, C.G., 2019. Intermittent restraint-induced sympathetic activation attenuates hepatic steatosis and inflammation in a high-fat diet-fed mouse model. *American Journal of Physiology-Gastrointestinal and Liver Physiology*, 317(6), pp.G811-G823.
64. Gu, J., Yao, M., Yao, D., Wang, L., Yang, X., & Yao, D. (2016). Nonalcoholic lipid accumulation and hepatocyte malignant transformation. *Journal of Clinical and Translational Hepatology*, 4(2), 123.
65. Zhou, Z., Xu, M. J., & Gao, B. (2016). Hepatocytes: a key cell type for innate immunity. *Cellular & molecular immunology*, 13(3), 301-315.
66. Baldwin, N. P. (2019). *Evaluating the sub-lethal toxicity of the organophosphate pesticide, chlorpyrifos, on the amphibian, Xenopus laevis* (Doctoral dissertation, University of Saskatchewan).