

Case report

Hansen's Comedonicus: Borderline Tuberculoid Hansen's Disease with Comedones: A Rare Phenomena

ABSTRACT

The proportion of childhood leprosy is a red flag marker of the efficacy of Leprosy Control Programmes as it represents active case transmission in the population. Lack of well-defined clinical signs in children make this section of population highly vulnerable for late diagnosis and leading to disabilities and complications. Prevalence of Hansen's disease has increased since the last decade with many atypical presentations which make it more difficult to diagnose. We present the case of a 13-year-old boy with Hansen's disease where anaesthetic plaques were associated with multiple comedones over them resulting into an unusual presentation.

Key Words: Comedones, Borderline tuberculoid, Follicular plugging

Introduction

Hansen's disease has many atypical forms which make it difficult to diagnose and manage. In an infected patient *Mycobacterium leprae* harbour in sweat gland, sebaceous gland, hair follicle and arrector pili muscle. In lepromatous pole adnexal structure get atrophied due to granuloma pressure where as in tuberculoid pole inflammatory cell infiltrate destroy them [7-9]. Nerve conduction impairment causes the dysfunctions of skin appendages including hair growth, sebaceous gland secretion, sweating, and skin pigmentation which lead to different clinical pictures. *M. leprae* are discharged and disseminated through secretions and therefore infection through skin-to-skin contact can be one of the common modes of transmission of the disease [1].

CASE PRESENTATION

A 13 Years old male presented to dermatology OPD with hypoanaesthetic white color lesions over right shoulder and right thigh with a specific complain that acne appearing over these lesion for 1 years. Duration and progression of skin lesion and acne like lesion was similar. He did not give any history of anti-

leprosy treatment or any other oral or topical treatment for the illness. No other positive or negative relevant history was elicited.

On examination two well defined hypopigmented plaques with mild erythema over right shoulder with multiple open comedones all over lesion with black keratotic plugging with around size of 2×2 centimeters and 4×3 centimeters, and on posterior aspect of right thigh with size of 10×6 centimeters. Comedones can be extracted by comedone extractor (Figure1, Figure 2).

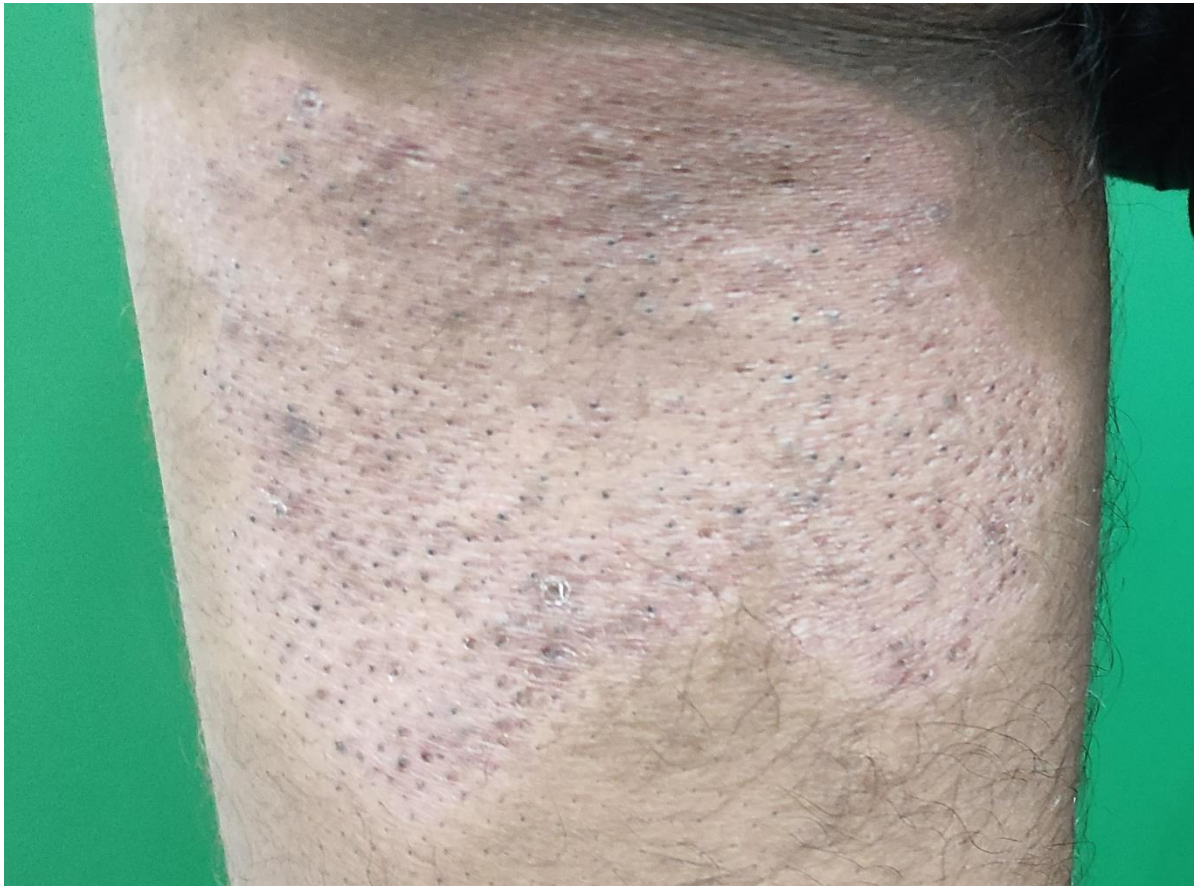

Figure 1. Hypopigmented plaque with multiple comedones over it on left thigh.

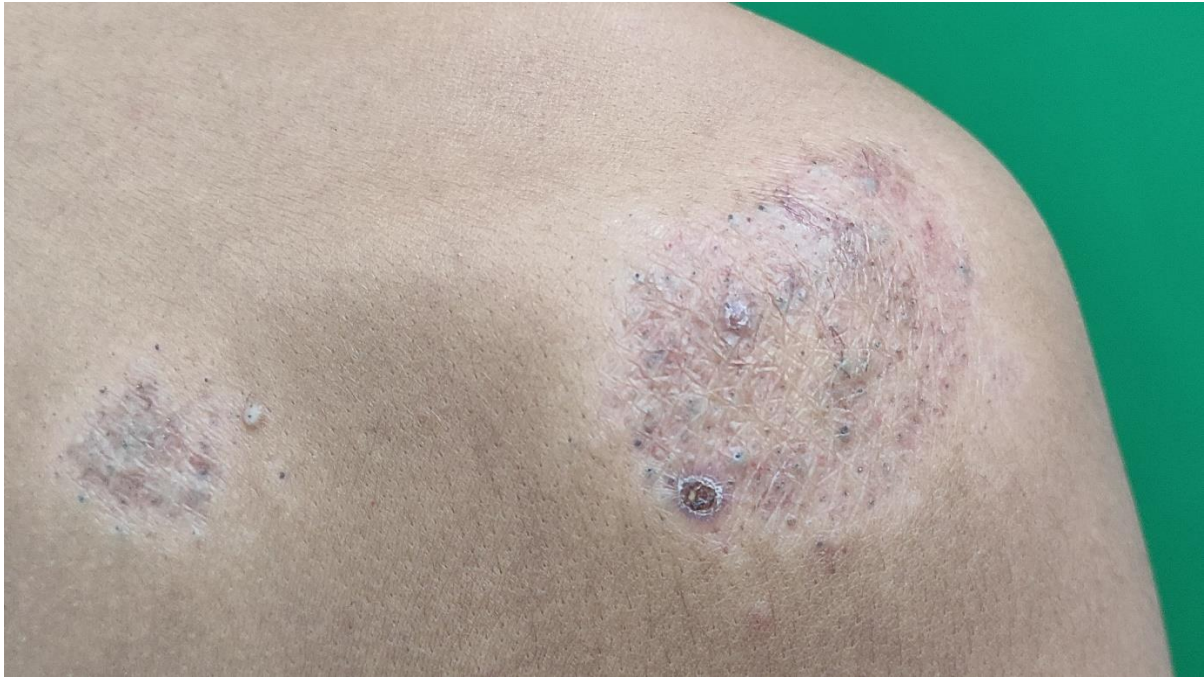

Figure 2. Two hypopigmented plaque on right shoulder with multiple comedones over them.

On dermatoscopy of left thigh lesion yellowish-brownish structureless area with decreased number of hair follicles, patchy loss of pigment network with white streaks and shiny scaling and accentuation of skin markings. Few areas with follicular keratin plugging with perifollicular and periappendageal pigmentation over erythematous to brownish background (Figure 3).

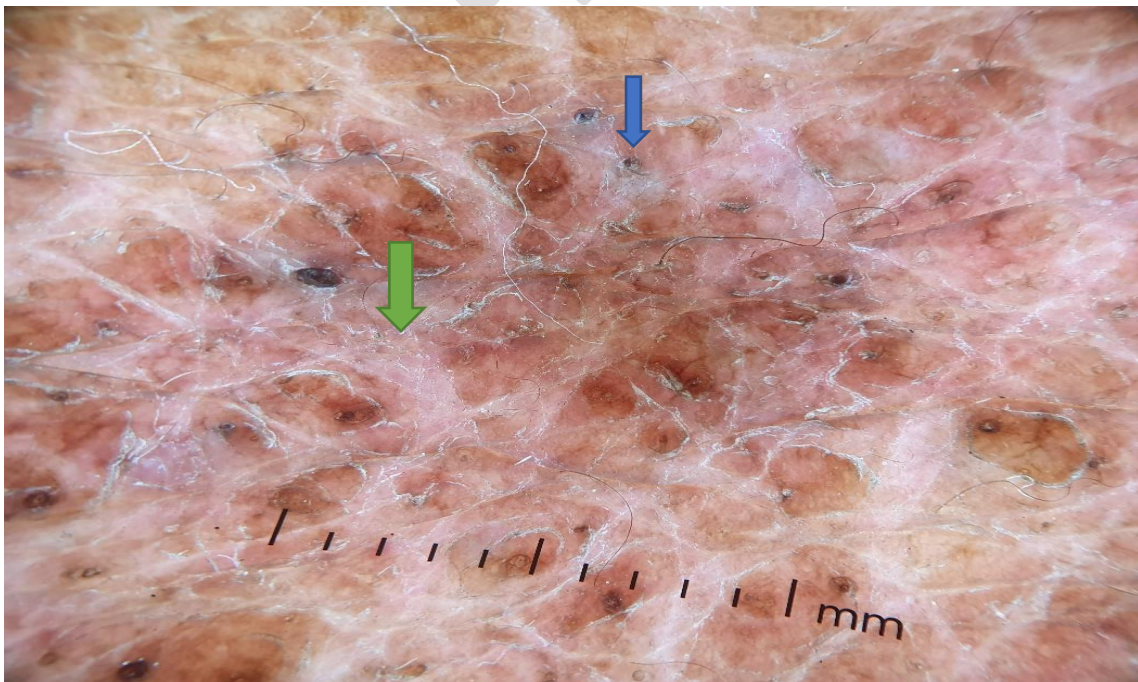


Figure 3. Dermatoscopic examination: blue arrow showing follicular keratin plugging and green arrow denotes patchy loss of pigment network.

On further examination there was frank sensory loss to touch and temperature over lesions. Slit skin smear was negative from all sites. Histopathological sections from skin biopsy from plaque of right shoulder reveal small to ill formed granulomas with peripheral lymphocytes along neurovascular bundles and also infiltrating erector pili muscle. Occasional small Langhan's giant cell is noted. Epidermis showed hyperkeratosis and follicular plugging. All these findings are suggestive of borderline tuberculoid leprosy. Z N-stained section was negative (Figure 4).

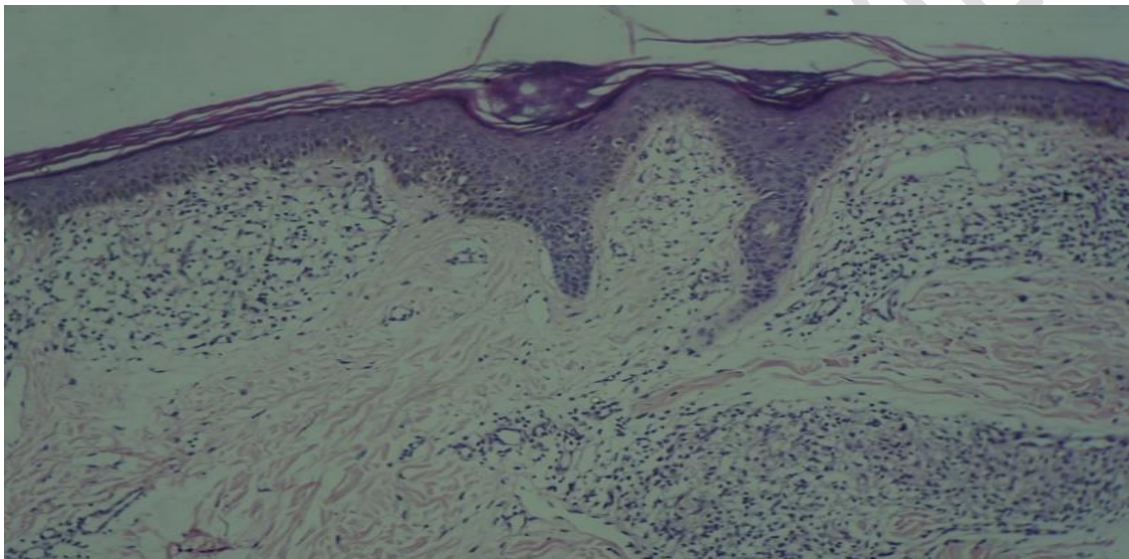


Figure 4. Epidermis showed hyperkeratosis and follicular plugging. Ill formed granulomas with peripheral lymphocytes along neurovascular bundles and also infiltrating erector pili muscle.

Patient was started on MDT MB child blister pack and was on monthly follow-up for 12 months with no progression in disease and satisfactory symptomatic improvement. It was interesting to see skin lesions were showing changes of resolution of leprosy but comedones were still present in significant number (Figure 6, Figure 7). During whole treatment period patient applied nothing over lesions.

Repeat biopsy was performed before release from treatment from same site which shows sparse superficial and mid perivascular and peri appendageal lymphocytic infiltrate with partial effacement of rete ridges. The dermoepidermal junction is

focally infiltrated by lymphocytes. There is no granuloma. In view of clinical features these findings are consistent with healed borderline tuberculoid Hansen's disease (Figure 5). Patient was counselled for follow-up and explained about post treatment course and prognosis.

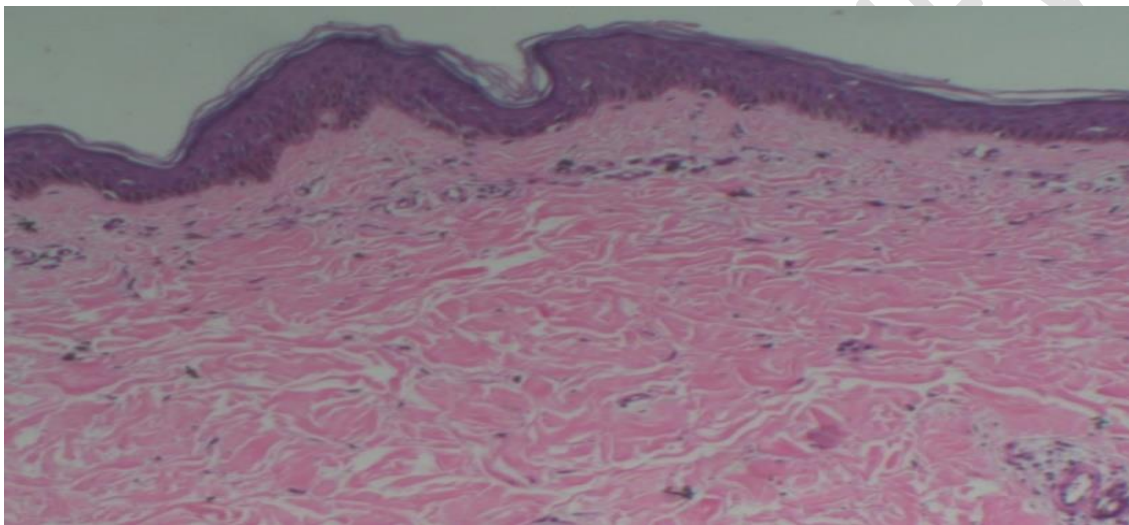


Figure 5. Repeat biopsy shows sparse superficial and mid perivascular and peri appendageal lymphocytic infiltrate with partial effacement of rete ridges.

DISCUSSION

Shrinivas et al presented a case of treated case of borderline tuberculoid Hansen's disease with single lesion with comedones over it but in that case, there was prolong history of coconut oil application [2].

Lahiri et al presented a case of borderline tuberculoid Hansen's disease with acneiform eruption due to topical corticosteroid but in this case, lesions of leprosy were spared [3].

Borderline tuberculoid Hansen's lesions are dry, scaly and indurated with decreased perspiration, sebum production and diminished hairs, so appearance

of comedones is usually not seen [4]. Sometime Acneiform eruption are seen in patients of reactions which are steroid induced.

It may be isotopic response in which occurrence of a new skin disorder at the site of another, unrelated, and already healed skin disease. It May be Locus minoris resistentiae which is defined as "a site of lessened resistance; an area, structure, organ offering little resistance to invasion by microorganisms and/or their toxins [5].

The potential of oral dapsone to treat acne vulgaris is well established, but the risks of serious side effects have made it an undesirable drug for use in the relatively healthy acne population. Topical formulation of dapsone has been approved by the FDA for the treatment of acne vulgaris. This might be the reason behind leprosy patient usually do not develop acne lesions even during puberty [6].

CONCLUSION

We reported this case due to unique and rare presentation of a Hansen' disease. In spite of searching on internet we could not find such de novo presentation of BTHD plaque with well-developed typical comedones over it.

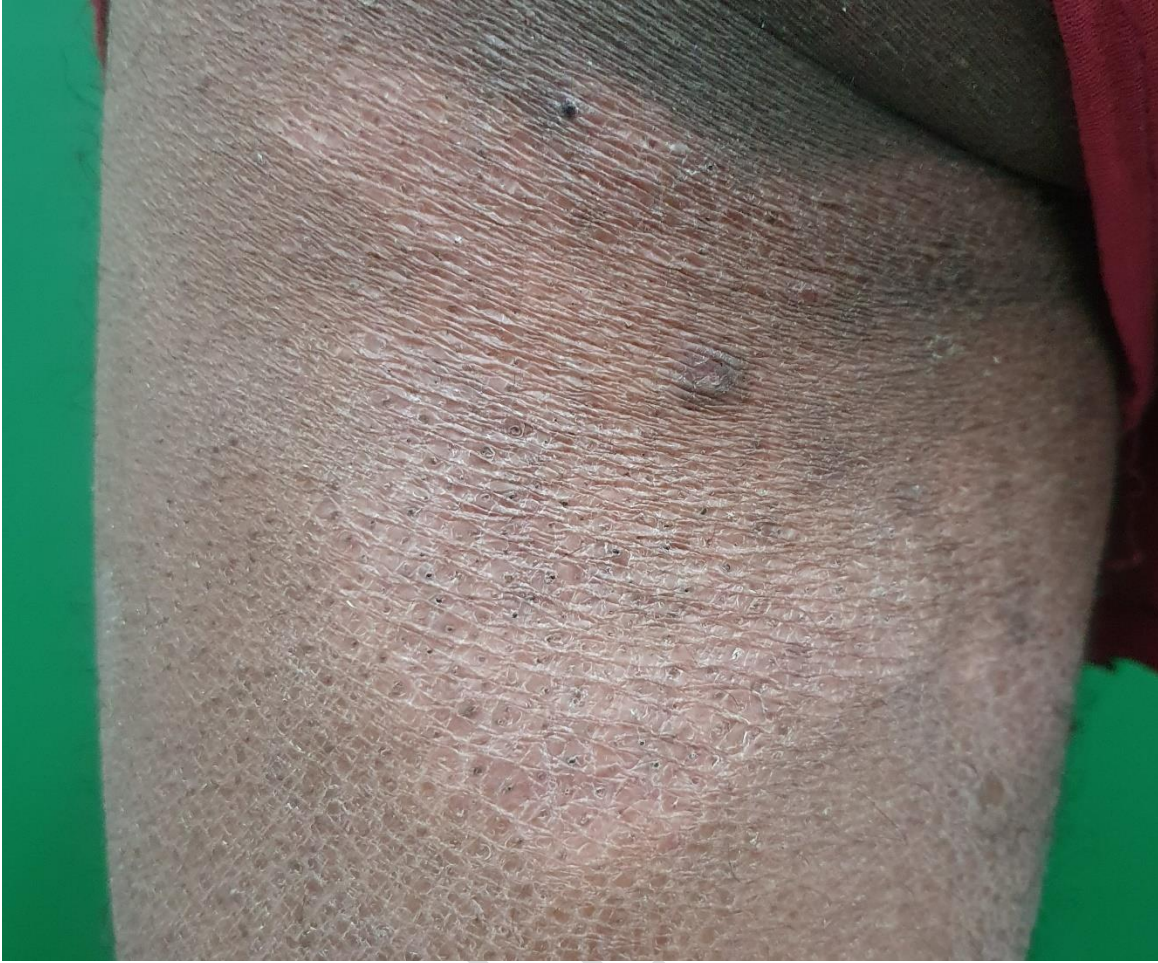

Figure 6: Plaque of left thigh showing resolution of lesion with comedones.

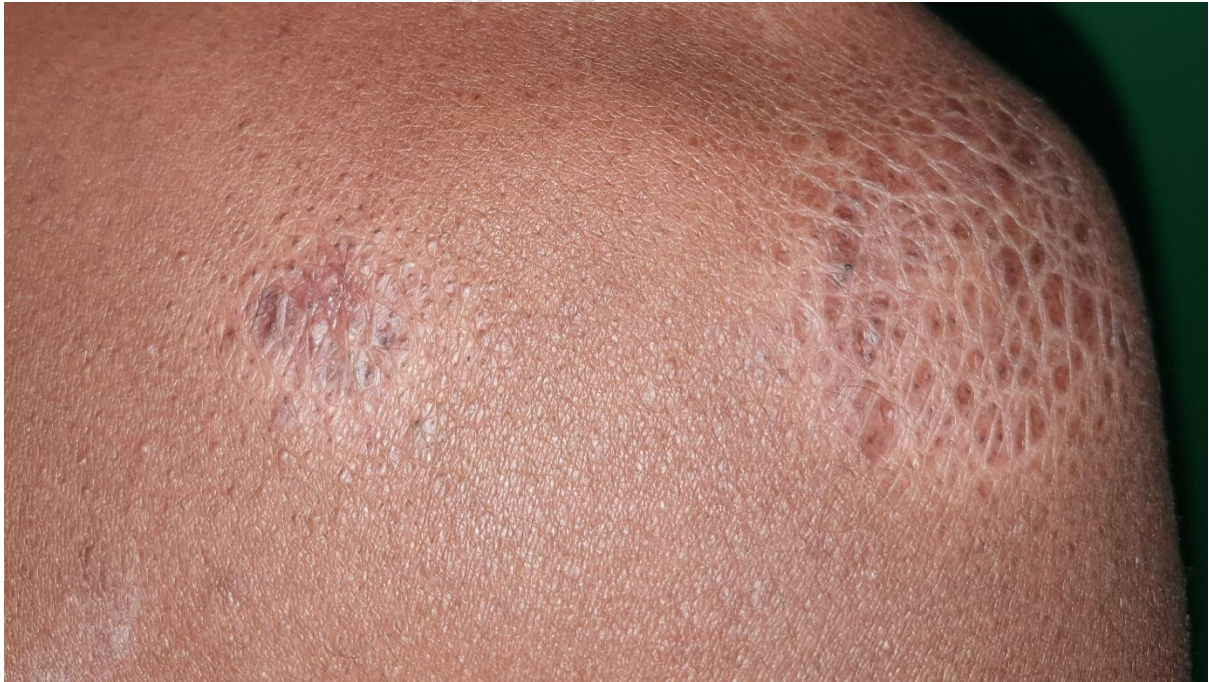

Figure 7: Shoulder plaques showing resolving phase with persistent comedones.

Consent

The patient provided written informed consent to publication of this case report and accompanying images.

Conflicts of Interest

The authors declare that they have no conflicts of interest.

Disclaimer (Artificial intelligence)

Option 1:

Author(s) hereby declare that NO generative AI technologies such as Large Language Models (ChatGPT, COPILOT, etc.) and text-to-image generators have been used during the writing or editing of this manuscript.

Option 2:

Author(s) hereby declare that generative AI technologies such as Large Language Models, etc. have been used during the writing or editing of manuscripts. This explanation will include the name, version, model, and source of the generative AI technology and as well as all input prompts provided to the generative AI technology

Details of the AI usage are given below:

- 1.
- 2.
- 3.

References

1. Kotteeswaran, G., Chacko, C. J., & Job, C. K. 1980. Skin adnexa in leprosy and their role in the dissemination of *M. leprae*. *Leprosy in India*, 52(4), 475–481.
2. Srinivas, C. R., Padhee, A., Balanchandran, C., Shenoy, S. D., Acharya, S., & Ramnarayan, K. 1988. Comedones induced by coconut oil in a borderline tuberculoid lesion. *International journal of leprosy and other mycobacterial diseases: official organ of the International Leprosy Association*, 56(3), 471–472.

3. Lahiri K, Malakar S. 2006. Steroid acne sparing Hansen's patches. *Indian J Dermatol*, 51:118-9.

4. Ridley, D. S., & Jopling, W. H. 1966. Classification of leprosy according to immunity. A five-group system. *International journal of leprosy and other mycobacterial diseases: official organ of the International Leprosy Association*, 34(3), 255–273.

5. Wolf, R., Wolf, D., Ruocco, E., Brunetti, G., & Ruocco, V. 2011. Wolf's isotopic response. *Clinics in dermatology*, 29(2), 237–240.

6. Searle, T., Al-Niaimi, F., & Ali, F. R. 2021. Dapsone for acne: Still in use after half a century!. *Journal of cosmetic dermatology*, 20(7), 2036–2039.

7. Pensler MS, Hristov AC, Aravind MS. Chronic annular plaques with new peripheral follicular plugging. *JAAD Case Reports*. 2024 Jul 1;49:25-7.

8. Lal NR. Papules: Localized. In *Atlas of Clinical Dermatology in Coloured Skin 2023* (pp. 76-99). CRC Press.

9. Sinha A, Natarajan S. Linear morhpea, nevus comedonicus, and lichen striatus in a 5-year-old girl. *Pediatric dermatology*. 2011 Jan 1;28(1).