

## Case report

### **preoperatively manifestations as univesicular mass like lesion and postoperatively as multivesicular lesion with multiple daughter cyst: a very rare case report**

#### **Abstract**

Pulmonary univesicular hydatid cyst and uncomplicated cysts with *Echinococcus granulose* and daughter cysts are very rare. A 58-year-old man presented to our center with cough, hemoptysis and right side chest wall pain. Chest x-ray and computerized tomography scan revealed a cystic like appearance mass in the hill of right lung. FOB and BAL was normal. With right side PL-thoracotomy cystic mass of lung was removed. Hundreds of 1to3 cm size daughter cysts and laminated membrane was discovered after opened the cystic mass. Pathologic examinations revealed the hydatid cysts with daughter cysts on the lung cystic mass. To best of our knowledge probably this is rare presentation of lung hydatid cyst as mass like and univesiculi cyst which full of daughter cyst.

**KEY WORDS:** Daughter cyst, lungs, univesicular hydatid cyst, cystic mass

## INTRODUCTION

Hydatid disease is caused by an infection with the cestode *Echinococcus granulosus*. Cystic echinococcosis is seen in some countries in words and is public health problems in endemic areas, such as South and Central America, the Middle East, Africa, Russia, China, Australia and New Zealand. and is endemic in Iran [1,2,3]. Adult worms mature in the intestine of dog (definitive host) and the eggs are released in the stool (4,5,6). Adult worms mature in the intestine of dog (definitive host) and the eggs are released in the stool (3,4,5). Animals like sheep get this disease by via ingestion of contaminated vegetables. Humans are accidental host, oncospheres hatch in the duodenum, penetrate the intestines and are carried via the bloodstream to various organs (3,4,5).it most often affects the liver and the lungs tissue [1,34,5]. Hydatid disease mostly affects the liver (75%) and the lungs tissue (15%), and occurs only 10% in others organ [2-6,7,8]. Pulmonary hydatid disease may be accompanied by complications including cyst rupture into the pleural space, lung mass, hemoptysis, suppuration (9,10,11,12,13). Patients may develop sudden onset of chest pain, cough, fever, and hemoptysis after a cyst ruptures, urticaria wheezing and anaphylaxis secondary bacterial infection. Infection resulting in difficulty in differentiation disease [2-4,7,8,9,13].

Hydatid disease should be in the differential diagnosis when a cystic lesion detected in an endemic area as bronchogenic cyst, lung carcinoma, sarcoma of the lung,metastasis , hematoma ,mesothelioma,granulomatouse lesions andpulmonary abscess[2-4,7,8,9,13,14,15]. Daughter cysts and calcifications are rarely seen in pulmonary hydatid cysts. (14,15). Chest imaging is the principal investigational modality for pulmonary hydatid cyst. computed tomography (CT), and magnetic resonance imaging (MRI) of the lungs are the various useful modalities in the diagnosis of thoracic hydatid cyst [7,8,9,10,11,12,13]. The treatment is surgery (1,6,10,12,13). The goal of surgical intervention includes removal of the entire cyst while preserving the lung parenchyma as much as possible and without allowing intra operative spillage [1,9,10,11,12]. The aim of this case report is for three interested causes, first is the unusual presentation as univesicular cyst in imaging preoperative and with multiple daughter cysts postoperative, second is the location of cyst which in the hill of lung and third is present as cystic mass lesion.

## CASE REPORT

A 58-year-old man was admitted to our referral hospital in pulmonology department with complaint of dry cough, milled hemoptysis, right side chest pain, night sweating and Low grade fever for three months. The symptoms in recent two weeks was sudden expectoration mild sputum with mixed with blood. In examination the respiratory sounds were normal but crackles were present in right hemi thoraces. Chest roentgenogram and computed tomography (CT scan) demonstrated cystic mass like lesion in the right hill of lung ( $14 \times 12 \times 11$  cm), (Fig 1,2,3,4). FOB performed show small compression on the right upper lobe, others were normal. BAL was normal in pathology evaluation. Patient refereed to thoracic surgery ward for excision of that lesion. After general anesthesia with one lung ventilation, five intercostal space was opened in right up position with muscle saving procedure. After pneumolysis the cystic mass in the hill of lung was walling of with wet sponge in normal saline for prevention of spillage cyst content of cystic mass when rupture occurs, because in endemic area as Iran all cystic masses should be in **diffrencited** from hydatid disease. The cystic mass was resected with safe margin as wedge resection. After chest - tube insertion and closed of chest wall the cystic mass was operated. After opened the mass there was ruptured laminated membrane with more than hundreds of 1 to3cm daughter cysts in cavity (Fig 5,6,7). Ultrasonography of abdomen was normal for cystic or mass lesions. **Albendassol** 800 mg prescribe for three cores of 28 days with 14 day interwall. The patient discharged on the fifth day postoperatively without any complications. As a result, the pathologic examinations of ruptured laminated membranes and daughter cysts confirmed a hydatid cyst. On 6 and 12 month follow up, patient condition is well.

## DISCUSSION

Hydatid cysts disease is still a significant health problem in certain countries such as South and Central America, the Middle East, Africa, Russia, China, Australia and New Zealand. and Central Europe occur in immigrants from endemic areas and in this areas hydatid cysts are endemic [1-3,4,5,9]. In Iran hydatid cysts are endemic (1,14,15).

Hydatid disease mostly affects the liver (75%) and the lungs tissue (15%), and occurs only 10% in others organ [2,4,5,6,7,8]. Pulmonary hydatid cysts are usually asymptomatic while symptoms may appear with increasing size over a period of time or in cases that cysts are in the central portion of lung or other complications (3,9,10,11,12) .as our case. Hydatid disease is caused by an infection with the *Echinococcus granulosus* in endemic area such as Iran [1,3,7,11,12]. The hydatid cysts may remain asymptomatic for a long time. As they enlarge, the cysts may rupture and patients complain of cough, expectoration of membranes, hemoptysis, and thoracic pain in cases of pulmonary cysts (3,7,11,12). Adult worms mature in the intestine of definitive host as dog and the eggs are defecated with stool (3,4,5,6). Animals like sheep get this disease by via ingestion of contaminated vegetables and water. Humans are accidentally infected. Oncospheres hatch in the duodenum mucosa of sheeps and penetrate the intestines and are carried via the bloodstream to various organs as liver, lung and all organs (3,4,5,6,7). Daughter cysts can also sporadically or very rarely be seen in pulmonary hydatid cysts (3,4,7,9,11,12). The germinative layer secretes hydatid fluid and generates brood capsule, If the inner layer and the brood capsules spitted up, daughter cysts can be produced. (13). Due to early presentation of symptoms and treatment,in PHC there in enough time for forming the daughter **cystshence** the occurrences of daughter cysts in the pulmonary hydatid cysts are uncommon(14). We present one case with a cystic mass lesion and univesicular on CT-scan in the hill of right lung before surgery with hundreds of daughter cysts with laminated membrane postoperative, like such case rarely reported in the literature (14).

univesicular cysts may contain no daughter cysts, (14,15) and are called unilocular and cyst with daughter cysts are called multivesicular. in the literature [15] Chest X-ray and CY-scan can show cyst mas lesion as a round opacity in a hemi thorax (14,15). CT scan can detect pulmonary hydatosis with or without daughter cysts (14,15) but CT-scan cannot show small sizes of daughter cysts as our case before surgery. Repeated mechanical trauma such as heart beats and respiratory motions and separation of some parts of laminated membrane from of pericyst layer into the cyst cavity and formation of daughter cysts, Daughter cysts may develop directly from the end cyst, resulting in multisystem or multivesicular pulmonary hydatid cysts, [13,14,15,18].In this our case, daughter cysts were present in the mass like cystic lesion . Daughter cysts rarely can be seen in pulmonary hydatid cysts. The hydatid fluid and brood capsule secretes by germinative layer. Daughter cysts can be produced by spitted up germinative and brood capsules (21). Because of early presentation of symptoms and early treatment of pulmonary hydatid cyst there are no enough time for forming the daughter cysts., hence the occurrences of daughter cysts in the pulmonary hydatid cysts are very uncommon (21). We present one case of intact lung hydatid cysts of lung in CT-scan without any daughter cysts but postoperative there was more than hundred daughter cysts rarely reported in the literature. cysts without daughter cysts are called univesicular and those with daughter cysts are called multivesicular. CT scan can show pulmonary hydatid cysts with or without daughter cysts [21) but in majority of cysts due to very small sizes of daughter cysts CT -scan not detected before surgery (21) as our case. There are two theories for formation

of daughter cysts (21): Repeated mechanical trauma such of pulsation of heart beats and respiratory motions and opening of bronchioles into the cyst cavity (21). In our case, daughter cysts were not present in the hydatid cyst but it presents in the mass cystic lesion postoperative with cut the mass

It is required to Differential diagnosis from lung masses which most commonly present with malaise, weight loss, cough especially in endemic area as Iran (14).

*hydatid cysts of lung* should be always kept in the differential diagnosis when a cystic lesion is detected in a patient who has come from an endemic area. Differential diagnosis for pulmonary HCs can be listed as bronchogenic cyst, lung carcinoma, sarcoma of the lung, metastasis (when cysts are multiple), hematoma, mesothelioma, granuloma, and lung abscess (16,17). CT-scan and MRI can help cysts from masses in some patient but not definitive diagnosis not possible (4,5,7,14). Transthoracic needle biopsy is dangerous or contraindicated in endemic area in such as our case, because can ruptured cyst and produce anaphylaxis and dissemination of cysts content (3,4,7,11).

Surgical treatment. For patients who are cardiovascular stable and able to undergo major operation, Surgery is the treatment of choice because parasite can be excised completely and the patient will be cured (1,2,3,10,11,14). Our surgical options for lung cysts include wedge resection, evacuation, bronchial opening closure with precystectomy, rarely lobectomy, and capitonnage for obliteration of remnant cavity (1,3,7,11,12). During surgery it is important to prevent spillage of cyst contents intraoperative for dissemination, allergic reactions and recurrence (1,3,7,11,12,14). In our patient we don't use any sporicidal agents in pulmonary hydatid cysts. Medical therapy with Albendazole is Used in patients which cannot tolerated undergrowing surgery or in disseminated disease and when there is intraoperative spillage of hydatid fluid (17,18,19,20), After surgery we **priscibe Albendasol** 800 mg in three cores of 28 days with 14 days' interval.

**Conclusion:** in endemic area all cystic mass lesion of lung should be differenced from hydatid cysts. MRI and CT -scan help for diagnosis but FOB can help for diagnosis of lung mass or some time ca see the priciest. The only way for definitive diagnosis is surgery as VATS or thoracotomy

### **Compliance with ethical standards**

#### **Statement of ethical approval**

This study was approved by **ethic comity** of arya hospital and Inflammatory Lung Diseases Research Center of Razi hospital, Guilan University of Medical Sciences, Rasht, Iran E-mail [=XXX@XXXhospital.ir](mailto:XXX@XXXhospital.ir)

#### **Statement of informed consent**

Informed consent was obtained from all individual participants included in the study.

## **REFERENCES**

1. Aghajanzadeh M, Safarpour F, Amani H, Alavi A. One-stage procedure for lung and liver hydatid cysts. Asian CardiovascThorac Ann. 2008; 16: 392-395.

2. Sarkar M, Pathania R, Jhobta A, Thakur BR, Chopra R. Cystic pulmonary hydatidosis, Lung India. 2016; 33: 179-191.

3-Ehsan Hajipour Jafroudi , Manouchehr Aghajanzadeh , Ali Alavi Foumani , Azita Tangestaninejad , Yousha Pourahmadi , Mahsa Mousazadeh, Pulmonary hydatid cyst mimicking pneumonia, lung mass, pneumothorax, pleural effusion, pulmonary abscess, and pyopneumothorax International Journal of Life Sciences Vol. 10 No. 4 , 2022-12-31

4. Havlucu Y, Ozdemir L, Sahin E. Multiple cystic echinococcosis mimicking metastatic malignancy. Respiratory Med. 2010; 3: 132- 134.

5. Kuzucu A, Ulutas H, RehaCelik M, Yekeler E. Hydatid cysts of the lung: Lesion size in relation to clinical presentation and therapeutic approach. Surg Today. 2014; 44: 131-136.

6. Polat P, Kantarci M, Alper F, Suma S, Koruyucu MB, Okur A. Hydatid disease from head to toe. Radiographics. 2003; 23: 475-494.

7. Asgary MR, Aghajanzadeh M, Hemmati H, Safarpour F, Alavi A, Amani H. The clinical finding, diagnosis and outcome of patients with complicated lung hydatid cysts. Int J Med Res Health Sci. 2016; 5: 293- 297.

8. Hasdıraz L, Onal O, Oguzkaya F. Bilateral staged thoracotomy for multiple lung hydatidosis J Cardiothoracic Surg. 2013; 8: 121.

9. Trilok C, Avdshesh B, Aanchal T. Hydatid lung disease presented with multiple pulmonary nodules. J Health Res. 2016; 3: 137-140.

10-Saviz Pejhan , Mohammad Reza Lashakri Zadeh , Mojtaba Javaherzadeh , Mohammad Behgam,Shadmehr , Mehrdad Arab , Abolghasem Daneshvar Kakhki , Roya Farzanegan ,Azizollah Abbasi,Dezfouli ,Surgical Treatment of Complicated Pulmonary Hydatid Cyst, Tanaffos (2007) 6(1), 19-22

11Mohammad Reza Asgary, Manouchehr Aghajanzadeh, Hosein Hemmati1, F. Safarpour1, Ali Alaviand Hosein Amani ,The clinical finding, diagnosis and outcome of patients with complicated lung hydatid cysts, *Int J Med Res Health Sci.* 2016, 5(8):293-297

12.Manouchehr Aghajanzadeh1, Ali Alavi, Alirza Jafarnegad, Azita Tangestaninejad, PedramTalebi, Rasool Hassanzadeh, and Mahdi Pursafar ,Multiple and Bilaterally Pulmonary Hydatid Cystic Mimicking Metastatic Lesions ,Vol. 10 No. 4 (2022): International Journal of Life Sciences

13. Bonfrate L, Giuliante F, Palasciano G, Lamont JT, Portincasa P. Unexpected discovery of massive liver echinococcosis.A clinical, morphological, and functional diagnosis. Ann Hepatol. 2013;12:634–41.

14-Mohsen Sokouti, Babak Sokouti, Behrooz Shokouhi, and Mohammad Hossein Rahimi-Rad Multi- vesicular pulmonary hydatid cyst, the potent underestimated factor in the formation of daughter cysts of pulmonary hydatid disease .Lung India. 2015 Jul-Aug; 32(4): 375–377.

15-Saidi F. 1st ed. Philadelphia: WB Saunders; 1976. Surgery of Hydatid Disease; pp. 156–281.

16-Pedrosa I, Saiz A, Arrazola J, Ferreiros J, Pedrosa CS (2000) Hydatid disease: radiologic and pathologic features and complications. Radiographics 20:795–817

17-Morar R, Feldman C (2003) Pulmonary echinococcosis. Eur Respir J 21:1069–1077

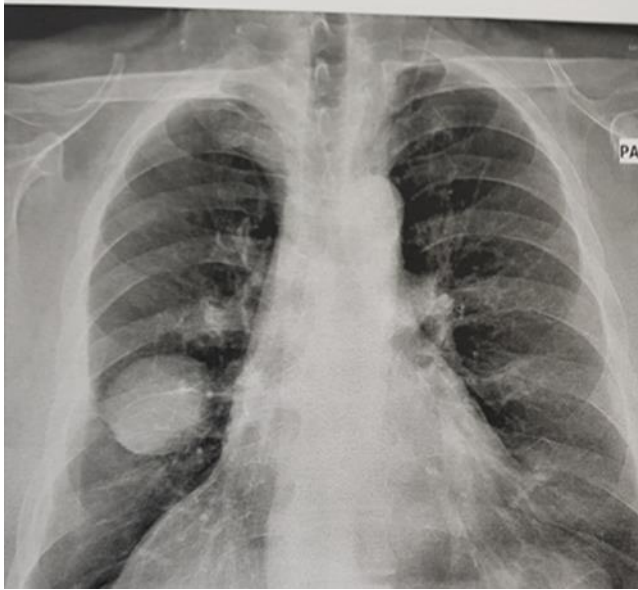
18-Kilani T, El Hammami S. Pulmonary hydatid and other lung parasitic infections. Curr Opin Pulm Med 2002; 8: 218– 223.

19. Filice C, Brunetti E. Use of PAIR in human cystic echinococcosis. Acta Trop 1997; 64: 95– 107.

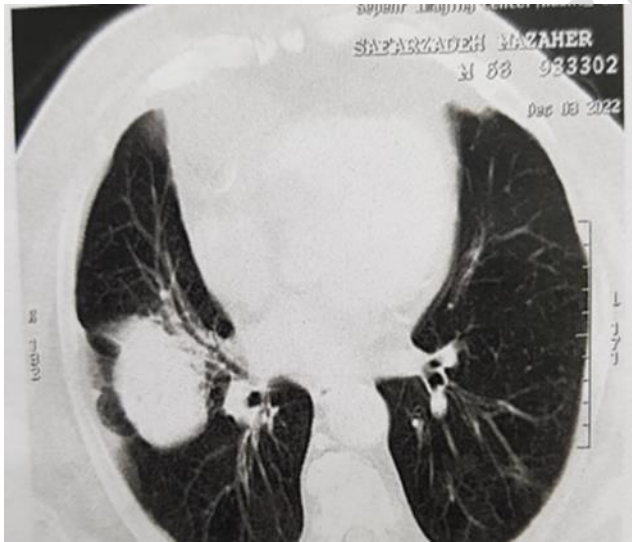
20. Akhan O, Ozmen MN, Dincer A, Gocmen A, Kalyoncu F. Percutaneous treatment of pulmonary hydatid cysts. *Cardiovasc Intervent Radiol* 1994; 17: 271–275.

21-Mohsen Sokouti, Babak Sokouti,<sup>1</sup> Behrooz Shokouhi,<sup>2</sup> and Mohammad Hossein Rahimi-Rad<sup>3</sup> Multi- vesicular pulmonary hydatid cyst, the potent underestimated factor in the formation of daughter cysts of pulmonary hydatid disease *Lung India*. 2015 Jul-Aug; 32(4): 375–377

**Fig 1:** CXR show a round cystic mass like lesion in RL lobe

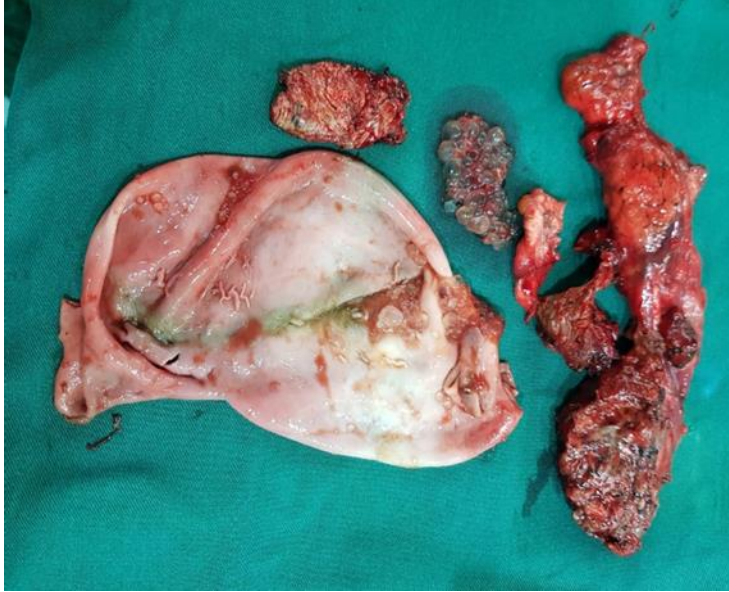

**Fig 2:** CT-**scab** show mass like lesion in the RL lobe

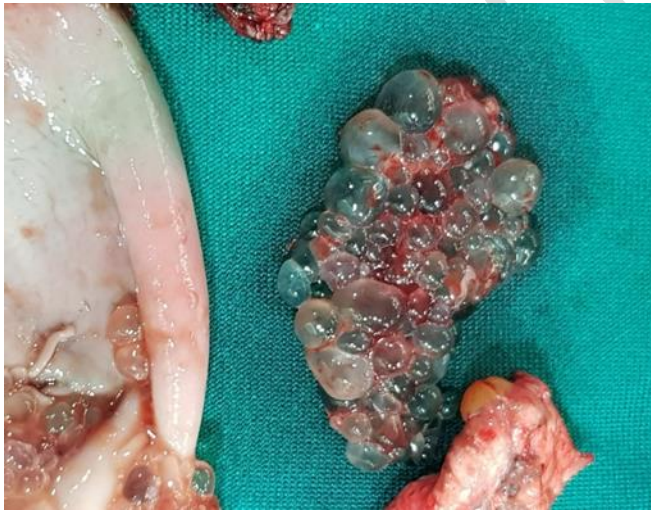


**Fig 3:** CT-**scab** show mass like lesion in the RL lobe

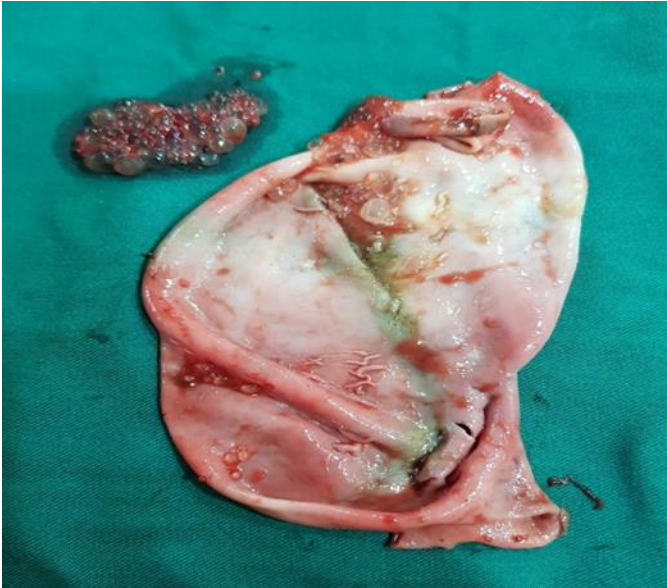




**Fig 6:** show hydatid cyst content with daughter cyst



**Fig 7:** show laminated membrane and daughter cysts



UNDER PEER REVIEW