

Femur length as a predictor of femur head diameter in Nigerians

ABSTRACT

Introduction: The femur forms the skeleton of the thigh and its proximal segment is a component of the hip joint which is the largest mobile synovial joint of the human body. Although, the hip joint has a very remarkable stability, it may become dislocated with accompanying fracture of the femoral head and neck sequel to considerable trauma. Definitive management of fracture neck of the femur in the elderly is surgical operation at which the fractured proximal end of the femur is replaced with an inert metallic implant.

Methodology: This study set to establish the length of the femur, diameter of the femur head and the relationship between these two parameters in Nigerians (Black Africans) using direct bone measurement technique.

Results: The sample size (human femur) was 266 with 51.1% (136) being right and 48.9% (130) being left. The respective mean length of the right, left and that of overall was similar (42.89 ± 2.96 ; 42.78 ± 2.86 2.83 ± 2.90) cm. The median length of the femur irrespective of the side was the same (43.00 cm) and the range was 37-49 cm.

The diameter of the head of the femur along the sagittal (supero-inferior) plane ranged between 3.56 to 5.09 on the right, 3.49 to 4.88 on the left and 3.49 to 5.09 cm overall. The mean supero-inferior diameters were also very similar (Right- 4.28 ± 0.30 ; Left- 4.26 ± 0.36 and Overall- 4.27 ± 0.33 cm). The median supero-inferior diameter was 4.31 cm. The mean horizontal (medio-lateral) diameter was not significantly different along-side (Right- 4.48 ± 0.33 ; Left- 4.46 ± 0.33 and Overall- 4.47 ± 0.33 cm). Also the median horizontal diameters were very similar ie 4.46, 4.48 and 4.47 cm respectively. The medio-lateral diameter ranged from 3.67 to 5.37 cm and no side difference. The average diameters (i.e. supero-inferior + medio-lateral/2) of the femur were similar (Right- 4.38 ± 0.30 ; Left- 4.36 ± 0.33 and Overall- 4.37 ± 0.32 cm). The median value of the average diameter was similar side-wise (Right-4.46, Left-4.48, Overall-4.47 cm). The average diameter of the femur ranged between 3.62 to 5.17 cm.

There was no significant difference between the mean area of the femur head computed from the two diameters.

The ratio of the head diameter to the bone length was the same irrespective of the diameter or the side of the femur (0.1 ± 0.01) also the median value was 0.1 cm. The correlation coefficient (r), of the ratio of the head diameter to bone length was positive for both the right and left side.

Conclusion: A linear relationship exists between the head diameter and the length of the femur. In essence the wider the diameter of the head, the longer the length of the femur.

Key words- Femur length, femur head diameter, Femur head diameter to length constant.

1. INTRODUCTION

The femur is the longest and heaviest bone that forms the skeleton of the thigh and largely responsible for bearing and transmission of the body weight through its articulation by means of its head with the acetabulum of the pelvic bone resulting in the formation of the hip joint. It accounts for about 25 % of the height of an individual [1].

The formation of the femur is largely by endochondral ossification and its initial stage is by intramembranous ossification. In the development of the femur, the earliest ossification centre is that of the shaft which is at the 8th week of intrauterine life. The epiphyses of the proximal end of the femur fuse with the diaphysis by age of 18 years while the epiphysis of the distal end fuses with the shaft at age 20. Thus after the 20th birthday, the femur can no longer increase in length [2,3].

Fracture of its shaft (diaphysis) is usually due to high impact trauma especially from vehicular accidents and this could be managed conservatively or through surgical procedures such as intra medullary nailing or insertion of plate and screw[4]. As one advances in age and especially in women due to hormonal changes, there is progressive demineralization resulting in osteoporosis especially of its neck. At this stage, a slight trauma which hitherto would have been uneventful may result in fracture of the femoral neck which in clinical parlance is referred to as fracture neck of the femur. However, in severe trauma especially in younger age group, fracture neck of the femur may occur with hip dislocation[28-30].

There is no conservative management for the displaced fracture of the neck of the femur in the elderly rather it is managed surgically either by hemiarthroplasty (removal and replacement of the head of the femur with a metallic non-reactive implant) or total hip arthroplasty in which in addition, the acetabulum is removed and replaced with an inert implant[5-12]. Several studies have documented inter-racial differences in the geometry of the proximal femur. Such studies noted significant differences in the parameters amongst Europeans, Americans and Asians [13-16].

The overall height of an individual, body built, gender, vocation, nutritional status and race are factors that bring about variabilities in the length and size of the femur and its proximal end. Thus the implants are manufactured in different sizes in order to accommodate the variabilities in the size and length of the proximal end.

For any patient being planned for hip replacement surgery, the size of the implant has to be determined preoperatively. This is usually done by taking certain measurements on plain radiograph or computed tomographic film of the hip. While this has been found to be a very reliable assessment mode, its exactness i.e. accuracy can and is only confirmed at surgery when the hip is opened up and the fractured proximal end is removed.

Normally, the reference points for the measurement of the length of the femur are the tip of the greater trochanter and the lower border of the lateral epicondyle. These two reference points are easily palpable in the living human body. The site of fracture in the proximal end of the femur is at the neck of the femur thus it is still possible to determine the length of the femur from the plain radiograph of a patient with fracture neck of femur and fracture-dislocation of the hip joint.

This anthropometric study set out to derive a numerical constant that could be used to obtain the diameter of the appropriate hip prosthesis (implant) from the length of the femur either directly from the patient or from the plain radiograph of the thigh. This will reduce the technical glitches of hip replacement surgical operations which will translate to reduction in complications, morbidity and mortality. This numerical constant would be obtained from a correlation between the diameter of the head of the femur measured at two perpendicular axes and the length of the femur using the previously stated reference points.

2. MATERIALS AND METHODS

Adult femur bones obtained through maceration of dissected cadavers (Nigerians) over several years in the Department of Anatomy, College of Medicine, University of Ibadan, Nigeria; were used for the study. Bones with congenital anomaly, evidence of healed fracture and osteoporotic changes of any of the landmarks were excluded from the study.

On each bone, the following parameters were measured:-

(a) Bone length- this was measured with the bone supine and against a fixed graduated stainless meter rule.

of the
border
meter

(b)
the

3).
Each

(c) An
weight
The
length

the
ratio
The

t-test



The summit (tip) of the greater trochanter was at the zero mark meter rule and by means of another ruler placed at the lower of the lateral epicondyle, its intersection with the stainless rule was read off as the femur length in centimetres (cm) (Figures 1&2).

Diameters of the Head:- by means of a digital Vernier caliper, supero-inferior (vertical) and the medio-lateral (horizontal) diameters were measured respectively along the sagittal and transverse plane with the fovea lying along the planes (Figure

parameter was measured twice and the average of the two readings (though very close) was recorded

electronic digital weighing scale was used to measure the of each of bones.

following parameters were computed from the values of the and the diameters.-: (i) Area of the head {supero-inferior} $\{A = \pi r^2, \text{ where } r(\text{radius}) = \text{diameter}/2\}$; (ii) Area of head {medio-lateral}; (iii) Average area of the head using the average diameter; (iv) the supero-inferior diameter: length and (v) the medio-lateral diameter: length ratio.

data was expressed as percentages, means plus standard deviation, median and range. Significance of the difference between right and left was determined by means of the Student and $P \leq 0.05$.

Summit of the greater
trochanter

Fig 1: Measurement of the length of the femur (Right). (©rsa2024)

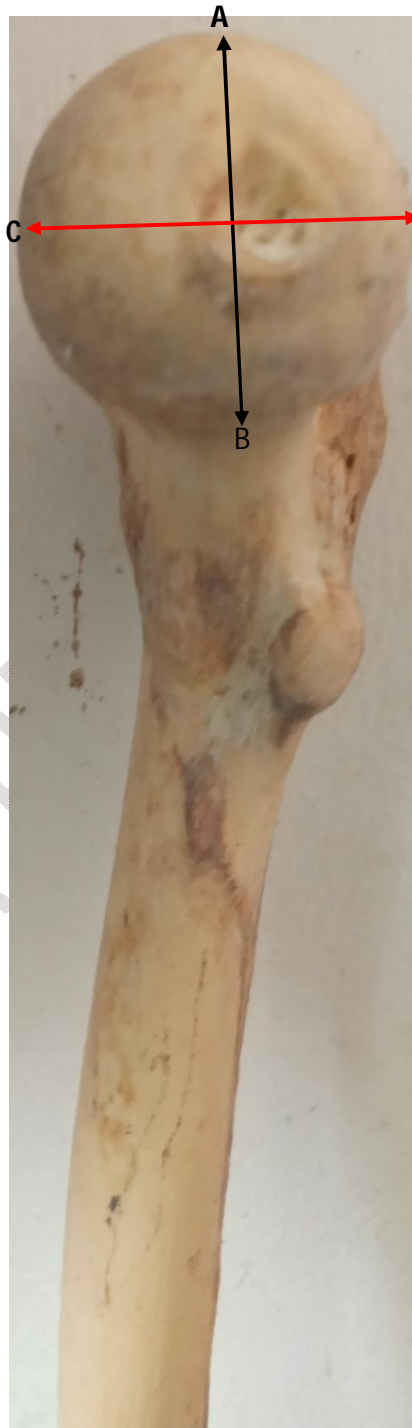

Fig 2: Left Femur (©rsa2024) Fig 3: Head of the femur- (©rsa2024)

**A-B is Supero-inferior (vertical) diameter
C-D is Medio-lateral (horizontal) diameter.**

UNDER PEER REVIEW

3. RESULTS

Two hundred and sixty six femur bones that met the inclusion criteria comprising of 136(51.1%) right and 130(48.9%) left were used for the study. The respective mean length of the right, left and that of overall was similar (42.89 ± 2.96 ; 42.78 ± 2.86 & 42.83 ± 2.90) cm. The median length of the femur irrespective of the side was the same (43.00 cm). While the shortest femur irrespective of the side was 37cm and the longest was about 49 cm.

The diameter of the head of the femur along the sagittal (supero-inferior) plane ranged between 3.56 to 5.09 on the right, 3.49 to 4.88 on the left and 3.49 to 5.09 cm overall. The mean supero-inferior diameters (S-ID) were also very similar (Right- 4.28 ± 0.30 ; Left- 4.26 ± 0.36 and Overall- 4.27 ± 0.33 cm). The median supero-inferior diameter was 4.31 cm. The mean horizontal (medio-lateral) diameter was not significantly different along-side (Right- 4.48 ± 0.33 ; Left- 4.46 ± 0.33 and Overall- 4.47 ± 0.33 cm). Also the median horizontal diameters were very similar ie 4.46, 4.48 and 4.47 cm respectively. The medio-lateral diameter (M-LD) ranged from 3.67 to 5.37 cm and no side difference. The average diameters (i.e. supero-inferior + medio-lateral/2) of the femur were similar (Right- 4.38 ± 0.30 ; Left- 4.36 ± 0.33 and Overall- 4.37 ± 0.32 cm). The median value of the average diameter was similar side-wise (Right-4.46, Left-4.48, Overall-4.47 cm). The average diameter of the femur ranged between 3.62 to 5.17 cm. The mean area of the head of the femur computed from the horizontal (medio-lateral) diameter was slightly but insignificantly higher than the one derived from the vertical (supero-inferior) diameter- {Right- 15.82 ± 2.30 ; Left- 15.71 ± 2.30 ; Overall- 15.76 ± 2.29 vs: Right- 14.47 ± 2.02 ; Left- 14.32 ± 2.36 ; Overall- 14.40 ± 2.18 cm² respectively}. The range of the S-ID derived area was 9.96-20.35 on the right and 9.57-20.35cm² on the left while those of the M-LD derived area were 10.75-22.65 (Right) and 10.58-20.85 cm² (Left). The respective median area was S-ID (Right 14.56, Left 14.66 cm²) and M-LD (Right 15.59, Left 15.77 cm²). As expected, using the average diameter to compute the area of the head of the femur produced values in between those of the supero-inferior diameter (S-ID) and medio-lateral diameter (M-LD).

The ratio of the head diameter to the bone length was the same irrespective of the diameter or the side of the femur (0.1 ± 0.01) also the median value was 0.1 cm while the range was 0.08-0.12. The correlation coefficient (r), of the ratio of the head diameter was positive for both the right and left side. This implied a linear relationship between the head diameter and the length of the femur. In essence the wider the diameter of the head, the longer the length of the femur. Another computed constant is the ratio of the area of the femoral head to the length of the femur. A constant factor of 0.34 ± 0.04 with a median of 0.33 when the area was based on S-ID and 0.37 ± 0.04 with the M-LD being the determinant of the area.

Plotting the diameter of the head of the femur against the length of the femur revealed a linear relationship between the two parameters for both sides as well as the supero-inferior and medio-lateral diameters (Figures 4&5).

The right femur weighed 390 ± 90 grammes with the median weight being 400 g and range being 200 to 600 g. The respective values for the left femur are 380 ± 90 ; 400; and 250 to 600 grammes (Table 1)

TABLE 1: DIRECT AND DERIVED VALUES OF THE VARIOUS PARAMTERS

PARAMETER	Mean value			Range			Median value		
	Right (N=136)	Left (N=130)	Overall (N=266)	Right	Left	Overall	Right	Left	Overall
Length (cm)	42.89 \pm 2.96	42.78 \pm 2.86	42.83 \pm 2.90	37.50 --- 48.40	37.20 --- 48.50	37.20 --- 48.50	43.00	43.10	43.00
Supero-inferior Diameter(cm)	4.28 \pm 0.30	4.26 \pm 0.36	4.27 \pm 0.33	3.56 --- 5.09	3.49 --- 4.88	3.49 --- 5.09	4.31	4.32	4.31
Medio-lateral Diameter(cm)	4.48 \pm 0.33	4.46 \pm 0.33	4.47 \pm 0.33	3.70 --- 5.37	3.67 --- 5.15	3.67 --- 5.37	4.46	4.48	4.47
Average Diameter (cm)	4.38 \pm 0.30	4.36 \pm 0.33	4.37 \pm 0.32	3.62 --- 5.17	3.62 --- 4.98	3.62 --- 5.17	4.42	4.39	4.40
Area 1-{S-I D} (cm²)	14.47 \pm 2.02	14.32 \pm 2.36	14.40 \pm 2.18	9.96 --- 20.35	9.57 --- 18.71	9.57 --- 20.35	14.56	14.66	14.59
Area 2- {M-L D} (cm²)	15.82 \pm 2.30	15.71 \pm 2.30	15.76 \pm 2.29	10.75 --- 22.65	10.58 --- 20.83	10.58 --- 22.65	15.59	15.77	15.69
Area3- {Av.diameter}(cm²)	15.14 \pm 2.09	15.01 \pm 2.25	15.08 \pm 2.16	10.35 --- 21.00	10.30 --- 19.79	10.30 --- 21.00	15.31	15.14	15.21
Supero-inferior diameter: Length Ratio	0.1 \pm 0.01	0.1 \pm 0.01	0.1 \pm 0.01	0.09 --- 0.11	0.08 --- 0.11	0.08 --- 0.11	0.10	0.10	0.10
Correlation coefficient	0.59	0.63							
Medio-lateral diameter: Length Ratio	0.1 \pm 0.01	0.1 \pm 0.01	0.1 \pm 0.01	0.09 --- 0.12	0.09 --- 0.12	0.09 --- 0.12	0.10	0.10	0.10
Correlation coefficient	0.58	0.69							
Average diameter: Length Ratio	0.1 \pm 0.01	0.1 \pm 0.01	0.1 \pm 0.01	0.09 --- 0.11	0.09 --- 0.12	0.09 --- 0.12	0.10	0.10	0.10
Correlation coefficient (r)	0.6	0.68							
Area 1 :Length Ratio	0.34 \pm 0.04	0.34 \pm 0.04	0.34 \pm 0.04	0.26 --- 0.42	0.22 --- 0.41	0.22 --- 0.42	0.33	0.33	0.33
Area 2 :Length Ratio	0.37 \pm 0.04	0.37 \pm 0.04	0.37 \pm 0.04	0.28 --- 0.50	0.26 --- 0.44	0.26 --- 0.50	0.37	0.37	0.37
Femur Weight (g)	390 \pm 90	380 \pm 90	390 \pm 90	200 ---	250 ---	250 ---	400	400	400

Foot Note:- Area {S-I D} was derived from the supero-inferior diameter. Area{M-L D} was derived from the medio-lateral diameter. Area{Av. diameter) was derived from the average diameter. The ratios were derived by dividing the respective diameter by the femur length. Area 1 is supero-inferior diameter area while Area 2 is medio-lateral diameter area.

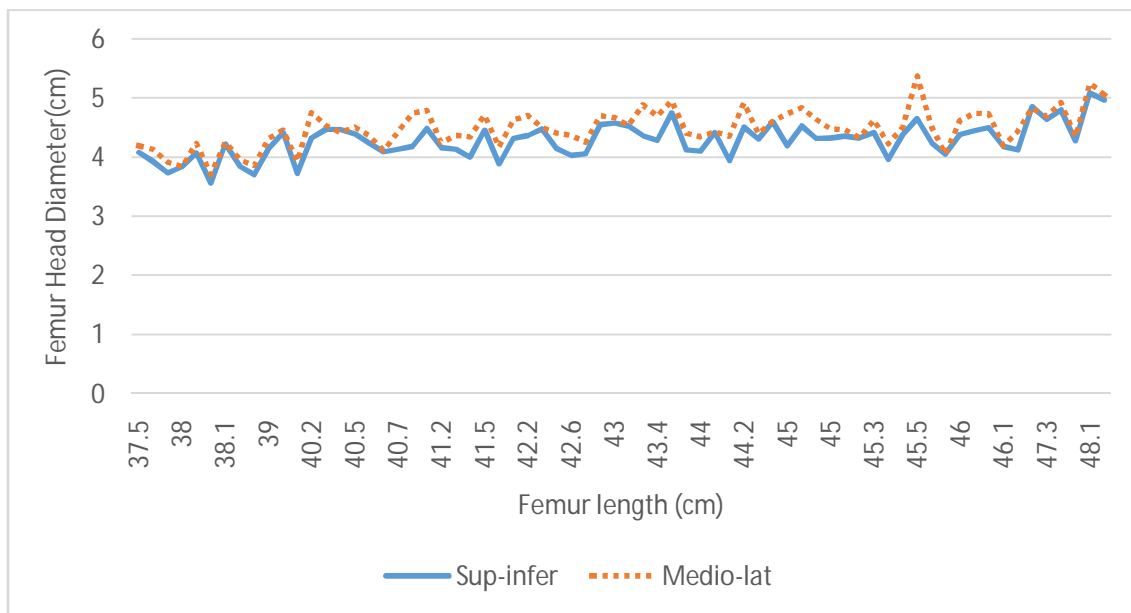


Figure 4: A plot of the femur head diameter against the femur length to demonstrate the relationship between the two parameters.-The longer the bone length, the greater the head diameter (Right Femur)

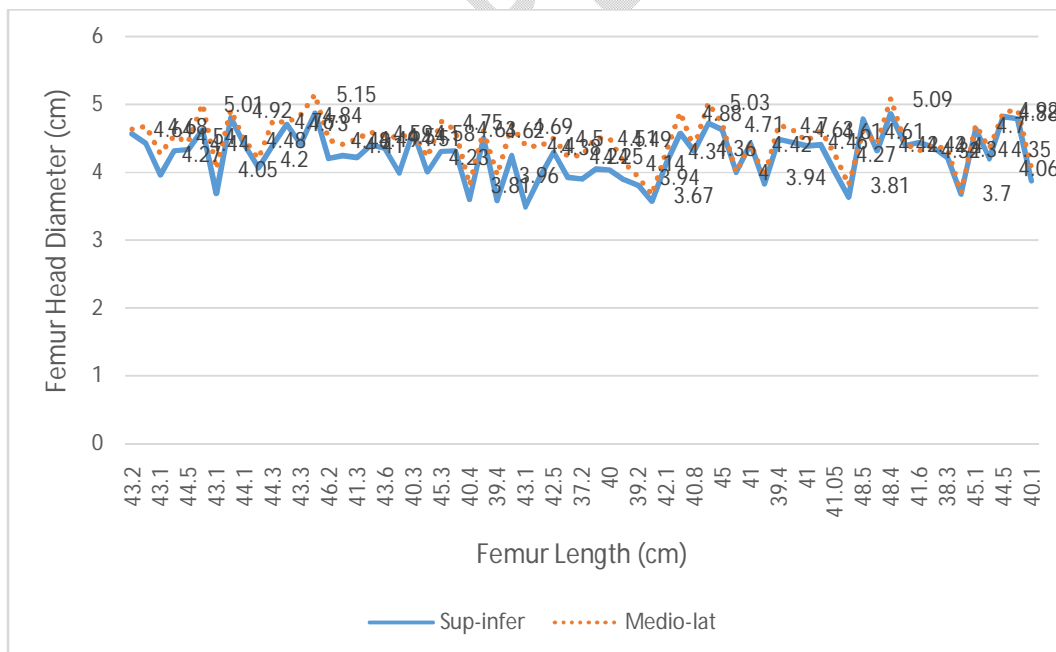


Figure 5: A plot of the femur head diameter against the femur length to demonstrate the relationship between the two parameters.-The longer the bone length, the greater the head diameter (Left Femur)

4. DISCUSSION

Femur length

Different studies using different methods have documented different values for the mean length of the femur and its range. Kira *et al.*, using computed tomography imaging of cadavers and measuring the length of the femur from the upper border of the head to the lower border of the condyles gave the mean length as 42.74 ± 2.94 and range as 36.06-51.11 cm [17]. Also, in that study, no significant difference was observed between the length of the right femur and that of the left. In another human direct measurement study done amongst Zambian population (southern Africa) the mean femur length was 44.2 (male) and 42.3 cm (female). Also, the femur length constitutes 25% of the individual height [18]. Using the same reference points to measure the femur length, Mossa *et al* (2021) obtained 42.38 ± 19.02 cm as mean and a range of 38.6-47.1 cm for male while the respective female values were: 38.72 ± 40.15 and 30.3-45.2 cm. This was a direct bone measurement study [19]. Analyses of 1189 Asian and Caucasian segmented three-dimensional computed tomographic data sets of femurs, revealed an overall femur length of 42.0 ± 3.1 cm and the range being 32.9-50.8 cm. The respective values for the Asians were 39.8 ± 2.7 cm; (32.9-46.7 cm) and Caucasians: 43.0 ± 2.8 cm; (35.3-50.8 cm). The Caucasian femur was found to be significantly longer than of the Asian femur. The femur length was measured from the tip of the greater trochanter to the distal intercondylar notch [20]. In another three dimensional Computed tomography analyses of 122 femurs from 61 individuals, the mean length of the femur as measured from the tip of the lesser trochanter to the mid point of the trans-epicondylar axis was 37.86 ± 2.32 cm while the diameter of the head was 4.55 ± 0.31 cm and the range being 4.01-5.38 cm. The corresponding values for the right and the left were very similar [21]. In a study done amongst Koreans using three different methods to determine the length of the femur, a mean length of 41.45 ± 2.37 cm. using the osteometric board. Significant differences were noted amongst the values obtained by three methods. The other two methods were geometric computation of anatomical and mechanical axes [22]. Most of the studies referenced above did gender comparison and reported significantly higher values for the male. However, both right and left femur had similar values.

From the narrative thus far, the following inferences can be made that; (i) the length of the femur differs along population line, (ii) the length of femur varies with the reference points of measurements and (iii) the mode of study which could be direct bone measurement, human body measurement, plain radiograph and three-dimensional computer tomography scanning. For any meaningful comparison of studies, the mode of assessment and reference points of measurement must be taken into consideration. The length of the femur is a function of the overall height of the individual. Human height is influenced by genetics (hereditary), family trait, race and early childhood nutritional status. Thus, there cannot be a single value as the universal length of the femur. In a previous study on limb length inequality, we documented the

existence of a small but insignificant inequality between the length of the right and left lower limbs in normal people without obvious limb shortening [23]. Findings of our study and those of similar studies reveal slight but insignificant difference between the length of the right and left femurs.

Femur Head Diameter

In this study, the diameter of the head of the femur was measured at two perpendicular planes (superoinferior and medio-lateral) with no significant difference between the right and the left. The mean values as well as the range were very similar in both planes. In an antero-posterior pelvic X-ray films obtained from 97 patients (194 hips), the mean diameter of the head of the femur was 5.08 ± 0.43 cm with a range of 4.14-6.34 cm [24]. In another plain radiographic study of the proximal femur geometry done among Croatians, a value lower than ours was obtained as the femur head diameter (38.84 ± 5.32 mm and range being 30.00-52.10 mm)[25]. The mean vertical diameter of the femur head in Indian population has been reported as 4.54 ± 0.36 cm [26] and 42.70 ± 3.02 cm [27]. The latter study whose result was very similar to us was a direct measurement one. Also, in that study, the femur length was measured from the highest point of the head to the lowest point of the medial condyle got a similar value of 42.82 ± 2.87 cm as being the femur length. [27]. The diameter of the head of the femur in Chineseas obtained from pelvic X-rays measurement is slightly higher than ours [13]. Thus it is very pertinent to state and put into consideration the reference points of measurement when comparing the values of the femur length and femur head diameter as obtained by different studies. From the comparisons of femur head diameter among different races, it is obvious that it varies hence it will be misleading to state a single value as the diameter in textbooks of Human Anatomy.

A summary of the major findings of related studies and their comparison with the present study is presented in Table 2

Mathematical relationship between the Femur head diameter and Femur length (Head/length constant).

In all the related femur geometry studies available in the literature, none of them made any attempt at establishing a mathematical relationship between the femur head diameter and femur length. This study did and obtained a constant of 0.1 ± 0.01 as being the ratio of the femur head diameter to the femur length with a positive correlation coefficient. This is the same whether it is superoinferior (vertical), medio-lateral (horizontal) or average diameter. Expressed graphically, the parameters of the femur head diameter and femur length exhibit a linear relationship. The implication of this major feat is that the diameter of the femur head can be calculated from the femur length by multiplying the latter with 0.1 i.e. *Femur head diameter = femur length x 0.1*. Since this constant (0.1) has a very small standard deviation of 0.01, its reliability and predictability are very likely to be very high. The landmarks for femur length are very accessible and easily done on the non-fractured hip, the accuracy of preoperative

of hip prosthesis selection will be very high. The implications of this include but not limited to; ease of procedure, reduced postoperative complications and morbidity with improved quality of life. Using the areas of the head of the femur as derived from the vertical, horizontal and average diameters, to compute the head/length ratio; varying constants were obtained and as such cannot be used to predict the femur head diameter. In the choice of hip prosthesis, it is the diameter that is of importance and relevance.

TABLE 2: SUMMARY OF RELATED STUDIES

S/N	Parameter	Study Type	Population	Reference
1	A). Femur length; Mean- 42.83±2.90cm.Range (37.20-48.50 cm). B) Head diameter: i- Supero-inferior (vertical) 4.27±0.33 cm. Range 3.49-5.09. ii- Medio-lateral (horizontal) 4.47±0.33 cm. Range 3.67-5.37.	Direct human bone measurement (Osteometric board)	Nigerians(Africa)	This Study
2	Femur head diameter; 51.03± 3.88 mm	Pelvic X-rays (198 patients; 396 hips).	Chinese (Asia)	13
3	Femur length; Mean- 42.74±2.94cm Range- 36.06-51.11 cm	Computed Tomography Scanning	Japanese (Asia)	17
4	Femur Length; Mean 44.2 (male) Female 42.3 cm.	Direct human body measurement	Zambian (Africa)	18
5	Femur length: Male-42.38±19.04cm (range, 38.6-47.1cm) Female-38.72±40.15cm (range, 30.3- 45.2) Femur head vertical Diameter: Male- 4.3±0.24; range-3.05 to 4.87 cm. Female-3.82±0.23; range-3.33 to 4.33.	Direct bone measurement using an osteometric board	Indians (Asia)	19
6	Femur length Overall 42.0 ±3.1 cm (32.9-50.8) Asian femur length: 39.8±2.7; (32.9- 46.7 cm) Caucasian femur length : 43.0±2.8 cm; (35.3-50.8 cm).	3D Computer Tomography Scan (1189 femurs)	Asian 31% (369) Caucasian 69%(820)	20
7	Femur length: 37.86 ±2.32 cm Head diameter: 4.55±0.31cm (4.01-5.38 cm)	3D Computer Tomography Scan (112 femurs)	Not stated	21
8	Femur Length- 41.45±2.37 cm	Osteometric board (202 femurs).	Koreans (Asia)	22
9	Femur Head Diameter-5.08±0.43 cm.	Pelvic X-rays	Chinese (Asia)	24

	Range:4.14-6.34cm	(194 hips)		
10	Femur Head Diameter-3.88±0.53 cm. Range:3.00-5.21cm	Pelvic X-rays (300 patients; 600 hips).	Croatian (Europe)	25
11	Femur head diameter- 4.54±0.36 cm	Computer Tomography Scan (98 femurs)	Indians (Asia)	26
12	Femur length- 42.70±3.02 cm. Femur head diameter-4.23±0.41 cm	Direct bone measurement	Indians (Asia)	27

Conclusion

The length of the femur amongst Nigerians vary from those of other races and does not exhibit side differences.

The diameters of the head of the femur as measured along two perpendicular planes have negligible differences.

There is a linear relationship between femur head diameter and the length of the bone.

The ratio of the head diameter to the length of the femur has a constant factor of 0.1.

The length of femur is an accurate and very reliable predictor of the head diameter.

Disclaimer (Artificial intelligence)

Option 1:

Author(s) hereby declare that NO generative AI technologies such as Large Language Models (ChatGPT, COPILOT, etc) and text-to-image generators have been used during writing or editing of manuscripts.

REFERENCES

- 1 Moore K L, Dalley A F, Agur, A. (2017). Clinically Oriented Anatomy (8th ed.). in: The Femur. Lippincott Williams and Wilkins.
2. Junqueira LC, Carneiro J (2005). Basic Histology (11th ed) in: The Bone. MC Graw-Hill
3. Kulkarni NV (2012). Clinical Anatomy (A Problem Solving Approach) (2nd ed). in: Bones of the lower limb p.825. Jaypee Brothers Medical Publishers New Delhi, India.
4. Rintoul RF. Farquharson Textbook of Operative Surgery (8th ed). in: Orthopaedic Surgery p146-152. 1995 Churchill Livingstone.
5. Blakeney WG, Kuster M. Advances in Hip Replacement Surgery. J Clin Med. 2023;12(10):3439.
6. Guo DH, Li XM, Ma SQ, Zhao YC, Qi C, Xue Y. Total Hip Arthroplasty with Robotic Arm Assistance for Precise Cup Positioning: A Case-Control Study. Orthop Surg. 2022 Jul;14(7):1498-1505.
7. Tian R, Duan X, Kong N, Wang K, Yang P. Precise acetabular positioning, discrepancy in leg length, and hip offset using a new seven-axis robot-assisted total hip arthroplasty system requires no learning curve: a retrospective study. J Orthop Surg Res. 2023 Mar 24;18(1):236.
8. Seagrave KG, Troelsen A, Malchau H, Husted H, Gromov K. Acetabular cup position and risk of dislocation in primary total hip arthroplasty. Acta Orthop. 2017;88(1):10-17.

9. Guyen O. Hemiarthroplasty or total hip arthroplasty in recent femoral neck fractures? *Orthop Traumatol Surg Res.* 2019;105(1S):S95-S101.
10. Shigemura T, Yamamoto Y, Murata Y, Sato T, Tsuchiya R, Mizuki N, Toki Y, Wada Y. Total hip arthroplasty after failed transtrochanteric rotational osteotomy for osteonecrosis of the femoral head: A systematic review and meta-analysis. *Orthopaedics & Traumatology: Surgery & Research* 104 (2018) 1163–1170
11. Atik OŞ, Hangody LR. Total hip replacement or hip hemiarthroplasty for the treatment of displaced femoral neck fractures in the elderly? *Jt Dis Relat Surg.* 2022;33(3):705-706.
12. Aguado-Maestro I, de Blas-Sanz I, Sanz-Peñas AE, et al. Dual Mobility Cups as the Routine Choice in Total Hip Arthroplasty. *Medicina (Kaunas).* 2022;58(4):528.
13. Hu ZS, Liu XL, Zhang YZ. Comparison of Proximal Femoral Geometry and Risk Factors between Femoral Neck Fractures and Femoral Intertrochanteric Fractures in an Elderly Chinese Population. *Chin Med J (Engl).* 2018;131(21):2524-2530.
14. Chang SM, Song DL, Ma Z, Tao YL, Chen WL, Zhang LZ, et al. Mismatch of the short straight cephalomedullary nail (PFNA-II) with the anterior bow of the femur in an Asian population. *J Orthop Trauma* 2014; 28:17-22.
15. Feng W, Yu B, Hao T, Hao ZT. Geometric match assessment of three intramedullary nailing systems for Chinese proximal femurs (in Chinese). *Chin J Orthop Trauma* 2011; 13:1029-33.
16. Du XR, Lu SB. Research progress on anatomical study of the proximal femoral canal (in Chinese). *Chin J Clin Anat* 2004; 22:674-6.
17. Kira K, Chiba F, Makino Y, et al. Stature estimation by semi-automatic measurements of 3D CT images of the femur. *Int J Legal Med.* 2023;137(2):359-377.
18. Chansa Mulenga. "A Cross - Section Study to Determine Human Height Using Femur Length in Zambian Population". *Acta Scientific Microbiology* 2019; 2 (11): 57-61.
19. Moosa SS, Shaikh MHR, Khwaja M, et al. Sexual dimorphic parameters of femur: a clinical guide in orthopedics and forensic studies. *J Med Life.* 2021;14(6):762-768.
20. Thiesen DM, Ntalos D, Korthaus A, Petersik A, Frosch KH, Hartel MJ. A comparison between Asians and Caucasians in the dimensions of the femoral isthmus based on a 3D-CT analysis of 1189 adult femurs. *Eur J Trauma Emerg Surg.* 2022;48(3):2379-2386.
21. Dimitriou D, Tsai TY, Yue B, Rubash HE, Kwon YM, Li G. Side-to-side variation in normal femoral morphology: 3D CT analysis of 122 femurs. *Orthop Traumatol Surg Res.* 2016;102(1):91-97.
22. Cho HJ, Kwak DS, Kim IB. Morphometric Evaluation of Korean Femurs by Geometric Computation: Comparisons of the Sex and the Population. *Biomed Res Int.* 2015; 2015:730538.
23. Ajani, R.S. and Ayanleke, E.O. Prevalence and Degree of Lower Limb Inequality in Asymptomatic Young Adult Nigerians. *Journal of Advances in Medical and Pharmaceutical Sciences.* 2020;22(9):1-9

24. Wang G, Guo A, Zhang Y, et al. Measurement of the relative position of the femoral head center, greater trochanter, and lesser trochanter. *Ann Palliat Med.* 2021;10(11):11524-11528.
25. Mokrovic H, Komen S, Gulan L, Gulan G. Radiographic analysis of the proximal femoral anatomy in the Croatian population. *Int Orthop.* 2021;45(4):923-929.
26. Rawal B, Ribeiro R, Malhotra R, Bhatnagar N. Anthropometric measurements to design best-fit femoral stem for the Indian population. *Indian J Orthop.* 2012;46(1):46-53.
27. Verma M, Joshi S, Tuli A, Raheja S, Jain P, Srivastava P. Morphometry of Proximal Femur in Indian Population. *J Clin Diagn Res.* 2017;11(2):AC01-AC04.
28. Ahmad, Saeed, Irfan Qadir, Jahanzeb Mazari, and Amer Aziz. 2022. "Non-Wedge Technique for Valgus Subtrochanteric Osteotomy in Pediatric Femoral Neck Non-Union". *Asian Journal of Orthopaedic Research* 5 (2):263-69. <https://journalajorr.com/index.php/AJORR/article/view/153>.
29. Mielke M, Wölfer J, Arnold P, van Heteren AH, Amson E, Nyakatura JA. Trabecular architecture in the sciuriform femoral head: allometry and functional adaptation. *Zoological letters.* 2018 Dec;4:1-1.
30. Bidau CJ, Martínez PA. Evolutionary negative allometry of orthopteran hind femur length is a general phenomenon. *Zoomorphology.* 2018 Jun;137(2):291-304.