

Multiple Ischemic Strokes as the Initial Presentation of Hyperthyroidism Complicated by Atrial Fibrillation

Abstract

We report the case of a 43-year-old man admitted for multiple ischemic strokes. Investigations revealed hyperthyroidism complicated by rapid atrial fibrillation (tachy AF). With no significant medical history, the patient presented with sudden speech suspension and a mild motor deficit in the upper limbs. Imaging confirmed ischemic strokes of different ages, and laboratory analyses showed very high levels of T3 and T4, with a suppressed TSH.

Initial treatment included dimazole for hyperthyroidism, avlocardyl for atrial fibrillation, and anticoagulation due to a CHADS-VASc score of 2. An echocardiogram revealed moderate mitral insufficiency and left atrial dilation. During hospitalization, the patient also had generalized convulsive seizures, requiring anticonvulsant treatment. After appropriate management, the patient showed significant clinical improvement, with a return to a regular sinus rhythm and normalization of hormone levels, leading to a full neurological recovery.

This case highlights the importance of recognizing the interactions between endocrine and cardiovascular pathologies, particularly the impact of hyperthyroidism on atrial fibrillation and the increased risk of stroke. A multidisciplinary approach is essential for diagnosing and treating these complex conditions to prevent serious complications and improve patient prognosis.

1. Introduction

Atrial fibrillation (AF) is a common cardiac arrhythmia characterized by rapid and disorganized electrical activity in the atria, leading to ineffective atrial contraction. AF can be associated with various cardiovascular and systemic risk factors, including hyperthyroidism. This arrhythmia is a major cause of morbidity, significantly increasing the risk of thromboembolic events, particularly ischemic strokes [1].

We report a rare case with an atypical presentation where multiple ischemic strokes revealed hyperthyroidism complicated by rapid atrial fibrillation (tachy AF). This case highlights the importance of rapid recognition and treatment of underlying cardiac pathologies in patients presenting with acute neurological events, underscoring the critical interplay between the cardiovascular and endocrine systems.

2. Clinical Presentation

We report the case of a 43-year-old patient admitted to the neurology department for multiple ischemic strokes of different ages, presenting with a mild motor deficit of the upper limbs and sudden speech suspension. The stroke revealed hyperthyroidism complicated by rapid atrial fibrillation at 120 beats per minute (figure 1). The patient, with no significant pathological history, was admitted to the emergency room at 4 a.m. for sudden speech suspension. An emergency brain CT scan showed signs of multiple ischemic strokes. A subsequent brain MRI revealed ischemic strokes of different ages in the supra-tentorial regions, with acute lesions located in the left frontal and fronto-parietal insular regions, affecting the anterior superficial watershed territories and the left middle cerebral artery (figure 2). Upon admission, the patient was conscious and hemodynamically and respiratory stable, with speech suspension and no other associated signs. The ECG showed rapid

atrial fibrillation (tachy AF) at 125 bpm. Complete laboratory tests revealed suppressed TSH with very high levels of T3 and T4 (T4 > 77 and T3 at 23.2), hemoglobin at 12.4 g/dL, white blood cells, renal and liver function without abnormalities, and negative CRP.

The patient was treated with dimazole with liver function monitoring and underwent a cervical ultrasound showing acute thyroiditis. He was also treated with avlocardyl at 80 mg per day and, due to a CHADS-VASc score of 2, curative-dose anticoagulation was initiated with a scan control to look for signs of hemorrhage. A transthoracic echocardiogram revealed moderate mitral insufficiency with left atrial dilation without signs of mitral stenosis (figure 3). During hospitalization, the patient experienced generalized convulsive seizures with postictal agitation, requiring anticonvulsant treatment which showed good clinical response.

During his stay, follow-up ECGs showed a return to a regular sinus rhythm. Laboratory tests also revealed normalization of TSH, T3, and T4 levels, with good clinical evolution and complete neurological recovery.

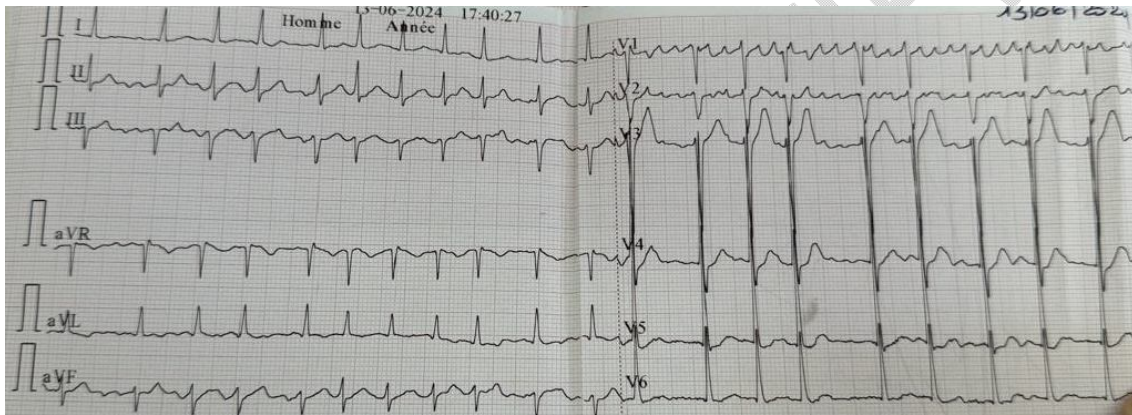


Figure 1: ECG Demonstrating Atrial Tachycardia at a Rate of 120 Beats Per Minute.

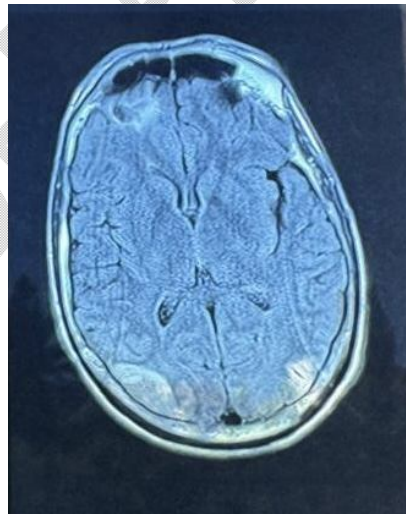


Figure 2: MRI Image Demonstrating Multiple Bilateral Occipital-Parietal Ischemic Strokes.

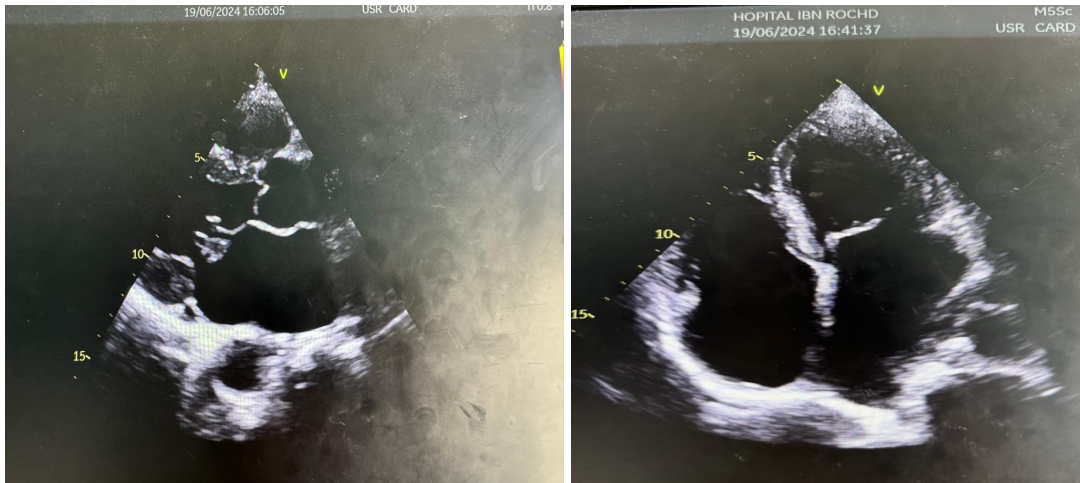


Figure 3 :Parasternal Long-Axis and Short-Axis Views Showing Bi-Atrial Dilatation.

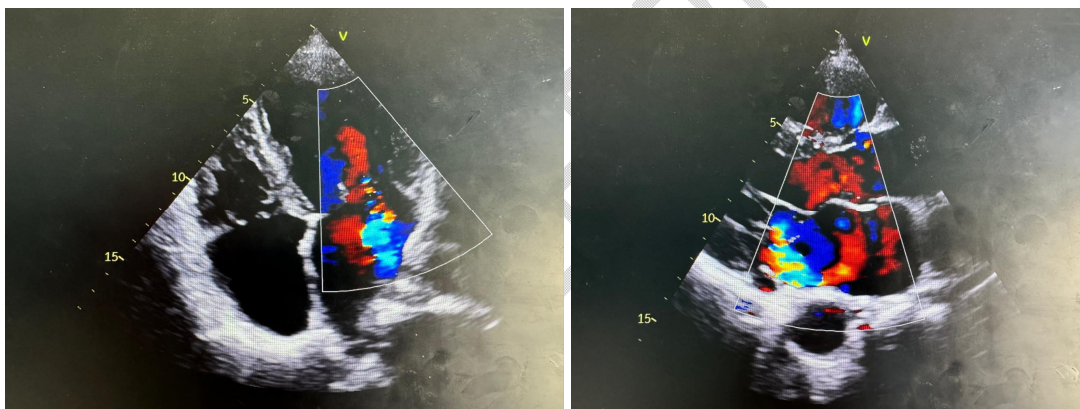


Figure 4: 2D Echocardiographic Image with Color Doppler Demonstrating Moderate Mitral Regurgitation.

3. Discussion

The rapid atrial fibrillation (tachy AF) observed in this clinical case is a supraventricular arrhythmia characterized by a rapid and irregular heart rate. It is often associated with palpitations, dyspnea, fatigue, and, in severe cases, thromboembolic complications such as strokes (AVC) [2]. Hyperthyroidism, an endocrine condition marked by excessive production of thyroid hormones (T3 and T4), can also accelerate basal metabolism, leading to symptoms such as weight loss, nervousness, tremors, and palpitations. The relationship between hyperthyroidism and atrial fibrillation is well documented, with thyroid hormones increasing the sensitivity of beta-adrenergic receptors, predisposing to arrhythmias [3].

Studies show that hyperthyroidism significantly increases the risk of ischemic stroke due to the often-associated atrial fibrillation [1]. Undiagnosed thyrotoxicosis revealed by multiple ischemic strokes, as in this case, is rare but critical. For instance, a similar case report documents

thyrotoxicosis revealed by multifocal ischemic stroke, emphasizing the importance of considering endocrine diagnoses in such contexts [4].

The relationship between thyroid disorders and strokes is further reinforced by systematic reviews identifying hyperthyroidism as a major risk factor for ischemic stroke through atrial fibrillation [5]. Moreover, atrial fibrillation itself is a well-known predisposing factor for strokes, with hyperthyroidism further increasing this risk [2]. Managing hyperthyroidism in patients with atrial fibrillation is thus crucial to reducing the risk of thromboembolic events [6].

Recent studies also show that early recognition and aggressive management of hyperthyroidism can improve outcomes in patients with cardiac arrhythmias [7]. Meta-analyses indicate that thyroid function should be closely monitored in patients at risk of atrial fibrillation and stroke [8]. Additionally, anticoagulation is an important strategy to prevent strokes in hyperthyroid patients with atrial fibrillation [9].

This clinical case illustrates the complexity and rarity of a simultaneous presentation of multiple ischemic strokes, hyperthyroidism, and rapid atrial fibrillation. Rapid recognition of this clinical combination is essential for adequate management and prevention of severe complications. Existing literature underscores the importance of a multidisciplinary approach to improve prognosis and prevent severe complications in patients presenting with acute neurological events without obvious clinical history [10].

4. Conclusion

This clinical case illustrates a rare and complex presentation of multiple ischemic strokes associated with hyperthyroidism complicated by rapid atrial fibrillation. The rapid progression and severity of symptoms, in the absence of pathological history, highlight the importance of a multidisciplinary approach and a thorough evaluation of underlying conditions. This report highlights the need to consider endocrine and cardiovascular diagnoses in patients presenting with acute neurological events without obvious clinical history. Early recognition and treatment of these conditions can significantly improve prognosis and prevent severe complications, making this case a valuable addition to the medical literature.

References

1. Chung-Wah Siu 1, Vincent Pong, Xuehua Zhang, Yap-Hang Chan, Man-Hong Jim, Shasha Liu, Kai-Hang Yiu, Annie W C Kung, Chu-Pak Lau, Hung-Fat Tse "Risk of ischemic stroke after new-onset atrial fibrillation in patients with hyperthyroidism" DOI: 10.1016/j.hrthm.2008.10.023, <https://pubmed.ncbi.nlm.nih.gov/19187905/>
2. M. O'Donnell, N. Valens, M. Lansberg, et C. Wijman, "Thyroid replacement therapy and atrial fibrillation in acute ischemic stroke," *Neurology*, vol. 67, pp. 1714-1715, 2006. <https://pubmed.ncbi.nlm.nih.gov/17101919/>
3. K. Kim, P.-S. Yang, E. Jang, H. Yu, T.-H. Kim, J. Uhm, J.-Y. Kim, J. Sung, H. Pak, M.-H. Lee, G. Lip, et B. Joung, "Increased risk of ischemic stroke and systemic embolism in hyperthyroidism-related atrial fibrillation: A nationwide cohort study," *American Heart Journal*, 2021.
4. Z. B. Gunduz et A. Ozşahin, "Acute ischemic stroke in young adult: Atrial fibrillation, hyperthyroidism, and COVID-19 collaboration," *SAGE Open Medical Case Reports*, vol. 9, 2021. <https://journals.sagepub.com/doi/pdf/10.1177/2050313X211048632>

5. Wong C.L., Tam H.K.V., Fok C.K.V., Lam P.K.E., Fung L.M. Thyrotoxic Atrial Fibrillation: Factors Associated with Persistence and Risk of Ischemic Stroke. *J. Thyroid Res.* 2017;2017:425183. doi: 10.1155/2017/4259183. <https://www.ncbi.nlm.nih.gov/pmc/articles/PMC5742874/>
6. I. Migdady, A. Russman, et A. Buletko, "Atrial fibrillation and ischemic stroke: A clinical review," *Seminars in Neurology*, vol. 41, pp. 348-364, 2021. <https://pubmed.ncbi.nlm.nih.gov/33851396/>
7. Q. Chen, Y. Yan, L. Zhang, K. Cheng, Y. Liu, et W. Zhu, "Effect of hyperthyroidism on the hypercoagulable state and thromboembolic events in patients with atrial fibrillation," *Cardiology*, vol. 127, pp. 176-182, 2014. <https://karger.com/crd/article-abstract/127/3/176/79199/Effect-of-Hyperthyroidism-on-the-Hypercoagulable?redirectedFrom=fulltext>
8. Sposato, LA, Klein, FR, Jáuregui, A, Ferrúa, M, Klin, P, Zamora, R, Riccio, PM, Rabinstein, A. Newly diagnosed atrial fibrillation after acute ischemic stroke and transient ischemic attack: importance of immediate and prolonged continuous cardiac monitoring. *J Stroke Cerebrovasc Dis.* 2012;21:210–216. doi: 10.1016/j.jstrokecerebrovasdis.2010.06.010
<https://pubmed.ncbi.nlm.nih.gov/20727789/>
9. Buccelletti F, Carroccia A, Marsiliani D, Gilardi E, Silveri NG, & Franceschi F. Utility of routine thyroid-stimulating hormone determination in new-onset atrial fibrillation in the ED. *American Journal of Emergency Medicine* 2011 29 1158–1162. <https://doi.org/10.1016/j.ajem.2010.06.010>
10. J. Haft, et L. Teichholz, "Echocardiographic and clinical risk factors for atrial fibrillation in hypertensive patients with ischemic stroke," *The American Journal of Cardiology*, vol. 102, no. 10, pp. 1348-1351, 2008.
<https://www.sciencedirect.com/science/article/abs/pii/S0002914908011831>

UNDER PEER REVIEW