

The Role of Endoscopic Ultrasound in the Management and Diagnosis of Pancreatic Cystic Tumors

Abstract:

Background:

Cystic tumors of the pancreas are rare neoplasms, increasingly discovered incidentally due in part to improvements in pancreatic imaging techniques (ultrasound, multidetector CT scan (Computed Tomography scan), Magnetic Resonance Imaging (MRI)) and enhanced understanding of these lesions' characteristics. They encompass serous cystadenomas (SC), mucinous cystadenomas (MC), intraductal papillary mucinous neoplasms (IPMN), and solid pseudopapillary tumors (SPPT).

Method:

This is a single-center study conducted at the EFD-HGE Unit (functional digestive exploration - hepato-gastroenterology unit) of Ibn Sina Hospital in Rabat, from September 2015 to May 2024, including all patients with pancreatic cystic tumors. Pancreatic pseudocysts were excluded from the study. Epidemiological, clinical, biological, and endoscopic ultrasound data were collected from Endoscopic Ultrasound registries.

Results:

Out of 696 biliopancreatic endoscopic ultrasounds performed, 57 patients were included, representing a prevalence of 8.18%. The mean age was 62.3 years (range 29-82 years) with a clear female predominance (M: 22, F: 35) (Sex Ratio = 0.62). Discovery circumstances were incidental in 23 cases (40.3%), epigastric pain in 18 cases (31.57%), acute pancreatitis in 6 cases (10.5%), jaundice in 5 cases (8.7%), and abdominal pain in 5 cases (8.7%). Biochemically, cholestasis was found in 14 cases (24.5%), cytolytic enzymes were elevated in 7 cases (12.2%), and elevated Ca19-9 in 6 cases (10.52%). Endoscopic ultrasound delineated tumor location, number, and size: predominantly in the pancreatic head in 25 cases (43.8%), body in 15 cases (26.3%), tail in 10 cases (17.5%), multifocal in 7 cases (12.28%), with an average tumor size of 24.5 mm (range 2,5 -76,5 mm). Endoscopic ultrasound appearance and cystic fluid analysis favored IPMN in 77.1% (n=44), mucinous cystadenoma in 8.7% (n=5), SPT in 7% (n=4), serous cystadenoma in 5.26% (n=3), and adenocarcinoma in one case.

Conclusion:

Pancreatic cystic tumors are rare and often incidentally discovered. They predominantly occur in the pancreatic head, with IPMN being the most common, followed by mucinous cystadenomas, while serous cystadenomas and SPPTs are less frequent.

Keywords: Pancreatic cystic tumors, Endoscopic Ultrasound, IPMN, mucinous cystadenoma, serous cystadenoma, solid pseudopapillary tumors.

1. Introduction:

Pancreatic cystic tumors are rare neoplasms but are increasingly recognized due to advancements in imaging techniques and our understanding of their characteristics. These technological advancements have enabled earlier and more precise detection of cystic lesions, often discovered incidentally during examinations performed for other clinical indications. Radiological and endoscopic characterization, sometimes including cystic fluid aspiration for analysis, is crucial for avoiding unnecessary surgical interventions and for monitoring lesions at risk of malignant degeneration.

Despite these advancements, the diagnosis of pancreatic cystic tumors remains challenging due to the variety of tumor types and their often non specific clinical presentation. Proper management of these tumors requires a therapeutic strategy based on accurate diagnosis and a thorough understanding of the natural history of each tumor type. This approach not only optimizes therapeutic decisions but also reduces the risks associated with inappropriate interventions. The ongoing evolution of imaging techniques and management methods for pancreatic cystic tumors presents opportunities to improve clinical outcomes and expand our understanding of these complex neoplasms.

AIM: The objectives of our study are to evaluate the epidemiological and morphological characteristics of pancreatic cystic tumors, as well as to assess the diagnostic yield of endoscopic ultrasound in their management.

2. Materials and Methods:

This is a single-center **retrospective** study conducted at the EFD-HGE Unit of Ibn Sina Hospital in Rabat, from September 2015 to May 2024, including all patients with pancreatic cystic tumors. Pancreatic pseudocysts were excluded from the study. Epidemiological, clinical, biological, and endoscopic ultrasound data were collected from Endoscopic Ultrasound registries.

All endoscopic ultrasounds were performed under Propofol sedation using radial and/or linear Pentax video echoendoscopes, with cytology obtained via needles of various calibers (19G-20G-22G) for biochemical analysis of cystic fluid and/or histopathological examination.

3. Results:

Out of 696 biliopancreatic endoscopic ultrasounds performed, 57 patients were included, representing a prevalence of 8.18%. The mean age was 62.3 years (range 29-82 years) with a clear female predominance (M: 22, F: 35) (Sex Ratio = 0.62). (Figure 1)

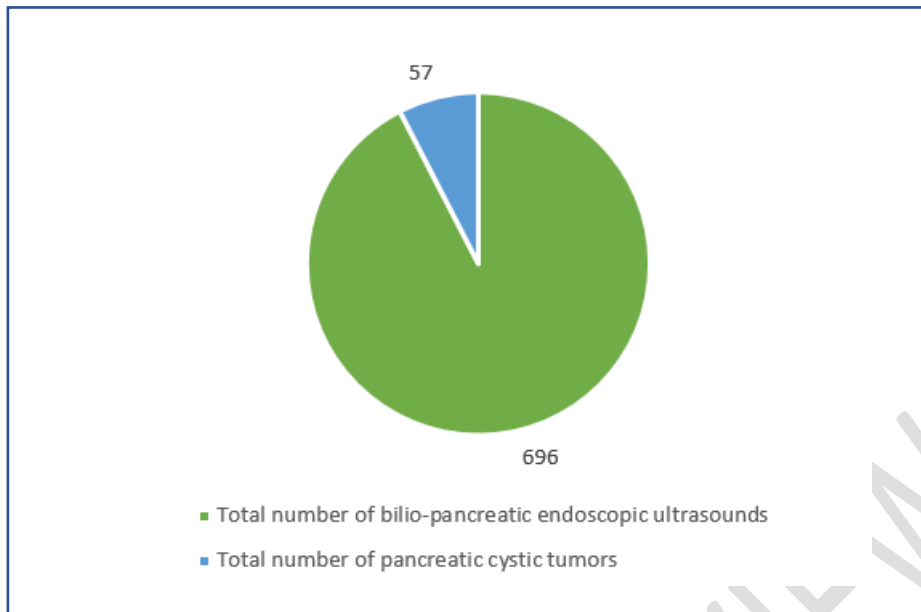


Figure 1: Prevalence of pancreatic cystic tumors

Discovery circumstances were incidental in 23 cases (40.3%), epigastric pain in 18 cases (31.57%), acute pancreatitis in 6 cases (10.5%), jaundice in 5 cases (8.7%), right hypochondrial pain in 3 cases (5.26%) and left hypochondrial pain in 2 cases (3.5%). (Figure 2)

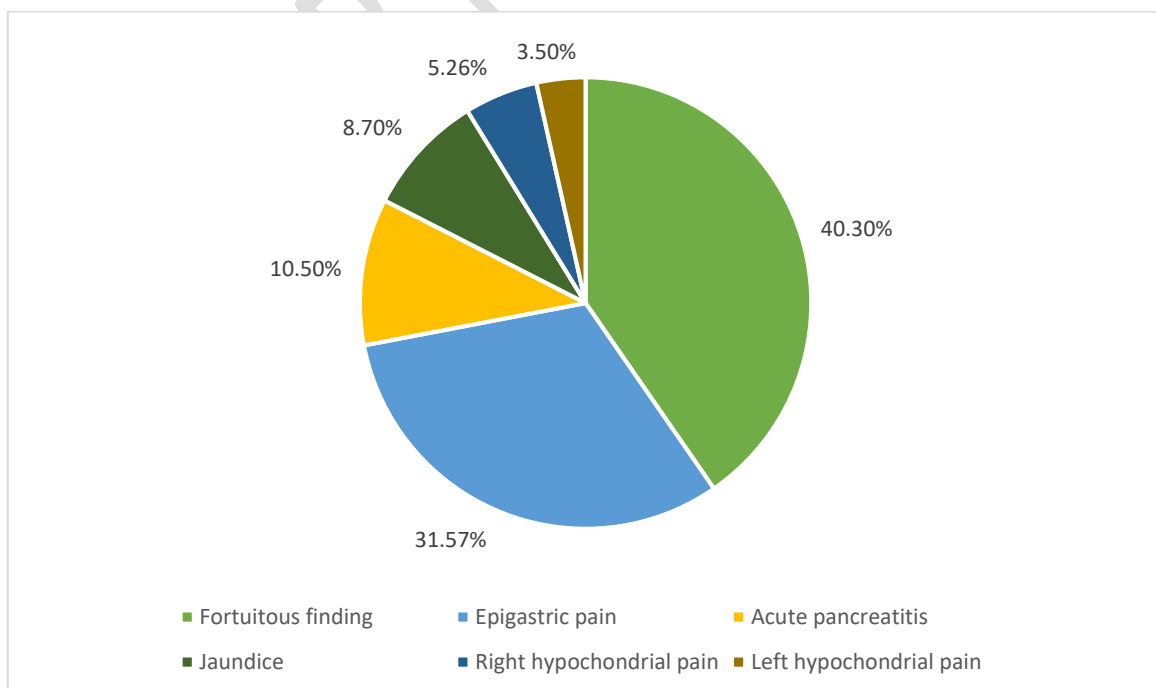


Figure 2: Discovery circumstances

Biologically, cholestasis was found in 14 cases (24.5%), cytolytic enzymes were elevated in 7 cases (12.2%), and elevated Ca19-9 in 6 cases (10.52%). (Figure3)

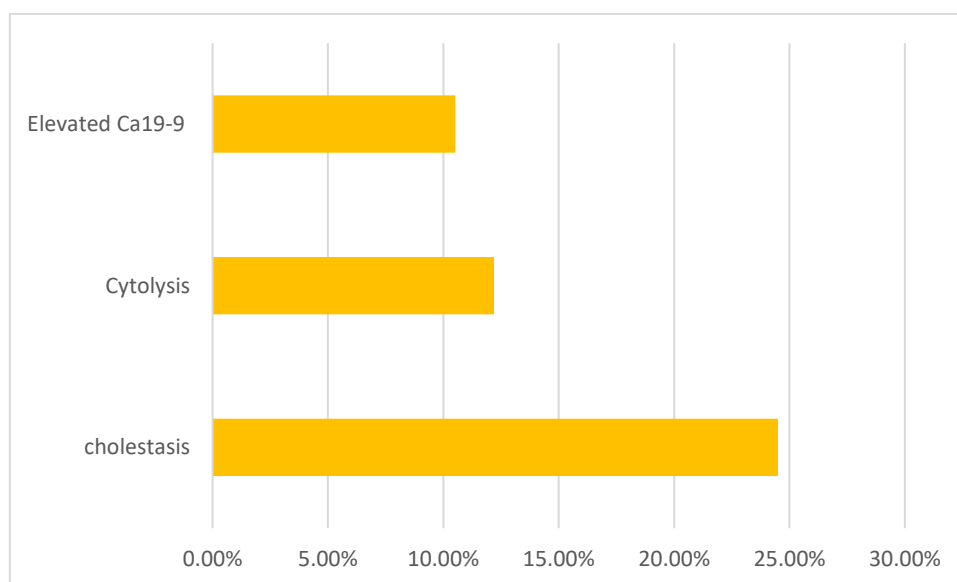


Figure 3: Biological assessment

Abdominal CT scan alone preceded the indication for EES in 89% of cases (n = 51). Bilio-pancreatic MRI was performed in 19.2% of patients (n = 11). Imaging enabled the cystic nature of the process and its size to be determined in 75.4% of cases (n=43)

Endoscopic ultrasound delineated tumor location, number, and size: predominantly in the pancreatic head in 25 cases (43.8%), body in 15 cases (26.3%), tail in 10 cases (17.5%), multifocal in 7 cases (12.28%), with an average tumor size of 24.5 mm (range 2,5 -76,5mm). (Figure 4)

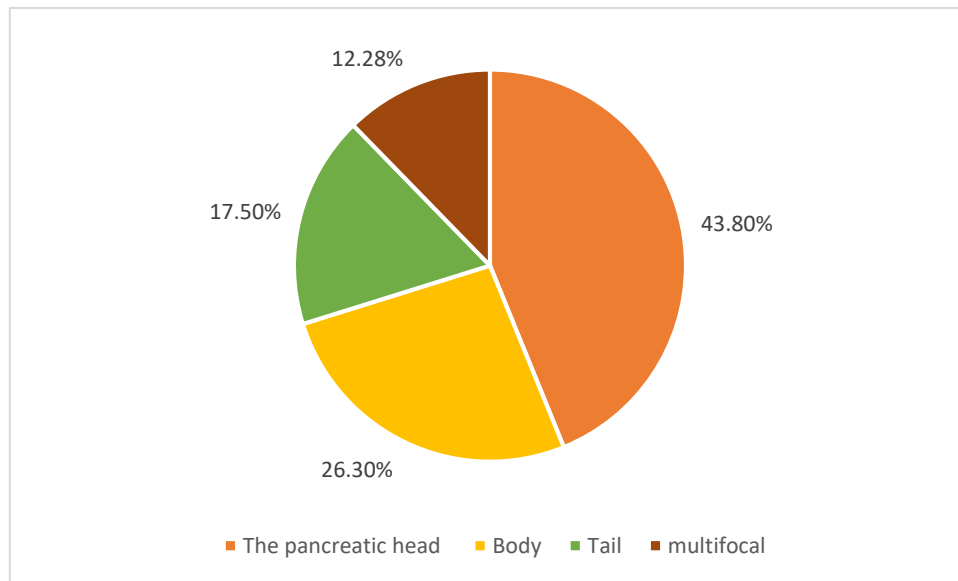


Figure 4: Distribution of patients according to the location of the cystic tumor

Communication with pancreatic ducts was observed in 44 cases (77.1%), and Wirsung duct dilation in 17 cases (29.82%). Cytology was performed in 29 cases (51%). Endoscopic ultrasound appearance and cystic fluid analysis favored IPMN in 77.1% (n=44), mucinous cystadenoma in 8.7% (n=5), solid pseudopapillary tumors in 7% (n=4), serous cystadenoma in 5.26% (n=3), and adenocarcinoma in one case. (Figure 5)

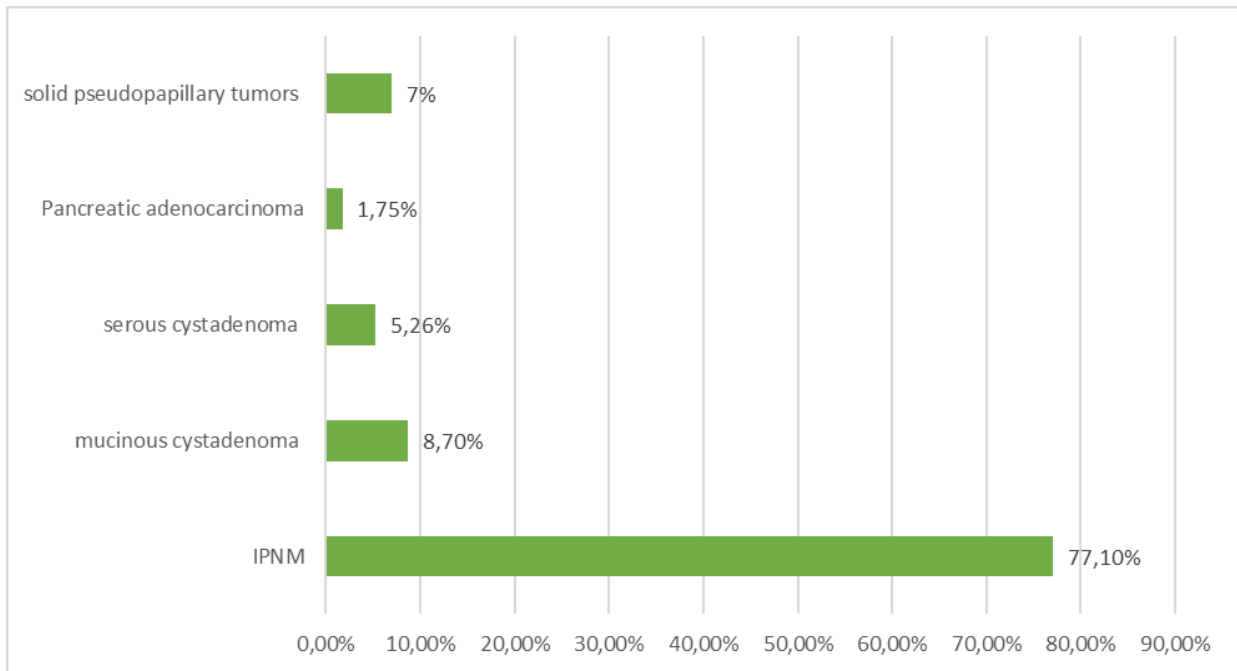


Figure 5: Endoscopic ultrasound appearance associated with cystic fluid aspect and analysis

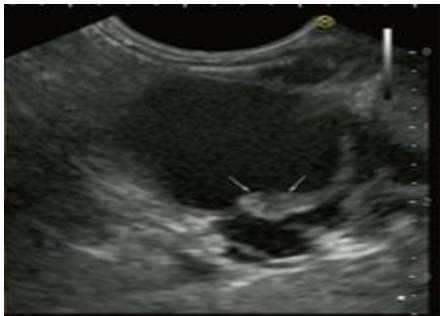

Figure 6: Endoscopic ultrasound image of an IPMN

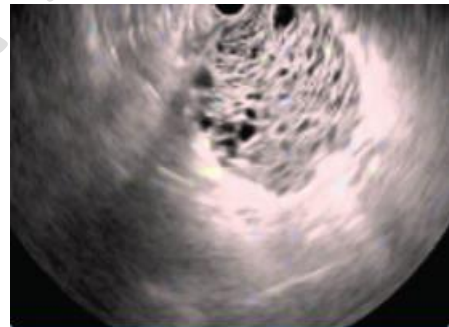


Figure 7: Endoscopic ultrasound image of a serous cystadenoma

4. Discussion:

Cystic tumors of the pancreas are a relatively frequent indication for biliopancreatic echo-endoscopy.

In our series, it accounted for 8.18% of all bilio-pancreatic echo-endoscopies performed. we excluded pancreatic pseudocysts. We based our differentiation between cystic tumors and pseudocysts on cross-sectional imaging (MRI, CT) and endoscopic ultrasound with fine needle aspiration for cystic fluid analysis.

This approach generally facilitates the differential diagnosis, especially when supported by a consistent clinical history [26]

However, its frequency varies according to the different studies carried out. In the study by Frank H. Miller et al. [1], it was 10%; in the study by Catalina Vladuț et al. [2-3], it was 12.9%. It is even lower, at 3%, according to the study conducted by the team of A. Lira-Trevino's team [4].

In our series, the average age of our patients was 62.3 years, which closely aligns with the average ages reported in the literature which is 61 years according to the study conducted by the team of Peter J. Allen et al. [5],

60 years according to the study conducted by Danielle E. Kruse et al. [6] and 66.12 years according to the study conducted by Beata Jabłońska et al. [7].

This is consistent with several studies, including Abigail Schubach et al., who observed that the incidence of cystic pancreatic tumors increases with age. This may explain the advanced average age observed in our study and in the various international series previously mentioned [8-9].

Our patients were predominantly female, with an M/F sex ratio of 0.62 representing 61% of cases, in line with various studies in the literature.

In the study by Aline Falqueto et al. [10], women accounted for 60.4% of patients, and in the study by Jennifer E. Verbesey et al. [11], 66.6%.

There are no specific and precise signs that can lead to a diagnosis of pancreatic cystic tumors. Diagnosis can be incidental, particularly following radiological or ultrasound examinations motivated by other conditions. In our study, incidental findings were noted in 40.3% of our patients. This is consistent with several studies, such as Carlos Fernández-del Castillo et al. [12], who reported incidental findings in 36.7% of patients, and Feixiang Hu et al. [13], where 49% of routine imaging exams accidentally detected pancreatic cystic lesions.

The potential clinical impact of these incidental findings is significant. Detecting pancreatic cystic lesions incidentally can lead to various outcomes, including increased diagnostic anxiety for patients and the need for additional follow-up procedures. While some incidental findings may be benign and clinically insignificant, others could indicate potentially serious conditions that require further investigation.

Pain is the most frequent and revealing clinical sign of pancreatic cystic lesions, typically presenting as epigastric pain. It is in 51.4% of cases according to Carlos Fernández-del Castillo et al. [12]. In our study, abdominal pain was

reported in 40.33% of cases, epigastric pain in 31.57%, right hypochondrium pain in 5.26%, and left hypochondrium pain in 3.5% of cases.

Acute pancreatitis was noted in 10.5% of our patients, consistent with findings in other series such as 26.8% according to Carlos Fernández-del Castillo et al. [12] and 3.2% according to Beata Jabłońska et al. [14].

Jaundice was also noted as a mode of discovery in 8.7% of cases in our study, which is comparable to findings in other studies; for example, 13.4% according to Carlos Fernández-del Castillo et al. [12].

Routine laboratory tests are usually normal except in cases of biliary or pancreatic duct compression. In our series, 24.5% of patients had biochemical cholestasis, and 12.2% had hepatic cytolysis. Comparing our results with literature, the rate of liver function test abnormalities is similar to that found in the study by Dupas B et al. [15], where liver function disturbances were noted in 13% of cases.

An elevation in CA19-9 was noted in 10.52% of our patients, which is comparable to the 15% elevation reported in the study by Renata Talar et al. [16].

In our study, an abdominal CT scan alone preceded the indication for Endoscopic Ultrasound (EUS) in 89% of cases. Biliary-pancreatic MRI was performed in 19.2% of patients. Imaging allowed for the determination of the cystic nature of the lesions and their size in 75.4% of cases. We specifically noted that variations in imaging techniques could influence the characterization of pancreatic cystic tumors. Additionally, differing levels of expertise among radiologists might affect diagnostic accuracy.

EUS (Endoscopic Ultrasound) is an essential tool in the evaluation of pancreatic cystic lesions, providing high-resolution imaging. Its diagnostic efficacy is comparable to MRI for characterizing lesions and demonstrating their communication with the main pancreatic duct. Moreover, EUS is superior in detecting multifocal, synchronous, or metachronous lesions, and identifying intramural nodules considered to have a high risk of malignancy. In all cases, whenever technically feasible, tissue should be sampled for histopathological study, as EUS imaging alone cannot confirm or exclude malignancy [17].

EUS-guided Fine Needle Biopsy (EUS-FNB) offers high diagnostic precision for pancreatic cystic tumors by enabling tissue acquisition for histological analysis. A multicenter randomized controlled trial by van Riet et al., comparing Endoscopic Ultrasound-Guided Fine Needle Aspiration (EUS-FNA) and EUS-FNB, demonstrated that EUS-FNB had superior histological yield (82% vs.

72%) and greater accuracy in diagnosing malignancy (87% vs. 78%) compared to EUS-FNA [18].

There are several types of pancreatic cystic tumors, including IPMNs (Intraductal Papillary Mucinous Neoplasms), mucinous cystadenomas, serous cystadenomas, and solid pseudopapillary neoplasms of the pancreas. The actual incidence of IPMNs varies between studies. In our series, the frequency of this diagnosis was 77.1%. This aligns with various international studies reporting rates of 65% in the study by William R et al. [19], 67% in the study by Laura D. Wood et al. [20], and up to 78.3% in the study by Tsuyoshi Hamada et al. [21].

Mucinous cystadenomas of the pancreas are cystic tumors that are much more common in women, typically occurring in their fifth decade of life. They are generally asymptomatic but can cause abdominal pain, weight loss, anorexia, fatigue, or jaundice [19].

EUS (Endoscopic Ultrasound) reveals thin-walled cysts with septations and fluid-filled cavities. Communication with ducts is rare. Suspicious features of malignancy on EUS include irregular cyst wall, thickening, and intracystic solid components [19].

In our series, mucinous cystadenoma was suspected in 8.7% of cases. This aligns with findings from other studies, reporting a pancreatic cystadenoma diagnostic rate of 10.8% in the study by Feixiang Hu et al. [13], 18.8% in the study by A. Lira-Treviño et al. [4], and up to 21.3% in the study by Srinivas Bojanapu et al. [22].

Solid pseudopapillary neoplasms (SPN) of the pancreas are tumors typically found in young women, with a low incidence and an excellent prognosis following surgical resection. They tend to be moderately symptomatic or asymptomatic [24].

SPNs represent nearly 4% of pancreatic cystic tumors. Smaller lesions are predominantly solid, while larger lesions may contain more cystic components. There is typically no connection with the main pancreatic duct, resulting in low amylase levels in the fluid [23].

EUS-guided Fine Needle Biopsy (EUS-FNB) is often diagnostic, and smaller lesions may appear solely solid, whereas larger ones may show cystic degeneration, sometimes with a hemorrhagic appearance upon sampling [3].

In our study, the frequency of SPN diagnosis was 7%.

Serous cystadenomas are the most common benign lesions, accounting for 16% of all pancreatic cysts [25]. They are mostly asymptomatic, with an average age at diagnosis of 62 years [3]. Serous cystadenomas are frequently seen in patients with von Hippel-Lindau (VHL) syndrome [25].

Diagnosis through imaging (CT, MRI, EUS) is crucial, revealing honeycomb-like multilocular cystic lesions with a central scar or star-shaped calcification (seen in 20% of cases). The latter is pathognomonic for serous cystadenomas [3].

In our series, serous cystadenomas were suspected in 5.26% of cases during endoscopic ultrasound.

In our study, we examined the risk of malignancy associated with pancreatic cystic lesions. Our findings indicate that 1.75% of the pathological results were in favor of pancreatic adenocarcinoma. This percentage highlights the potential for malignancy among the identified cystic lesions. It is crucial to note that pancreatic cystic lesions can present a range of characteristics, some of which may be associated with an increased risk of malignancy.

Our study underscores that pancreatic cystic tumors are often discovered incidentally, highlighting the critical role of advanced imaging techniques in precise evaluation. We observed a notable prevalence of IPMNs and mucinous cystadenomas, emphasizing the need for rigorous management to differentiate benign lesions from potential malignancies. We acknowledge the limitations of our study, such as the relatively small sample size and data collection limited to a single center, and call for larger, multicenter studies to validate our findings. Technological advancements will continue to enhance diagnostic accuracy and management of pancreatic cystic tumors, offering promising prospects for clinical practice and long-term patient monitoring.

5. Conclusion:

Pancreatic cystic tumors present a daily challenge in gastroenterology, often discovered incidentally due to advancements in imaging techniques such as ultrasound and MRI. Endoscopic ultrasound (EUS) plays a crucial role in accurately characterizing these tumors and optimizing their management, with biopsy and guided aspiration techniques significantly enhancing diagnostic specificity. Our study confirmed a predominance of cystic tumors located in the pancreatic head, particularly IPMNs and mucinous cystadenomas, consistent with existing literature. Despite advances in imaging technology, EUS remains pivotal in the short and medium term for the management of pancreatic cystic tumors. The clinical implications of these findings highlight the need for close monitoring and individualized approaches for each patient, considering the

specific characteristics of the lesions and associated risks. Incidental discoveries of these tumors, often detected during examinations for other conditions, can lead to increased diagnostic anxiety and require appropriate follow-up to assess their malignancy potential. Future research should focus on conducting multicentric and longitudinal studies to better understand the progression of these tumors and refine surveillance and treatment protocols. The evaluation of new biomarkers and the improvement of imaging techniques could offer opportunities for earlier and more precise diagnoses. Additionally, comparative studies between different imaging modalities and management strategies could help establish more robust and standardized guidelines for the management of pancreatic cystic tumors

Conflict of interest:

The authors declare that there are no conflicts of interest related to this study. None of the authors have any financial or personal connections with organizations that could influence the results of this research

Ethical Approval:

As per international standards or university standards written ethical approval has been collected and preserved by the author(s).

Consent

As per international standards or university standards, patient(s) written consent has been collected and preserved by the author(s).

Disclaimer (Artificial intelligence)

Option 1:

Author(s) hereby declare that NO generative AI technologies such as Large Language Models (ChatGPT, COPILOT, etc) and text-to-image generators have been used during writing or editing of manuscripts.

Option 2:

Author(s) hereby declare that generative AI technologies such as Large Language Models, etc have been used during writing or editing of manuscripts. This explanation will include the name, version,

model, and source of the generative AI technology and as well as all input prompts provided to the generative AI technology

Details of the AI usage are given below:

- 1.
- 2.
- 3.

References:

- 1.** Frank H. Miller¹ , Camila Lopes Vendrami, Hannah S. Recht, Cecil G. Wood, Rajesh N. Keswani et al ;Pancreatic Cystic Lesions and Malignancy: Assessment, Guidelines, and the Field Defect ; Radio Graphics , Dec2021 , VOL42
- 2.** Kromrey, M.L.Bulow, R.Hubner, J. Paperlein, C.Lerc, M.M.Ittermann, et al . Prospective study on the incidence, prevalence and 5-year pancreatic-related mortality of pancreatic cysts in a population-based study. 2018, VOL: 67
- 3.** Catalina Vladuț, Dana Bilous , Mihai Ciocîrlan ;Real-Life Management of Pancreatic Cysts: Simplified Review of Current Guidelines J. Clin. Med. 2023,
- 4.** A. Lira-Treviñoa, I.G. Carranza Mendozab, J.P. Borbolla Ariztib, A. Soriano-Ríosa, L. Uscanga-Domíngueza, M. Peláez-Lunaa, ; Lesiones quísticas de páncreas. Diagnóstico diferencial y estrategia de tratamiento ; Revista gastroenterología Mexico; 2022
- 5.** Peter J. Allen, Associate Director for Clinical Programs, Rubenstein Center for Pancreatic Cancer Research, Memorial Sloan Kettering Cancer Center, New York, NY , The diagnosis and management of cystic lesions of the pancreas , December 04, 2017
- 6.** Danielle E. Kruse, and Erik K. Paulson, The Incidental Pancreatic Cyst, Korean J Radiol. online May 16, 2024
- 7.** Bartosz Bujala, Katarzyna Biskup, Sławomir Mrowiec, Žilvinas Dambrauskas, , Antanas Gulbinas, and Povilas Ignatavicius, , Pancreatic Cystic Tumors: A Single-Center Observational Study, Pub MED Published online 2023
- 8.** Abigail Schubach , Shivangi Kothari , Truptesh Kothari ,Department of Gastroenterology, University of Rochester Medical Center, Rochester, NY 14642, MDPI Journal / Published: 5 January 2023

- 9.** Canto M.I.; Hruban R.H.; Fishman E.K.; Kamel I.R.; Schulick R.; Zhang Z et al. Frequent Detection of Pancreatic Lesions in Asymptomatic High Risk. *Gastroenterology* 2012, vol:142
- 10.** Aline Falqueto, Gustavo Lemos Pelandré, Mariânges Zadrozny Gouvêa da Cost, Marcelo Souto Nacif, Edson Marchiori, Prevalence of pancreatic cystic neoplasms on imaging exams: association with signs of malignancy risk, *Radiologia Brasileira*, Jul-Aug 2018
- 11.** Jennifer E. Verbese, J. Lawrence Munson, Pancreatic Cystic Neoplasms, Department of General Surgery, Lahey Clinic Medical Center, USA *matter Elsevier*, 2010
- 12.** Carlos Fernández-del Castillo, Javier Targarona, Sarah P. Thayer, David W. Rattner, William R. Brugge, and Andrew L. Warshaw, Incidental Pancreatic Cysts, *PUB MED central* 2015 Apr 20
- 13.** Feixiang Hu¹, Yue Hu, Dan Wang, Xiaowen Ma, Yali Yue, Wei Tang, et al, Cystic Neoplasms of the Pancreas: Differential Diagnosis and Radiology Correlation, *Global Excellence in Oncology: Asia and Australia* 01 March 2022
- 14.** Bartosz Bujala, Katarzyna Biskup, and Sławomir Mrowiec, Žilvinas Dambrauskas, Antanas Gulbinas, and Povilas Ignatavicius, Pancreatic Cystic Tumors: A Single-Center Observational Study, *Pub MED Published* 2023
- 15.** Dupas B, Le Borgue J. L'apport de la cholongiopancreatographie-IRM dans les tumeurs kystiques du pancréas. *Ann chir* 2000 VOL :125
- 16.** RENATA TALAR-WOJNAROWSKA, MAREK PAZUREK, LUKASZ DURKO, MALGORZATA DEGOWSKA, GRAZYNA RYDZEWSKA, JACEK SMIGIELSKI, et al ; Pancreatic cyst fluid analysis for differential diagnosis between benign and malignant lesions, *Oncol Lett.* 2013 VOL : 616
- 17.** S.S. Vege, B. Ziring, R. Jain, et al. American Gastroenterological Association Institute guideline on the diagnosis and management of asymptomatic neoplastic pancreatic cysts. *Gastroenterology*, 2015 VOL:149
- 18.** van Riet, P.A.; Larghi, A.; Attili, F.; Rindi, G.; Nguyen, N.Q.; Ruszkiewicz, A et al. A Multicenter Randomized Trial Comparing a 25-Gauge EUS Fine-Needle Aspiration Device with a 20-Gauge EUS Fine-Needle Biopsy Device. *Gastrointest. Endosc.* 2019
- 19.** William R. Brugge MD. Diagnosis and management of cystic lesions of the pancreas, *Journal of Gastrointestinal Oncology*, 2015

- 20.** Laura D. Wood , N. Volkan Adsay , Olca Basturk , Lodewijk. A.A , Brosens , Noriyoshi Fukushima et al . Systematic review of challenging issues in pathology of intraductal papillary mucinous neoplasms , Pancreatology ELSIVIER , November 2023 ; Volume 23
- 21.** Tsuyoshi Hamada , Hiroki Oyama , Yousuke Nakai , Shuichi Tange , Junichi Arita , Ryunosuke Hakuta , et al , Clinical Outcomes of Intraductal Papillary Mucinous Neoplasms With Dilatation of the Main Pancreatic Duct , Clinical Gastroenterology and Hepatology ; 2023 , VOL:21
- 22.** Srinivas Bojanapu , Anup Kasi ; Pancreatic Mucinous Cystadenoma ; Sir Ganga Ram Hospital ; National Library Of Medicine , July 14, 2023.
- 23.** Ross C.D. Buerlein and Vanessa M. Shami , Management of pancreatic cysts and guidelines: what the gastroenterologist needs to know , sage journals 2021
- 24.** Xiaoyue Lu, Hao Chen & Taiping Zhang ; Solid pseudopapillary neoplasm (SPN) Of the pancreas : current understanding on its malignant potential and management ; SPINGLER LINK , March 2024
- 25.** Kylie Ning , Ashley Salamone , Lindsey Manos ,Kelly J. Lafaro, Elham Afghani ; Serous Cystadenoma: A Review on Diagnosis and Management J. Clin. Med. 2023 , VOL:23
- 26.** Banks PA, Bollen TL, Dervenis C, et al. Classification of acute pancreatitis–2012: revision of the Atlanta classification and definitions by international consensus. Gut 2013; Vol 62