

Low-Grade Appendiceal Mucinous neoplasm causing pseudomyxoma peritonei and review.

Abstract

Mucocele of the appendix is an obstructive dilatation of the appendix caused by the accumulation of mucinous material within the lumen. This rare condition occurs in 0.2-0.7% of all appendectomy specimens and is most commonly seen in individuals aged 50-60 years. Surgical intervention is always required and depends on the integrity and size of the appendix, base as well as the histological type of the original lesion. The prognosis is favourable if the appendix remains intact. However, perforation and subsequent leakage of its contents into the abdominal cavity can lead to pseudomyxoma peritonei, a condition with a very poor prognosis if not properly treated.

Low-grade appendiceal mucinous neoplasm (LAMN) is a rare condition, affecting approximately 1% of patients undergoing appendectomy. While LAMN is often asymptomatic, it can rupture and release mucin and neoplastic epithelial cells into the peritoneum, leading to pseudomyxoma peritonei. This condition produces abundant mucin or gelatinous ascites, commonly referred to as “Jelly-belly” syndrome.

Patients with LAMN without perforation have a better prognosis. However, those with perforation may experience symptoms similar to appendicitis, including pain in the right iliac fossa, fever, nausea, and vomiting. Increased mucin within the appendix lumen may present as a palpable mass or be diagnosed incidentally during an appendectomy.

For early-stage, non-perforated LAMN, a simple appendectomy is often adequate. In advanced stages, treatment may include appendectomy, right hemicolectomy, peritonectomy, and additional hypothermic intraperitoneal chemotherapy (HIPEC).

We report a rare case of low-grade appendiceal mucinous neoplasm leading to pseudomyxoma peritonei in a 56-year-old male patient. The diagnosis was made via ultrasonography and CT abdomen, identifying a perforated mucocele of the appendix.

Key words

Mucocele of appendix, Mucinous neoplasm, Pseudomyxoma peritonei, Low grade mucinous neoplasm, Hyperthermic intraperitoneal chemotherapy (HIPES).

Introduction

Perforation of mucocele of the appendix can occur spontaneously or intra-operatively. This may lead to the spread of mucin, epithelial cells or both, throughout the peritoneal cavity, resulting in pseudomyxoma peritonei, which can cause life threatening complication. Therefore, prompt diagnostic imaging and surgical treatment are crucial. [1,2,5]

Low-grade appendiceal mucinous neoplasm (LAMN) is an uncommon tumor of the appendix, typically diagnosed incidentally after surgery, and found in approximately 1% of appendectomy specimens. It accounts for nearly 0.05% of all gastrointestinal neoplasms. In 50% of cases, LAMN

has features with acute appendicitis, whereas some are asymptomatic and are generally detected incidentally on CT and MRI. [2,3,5]

LAMNs are more commonly diagnosed in men, particularly in their sixth decade of life. These neoplasms do not metastasize hematogenously or lymphatically but can disseminate within the abdominal cavity due to perforation, leading to an accumulation of mucin known as pseudomyxoma peritonei. [1,2]

McDonald et al. classified LAMNs into two types:

1. **LAMN Type I:** Mucin is contained within the lumen of the appendix.
2. **LAMN Type II:** Mucin can be found in the appendiceal wall or, in advanced stages, widely distributed in the abdominal cavity. [5,6]

In early, non-perforated stages (Type I) of LAMN, appendectomy is typically adequate therapy. In advanced stages (Type II), treatment may involve appendectomy, cytoreductive surgery, and hyperthermic intraperitoneal chemotherapy (HIPEC). [1,2,5]

Mucinous lesions due to hyperplasia (serrated polyps) or retention cysts (simple mucocele) are not associated with recurrence once they rupture. However, rupture of neoplastic mucinous lesions such as LAMNs, high-grade appendiceal mucinous neoplasms (HAMNs), or mucinous adenocarcinomas can lead to progressive intraperitoneal spread and accumulation of both mucinous ascites and neoplastic cells, resulting in pseudomyxoma peritonei. [1,2,4]

The epithelial lining of a simple mucocele is normal, lacking dysplasia, but may show flattened cells with abundant mucinous content. **The Peritoneal Surface Oncology Group International (PSOGI)** provides the following classification for appendiceal mucinous lesions: [4,6]

Non-neoplastic Appendiceal Mucinous Lesions

- **Simple mucocele or retention cysts:** Characterized by degenerative epithelial changes due to obstruction (e.g., fecalith) and distension, without mucosal hyperplasia or neoplasia. Also called inflammatory or obstructive mucocele. [1,2,5]

Neoplastic Appendiceal Mucinous Lesions

- **Serrated polyps of the appendix:** With or without dysplasia, referred to as hyperplastic polyps or mucosal hyperplasia.
- **Mucinous appendiceal neoplasms:** Cytoplasmic mucinous tumors confined to the mucosa, propria, and serosa of the appendix. These tumors can be classified as low-grade appendiceal mucinous neoplasm (LAMN) or high-grade appendiceal mucinous neoplasm (HAMN).
- **Mucinous adenocarcinomas of the appendix:** Characterized by frankly infiltrative invasion, classified into well, moderately, or poorly differentiated categories. Mucinous adenocarcinoma is defined by invasive glands containing high-grade cytology. [1,2,5,6]

Diagnosis

Imaging modalities for diagnosis include ultrasound, CT and MRI. CT abdomen is most commonly used modality for diagnosis. The common abdominal CT findings included cystic dilation within the appendiceal lumen with wall calcification and irregular appendiceal wall thickening. Grossly swollen appendix, secondary to mucinous accumulation. [2,3,7]

Lymph node metastasis is a rare occurrence in only 4.2% of patients and require an aggressive treatment. [1]

Case Report

A 56-year-old male patient was admitted to our center on 06/06/2024, presenting with complaints of right iliac fossa pain, mild fever, and a single episode of vomiting over the past four days. On physical examination, he exhibited pain in the right lower quadrant of the abdomen, mild muscle rigidity, and rebound tenderness. His body temperature was 37.5°C, and laboratory tests revealed leucocytosis with increased neutrophils, while other tests were normal.

Ultrasound imaging showed a tubular, non-compressible cystic structure measuring 3.6 cm in length and 1.4 cm in width, with a wall defect of 4 mm at the distal end of the appendix. There was fluid collection in the right paracolic gutter and pelvis, with septations and internal echoes, indicating a mucocele with perforation. CT abdomen confirmed a blind-ending tubular structure in the right iliac fossa with a wall thickness of 2 mm and fluid accumulation. There was free fluid, thick and echogenic, in the right paracolic gutter and pelvic cavity with septations and internal echoes.

A laparoscopic procedure was performed under general anesthesia. A 10 mm intra-umbilical port was placed after the insertion of a Veress needle, creating a pneumoperitoneum with carbon dioxide to a pressure of 14 mm Hg. A second 10 mm port was inserted through the left supra-pubic region, and a third 5 mm port was inserted in the right iliac fossa. The procedure revealed a perforated mucocele of the appendix at the tip, with pseudomyxoma peritonei seen in the right paracolic gutter and pelvis. All mucinous gelatinous fluid, measuring 250 ml, was completely aspirated through the suction tube. After division of the mesoappendix, a laparoscopic appendicectomy was performed using a harmonic scalpel, and the entire specimen was removed using an endobag to avoid contamination.

Gross examination revealed an irregular appendix covered with mucin, partially disrupted, and measuring approximately 5x4.5x2 cm. The proximal part was dilated up to the stump, with the serosa covered.

Histopathology revealed a mucinous neoplasm with a villiform surface mucosal configuration lined by dysplastic mucinous epithelium. The proximal cut margin at the base of the appendix was involved, and peritoneal fluid was positive for mucin and mucinous epithelial cells. It was diagnosed as low-grade appendiceal mucinous neoplasm with serosal perforation. Tumor involvement was noted in the appendiceal serosa and the proximal margin. It was staged as T4b low-grade appendiceal mucinous neoplasm, characterized by hyperchromatic nuclei with minimal mitotic activity.

The patient was discharged on the fourth post-operative day. Following the pathology report of low-grade appendiceal mucinous neoplasm (LAMN), grade T4b, the patient was referred to a higher cancer center for cytoreductive surgery and heated intraperitoneal chemotherapy (HIPEC). (**Fig 1-16**)

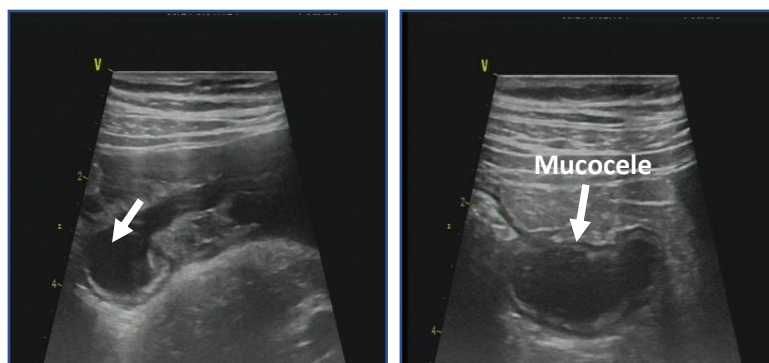


Fig-1,2 Ultrasound imaging showed a tubular, non-compressible cystic structure (mucocele) at RIF of size 3.6x1.4 cm

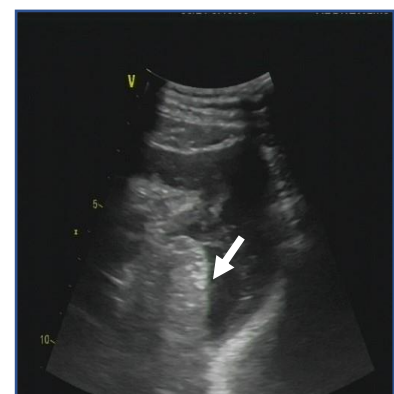

Fig-3 Ultrasound showed collection in pelvis with septations and internal echoes

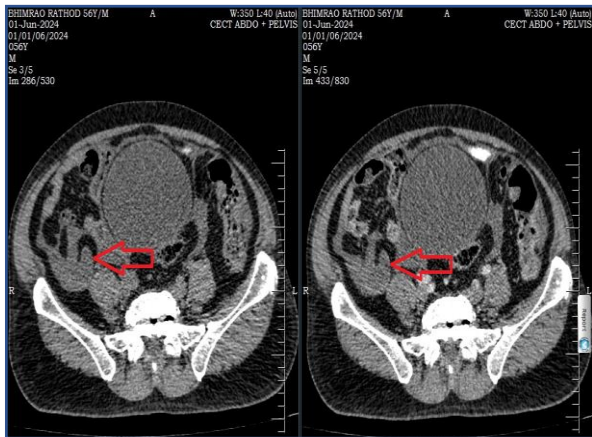


Fig-4,5 CT abdomen shows mucocoele of the appendix

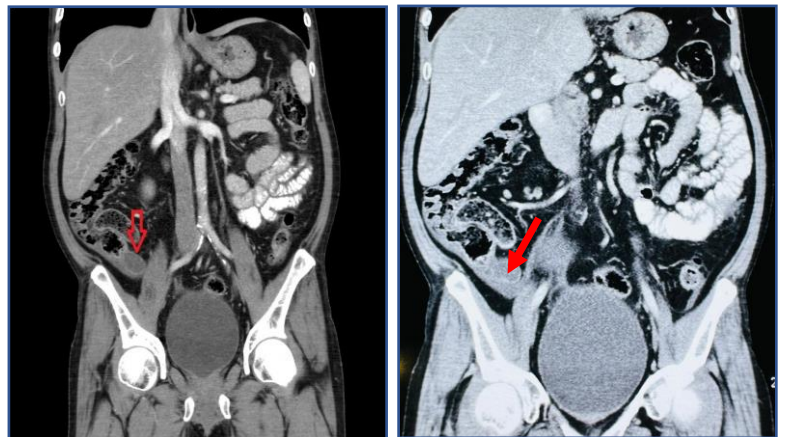


Fig-6,7 CT abdomen shows mucocoele of the appendix with perforation

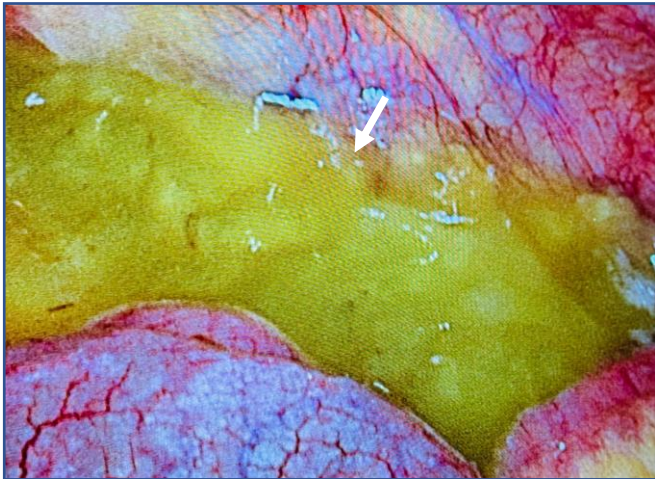


Fig-8 Intraoperative photographs shows mucinous jelly fluid at right paracolic gutter

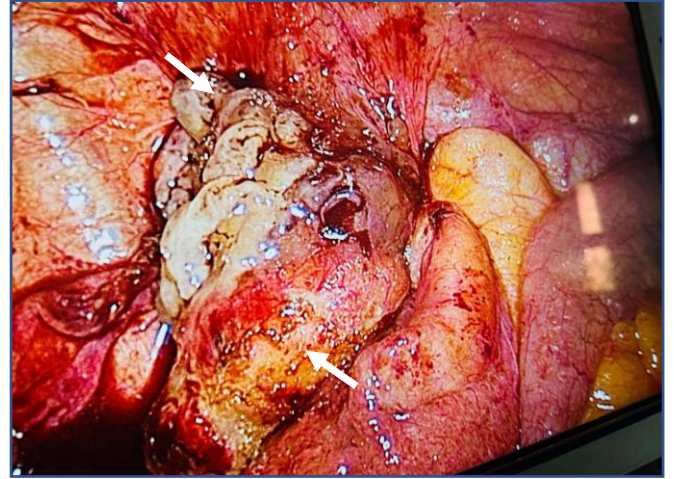


Fig-9 Intraoperative photographs shows mucocoele of the appendix with perforation

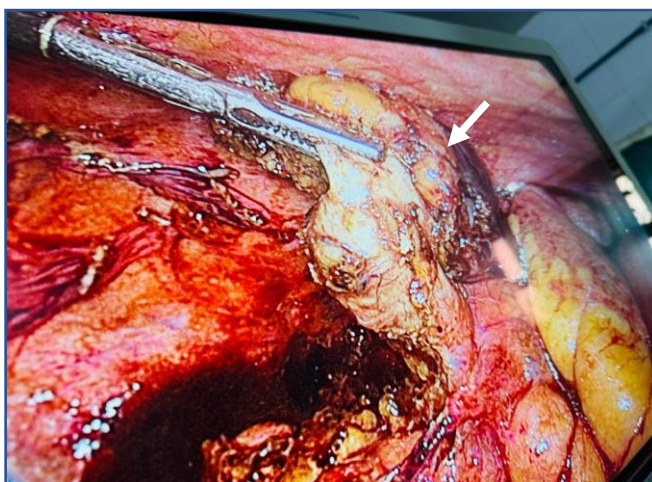


Fig-10 Total Laparoscopic resection of the appendix

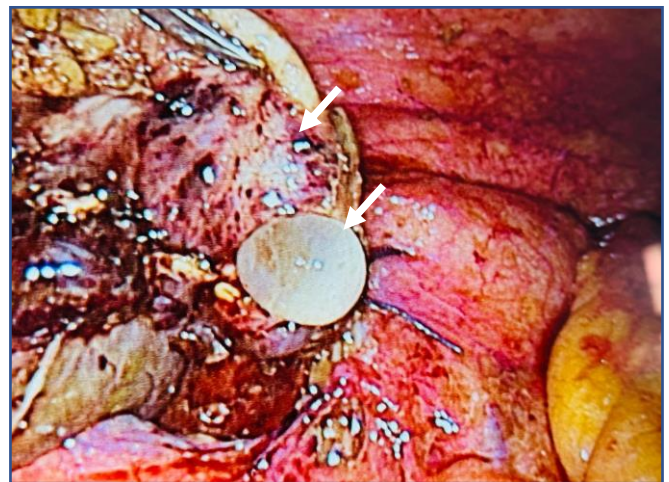

Fig-11 Intraoperative photographs showing appendix with mucinous fluid at base

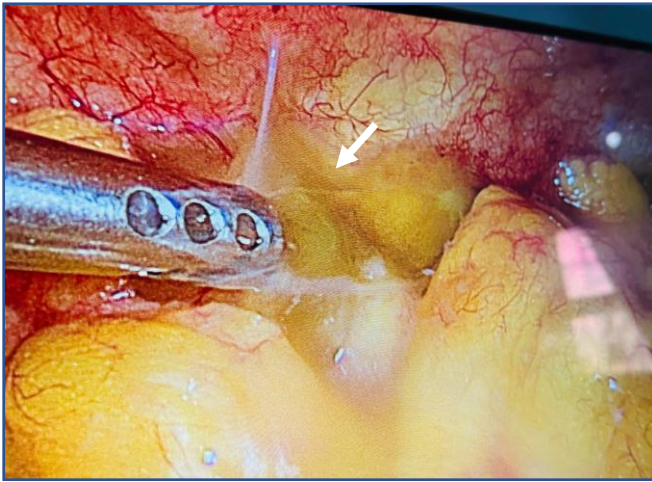


Fig-12 Intraoperative photographs showing suction of thick, mucinous jelly fluid

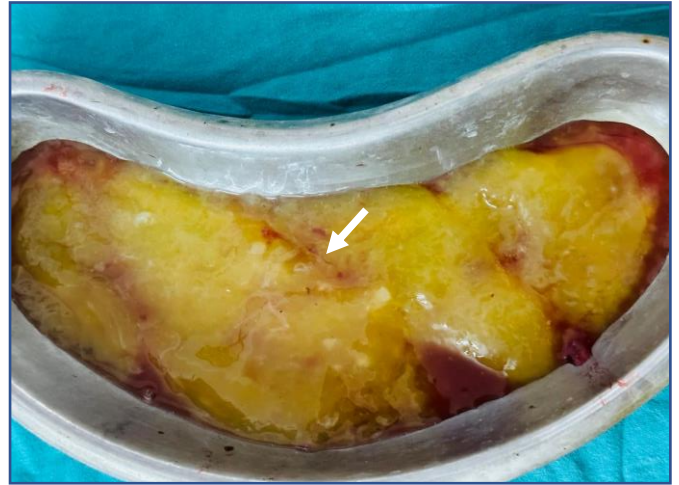


Fig-13 Photographs showing thick, mucinous gelatinous fluid, measuring 250 ml

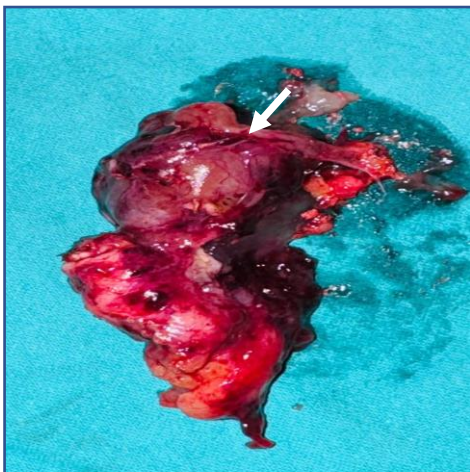


Fig-14 Photographs showing perforated mucocele of the appendix at tip

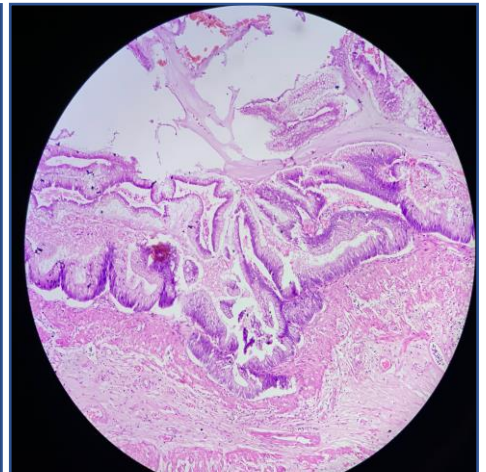
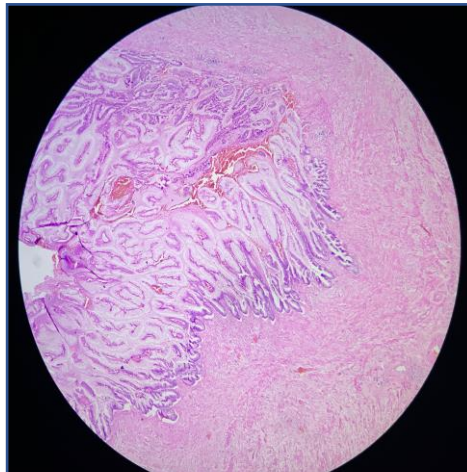


Fig-15,16 Histopathology revealed a low grade mucinous neoplasm with a villiform configuration lined by dysplastic mucinous epithelium

Discussion and review

Carl Rokitansky first described an appendiceal mucocele in 1842. In 1984, Werth coined the term pseudomyxoma peritonei in relation to a mucinous ovarian neoplasm. Eronkel described the first case associated with a cyst of the appendix in 1901. Notably, Audrey Hepburn died of pseudomyxoma peritonei in 1993. [1,2]

Pathological Staging for LAMN

Low-grade appendiceal mucinous neoplasm (LAMN) is distinct from other gastrointestinal tumors as it does not have T1 or T2 stages. The tumor stages for LAMN include Tis, T3, and T4:

1. **Tis LAMN:** Tumor cells or the mucin they produce are seen touching or invading the muscularis propria.
2. **T3 LAMN:** Tumor cells or mucin extend through the muscularis propria into the fat below the serosa.
3. **T4 LAMN:** Tumor cells or mucin have broken through the serosa into the abdominal cavity. This stage is further divided into:

- **T4a:** Tumor cells have broken through the serosa but are not seen in nearby organs.

- **T4b:** Tumor cells or mucin are found in nearby organs. [4,5,6]

Nodal Stage

LAMN is assigned a nodal stage between N0 to N2, based on the number of lymph nodes containing tumor cells. Lymph node involvement is extremely rare in LAMN.

Pathophysiology of Pseudomyxoma Peritonei

Pseudomyxoma peritonea is a rare type of cancer that affects peritoneal cavity and it is also called “False mucinous tumor of the peritoneum” it is called a false tumor because this cancer does not actually grow in to solid tumors, Instead, it spreads by continually producing mucin a jelly like substance. The mucin gradually accumulates in the peritoneal cavity of abdomen and pelvis, so called “jell belly” syndrome. [1,2,5]

The cancer begins as a polyp inside the appendix. Cancer cells secrete mucin, causing a mucocele that eventually bursts into the peritoneal cavity. Floating mucin and epithelial cells implant in various parts of the peritoneal cavity, producing mucin and leading to mucinous ascites, known as "jelly-belly" syndrome. Cells move with the peritoneal fluid and by gravity, with tumor deposits in the retro-vesical pouch (pouch of Douglas), paracolic gutters, sub-hepatic spaces, and greater and lesser omentum, leading to the development of omental cakes. The accumulation of large volumes of mucin inside the abdomen causes compression of visceral organs, resulting in intestinal obstruction, pain, malnutrition, and cancer cachexia which leads to death. [1,7,8]

In 2016, a classification system widely recognized by peritoneal carcinomatosis experts divided pseudomyxoma peritonei into four categories:

1. Acellular mucin
2. Low-grade mucinous carcinoma peritonei
3. High-grade mucinous carcinoma peritonei or peritoneal mucinous carcinomatosis
4. High-grade mucinous carcinoma peritonei with signet ring cells. [4,5, 9]

Treatment

1. Localized disease -

Low-grade appendiceal mucinous neoplasms are benign, non-invasive epithelial proliferations of the appendix. These usually present clinically as mucocele and rarely exceed 2 cm in diameter. Lesions confined to the lumen are low-grade and tend to be less aggressive. LAMNs confined to the appendix have a recurrence rate of 3%-7%. Surgical removal of the appendix, with care to prevent the spillage of mucin, is warranted in these cases. The goal of management of LAMN includes preventing rupture, seeding, and the development of pseudomyxoma peritonei. Appendectomy is the preferred approach for treating benign appendiceal mucocele. [1,2,12]

If the base of the appendix is involved in the disease process, preventing a clear margin from being achieved, a right hemicolectomy is performed to achieve a negative resection margin. Ruptured lesions may result in peritoneal dissemination of neoplastic cells; thus, careful handling and resection of the lesion during surgery are paramount. After resection, the appendix should be placed in a retrieval bag before extraction. [3,5]

2. **Ruptured lesions** - as rupture of an appendiceal mucinous lesion may result in peritoneal dissemination of neoplastic cells, careful handling and resection of the lesion during surgery is paramount, after the appendix is resected, it should be placed in a retrieval bag before extraction

T4a LAMN patients with either acellular or cellular mucin outside of the appendix or a ruptured tumor, the risk of subsequent pseudomyxoma peritonei is higher. In these patients, cytoreductive surgery (CRS) and heated intraperitoneal chemotherapy (HIPEC) are recommended to treat peritoneal disease. [2,4,11]

In the 1990s, Sugarbaker introduced the concept of a one-stage aggressive cytoreductive debulking procedure via several macroscopic peritonectomies, followed by intraoperative HIPEC infusion. A high dose of heated (40-42°C) chemotherapeutic agents is perfused intraoperatively throughout the abdomen to eradicate any residual microscopic cancer cells. The most commonly used

agents are mitomycin-C or oxaliplatin. Combining CRS and HIPEC therapy has resulted in a 5-year survival rate of 50-86%. [1,2,3]

Appendectomy and right hemicolectomy are proposed for cases of an unruptured appendix, while cytoreductive surgery (CRS) and hyperthermic intraperitoneal chemotherapy (HIPEC) are performed in ruptured cases with pseudomyxoma peritonei. [5,6,10]

Prognosis and follow up

Survival is excellent after standard appendectomy for non-neoplastic appendiceal mucinous lesions. Completely resected LAMNs rarely recur. Patients with any acellular mucin deposit on the visceral peritoneal surface of the appendix have a recurrence rate of 3 to 7%.

While for those with cellular mucin outside of the appendix, the risk is higher and ranges from 33 to 78%. The five-year overall survival is 86%.

Follow up should continue for 5 to 10 years with physical examination, annual CT and monitoring of tumor markers. Elevated CEA, Ca 19.9 and Ca 125 may be detected in 56.1 to 67.1% of patients with LAMN. [4,5,8]

Conclusion

Low-grade appendiceal mucinous neoplasms (LAMNs) are rare tumors of the appendix, often presenting with clinical symptoms similar to acute appendicitis. The presence of mucocele of the appendix with perforation, acellular mucin on the serosa, and positive surgical margins are high-risk factors for the development of pseudomyxoma peritonei, which is associated with high mortality.

For LAMNs confined to the appendix, an appendectomy is sufficient for management. However, for ruptured lesions with pseudomyxoma peritonei classified as stage T4a and T4b, and once pseudomyxoma peritonei is detected, the treatment of choice is cytoreductive surgery (CRS) combined with heated intraperitoneal chemotherapy (HIPEC).

References

1. Guner M, Aydın C. Low-Grade Appendiceal Mucinous Neoplasm: What Is the Best Treatment? *Cureus*. 2023 Oct 6;15(10):e46591. doi: 10.7759/cureus.46591. PMID: 37808597; PMCID: PMC10560074.
2. Gonzalez HH, Herard K, Mijares MC. A Rare Case of Low-grade Appendiceal Mucinous Neoplasm: A Case Report. *Cureus*. 2019 Jan 29;11(1):e3980. doi: 10.7759/cureus.3980. PMID: 30967980; PMCID: PMC6440557.
3. Samuel J, Ballentine, Jacquelyn Carr, Eliahu Y. Bekhor, Umut Sarpel, Alexandros D. Polydorides, Updated staging and patient outcomes in low-grade appendiceal mucinous neoplasms, <https://doi.org/10.1038/s41379-020-0628-7>.
4. Wang A S, Ismael H N, Parikh J, et al. (September 03, 2022) Low-Grade Appendiceal Mucinous Neoplasm: A Case Series. *Cureus* 14(9): e28755. doi:10.7759/cureus.28755
5. Feely M, Gonzalez RS. LAMN and HAMN. PathologyOutlines.com website. <https://www.pathologyoutlines.com/topic/appendixmucinousneoplasm.html>. Accessed August 3rd, 2024.
6. Loftus TJ, Raymond SL, Sarosi GA, Croft CA, Smith RS, Efron PA et al (2017) Predicting appendiceal tumors among patients with appendicitis. *J Trauma Acute Care Surg* 82(4):771–775

7. Nasib Al Shibli, Ahmed Badrand Bader M.N.Albilasi, Low-Grade Appendiceal Mucinous Neoplasia:ARare Case Report, European Journal ofMedical and Health Scienceswww.ejmed.org
8. Ahuja, Manisha; Mandal, Shramana; Mallya, Varuna; Singh, Meeta; Khurana, Nita; Lal, Pawanindra. Low-grade appendiceal mucinous neoplasms: Histomorphological spectrum in a tertiary care hospital. *Journal of Cancer Research and Therapeutics* 20(3):p 840-843, Apr-Jun 2024. | DOI: 10.4103/jert.jert_149_22
9. Boshnaq M, Toeima M, Hamade A, Bagla N. Local protocol for management of low-grade appendiceal mucinous neoplasm (LAMN). *Indian J Surg Oncol* 2020; 11:355-9
10. Salapathi, S & Rajeshwari, B & Niamath, Sadiya & Ghosh, Mitra. (2021). Low Grade Appendiceal Mucinous Neoplasms- A Short Case Series with Review of Literature. *Annals of Pathology and Laboratory Medicine*. 8. C43-49. 10.21276/apalm.2954.
11. Priya Dharshini R, Neha Agarwal, Vimal Chander R, An Incidental Finding of Low-Grade Appendiceal Mucinous Neoplasm in a Case of Borderline Brenner Tumor of the Ovary, *Cureus*, 10.7759/cureus.61151, (2024).
12. Shaib WL, Assi R, Shamseddine A, Alese OB, Staley C 3rd, Memis B, Adsay V, Bekaii-Saab T, El-Rayes BF. Appendiceal Mucinous Neoplasms: Diagnosis and Management. *Oncologist*. 2017 Sep;22(9):1107-1116. doi: 10.1634/theoncologist.2017-0081. Epub 2017 Jun 29. Erratum in: *Oncologist*. 2018 Jan;23(1):137. doi: 10.1634/theoncologist.2017-0081erratum. PMID: 28663356; PMCID: PMC5599200.