

Case report

Eruptive xanthoma as alarming sign of hypertriglyceridemia in poorly controlled type 2 diabetes mellitus

Abstract:

Eruptive xanthomas may be the phenotypic expression of severe hypertriglyceridemia and are usually located on the surfaces of the extensor areas and buttocks. We present a case of eruptive xanthomas in the extensor areas of the arms and legs associated with severe hypertriglyceridemia in an adolescent diagnosed with diabetes mellitus who was admitted for diabetic ketoacidosis (DKA). After the management of DKA, the use of maintenance insulin therapy and lipid-lowering agents were initiated with a marked reduction in triglycerides and significant improvement in eruptive xanthomas. Proper management of DM and rapid reduction of triglyceride levels were essential in preventing complications such as acute pancreatitis.

This article highlights the importance of an adequate management of the diabetic patient and the clinical suspicion of severe hypertriglyceridemia in patients with eruptive xanthoma.

Keywords: Eruptive xanthoma, hypertriglyceridemia, type 2 diabetes mellitus

Introduction:

Eruptive xanthoma is a benign lesion, the result of subcutaneous accumulation of lipids (histologically characterized by foam cells accompanied by a variable mixed inflammatory infiltrate of lymphocytes and neutrophils), usually occurring on the extensor surfaces of the extremities and buttocks; and, generally, associated with severe hypertriglyceridemia (values greater than 1000 mg/dl)^{1,2}. Severe hypertriglyceridemia is usually observed in primary and secondary dyslipidemias; secondary dyslipidemia includes poorly controlled diabetes mellitus (DM), an entity in which patients can present with acute pancreatitis, hyperosmolar coma or DKA³. We present the case of a diabetic adolescent with severe hypertriglyceridemia and eruptive xanthoma, which to our knowledge is the first to be reported in our country.

Case Report:

17-year-old female adolescent, from Lima, initially diagnosed in another institution as type 1 diabetes mellitus vs MODY at the age of 13 years 6 months, medicated with metformin for 6 months and then only with dietary measures during the COVID 19 pandemic. She is a child as a result of a twin pregnancy, which was also a first pregnancy, pre-term 35 weeks with adequate weight for gestational, did not receive breastfeeding, had normal psychomotor development, bronchial obstructive syndrome at 3 months and menarche at 11 years; there is no history of type 1 diabetes mellitus or autoimmunity in the parents, her sister has been diagnosed with insulin resistance and two of her paternal uncles have been diagnosed with DM2. At 16 years 8 months, she was hospitalized for diabetic ketoacidosis, showing xanthomas in the extensor areas of the upper and lower limbs, and laboratory tests finding triglycerides > 4,300 mg/dl, Total cholesterol: 691 mg/dl, HDL-c: 11 mg/dl, LDL-c: 206 mg/dl, HbA1c: 12.6%, and C-peptide: 0.92. (see table 1). Once the DKA condition was resolved, she was discharged with indication for insulin therapy (intermediate/rapid acting - NPH/R-), atorvastatin, etezimibe and acetylsalicylic acid.

She is admitted to our institution at 17 years old, showing height/age in the 5th percentile and BMI in the 50/75th percentile, Tanner V, multiple xanthomas in the extensor areas of the arms and legs (photo); and glycemic controls between 250 - 350 mg/dl. Due to poor glycemic control, the insulin therapy regimen was changed to degludec/R and nutritional counseling was reinforced, limiting the intake of easily absorbed sugars and saturated fats, and favoring the consumption of unsaturated fats, whole grains, fruits and legumes. The evolution shows a diagnosis of type 2 diabetes mellitus; and after 5 months and with good adherence to the treatment, clinical improvement of the xanthomas is observed and the laboratory results show a decrease in the lipid profile and HbA1c values to 8.9% (see table 1).

Table 1. Laboratory results before and after treatment in a diabetic patient presenting with eruptive xanthomas and severe hypertriglyceridemia.			
	Unit	Pre treatment	Post treatment (after 5 months)
Basal bloodglucose	mg/dl	329	184
HbA1c	%	12.6	8.9
Total cholesterol	mg/dl	691	129
c-HDL	mg/dl	11	28
c-LDL	mg/dl	206	74
Triglycerides	mg/dl	>4300	137
ALT	U/L	-	98
AST	U/L	-	55
Alkalinephosphatase	U/L	-	316
Totalproteins	g/dl	-	8.0
Albumin			4.9
Globulin			3.1
TSH	uUI/mL	3.26	1.8
T4 free	pmol/L	-	13.1
ATPO	UI/ml		< 10
ATg	UI/ml	18.41	< 20
Péptide C	ng/ml	0.92	2.57
Microalbuminuria	mg/24 hr		Negative
Skin biopsy		Eruptivexanthoma	
Electrophoreticlipidogram	alpha:9.8-52 % Pre-beta: 4-35% Beta= 36-62%.	-	alfa: 8.3 % Pre-beta:29.7% Beta=62.0%

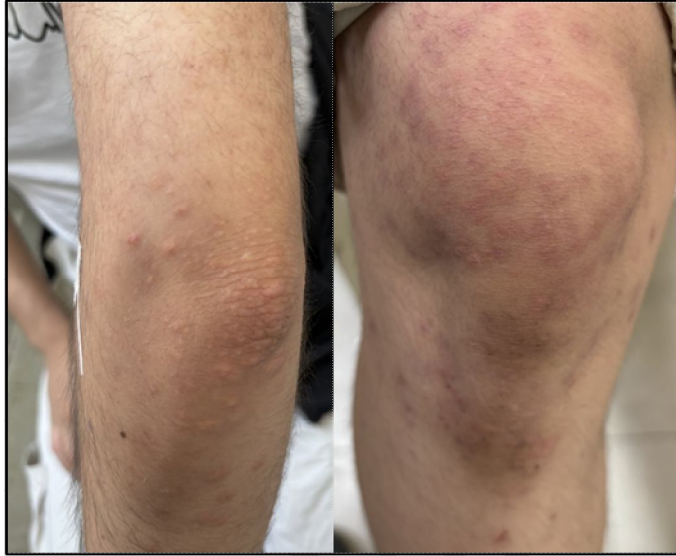


Photo1. Eruptive xanthomas on the elbows and knees of a diabetic patient with severe hypertriglyceridemia.

Discussion

The main risk factor for the development of eruptive xanthomas is severe hypertriglyceridemia, as in our patient, Sandhu et al. found that 8.5% of patients with serum triglyceride values greater than 20 mmol/L (1772 mg/dl) developed xanthomas that improved after reducing triglyceride levels⁴. The result of severe hypertriglyceridemia is intra- and extracellular lipid deposits as a consequence of a deficiency in lipoprotein lipase (LPL) activity, which may be due to a primary or secondary deficiency to a decreased insulin activity as in the case of Mellitus diabetes. Implicit in the latter are, on the one hand, the clearance of chylomicrons that leads secondarily to an increase in very low-density lipoproteins and hypertriglyceridemia; and on the other, the lack of action or resistance to insulin leading to an acquired deficiency of lipoprotein lipase⁵.

In the present case, the xanthomas are evident during the presentation of DKA as a result of poor DM metabolic control, an observation similar to that of Tsuchiya et al, who report eruptive xanthomas in a 15-year-old male adolescent, obese and with history of consumption of sugary drinks that presented ketosis at the onset of DM2⁶; both cases being evidence that eruptive xanthomas are a sign of poor regulation of both lipid (hypertriglyceridemia) and glucose metabolism (type 2 diabetes mellitus) .

The pathophysiological sequence is explained by the state of insulin insensitivity in extra adipose tissues that decreases lipoprotein lipase activity by activating angiopoietin-like protein 3 (ANGPTL3) expressed in the liver, in turn, high ANGPTL3 activity would have induced elevations in serum levels of remaining lipoproteins, chylomicrons or LDL and VLDL^{5,7,8}, when these remnants infiltrate the blood vessels of the dermis, they are phagocytosed by macrophages, which, when transformed into foam cells, are deposited on the walls of the skin and cause the eruptive xanthoma symptoms observed in our patient⁹.

The main risks of severe hypertriglyceridemia are acute pancreatitis and cardiovascular events; Parhofer et al¹⁰ demonstrated that triglyceride values greater than 1000 mg/dl increase the risk of developing acute pancreatitis, a situation that did not occur in our patient due to the management established with insulin therapy that would have restored the activity of the LPL and with the dietary measures that, by leading to weight loss, would have reduced triglyceride levels by up to 20%⁶. On the other hand, the drugs of choice to reduce serum triglyceride levels are omega-3 fatty acids, fibrates and niacin, however, in the present case and due to the presence of high levels of LDL-C, the use of ezetimibe was preferred, which, although it has less power in reducing triglyceride levels, is recommended to reduce LDL-C levels and the risk of atherosclerotic cardiovascular disease¹¹.

Although secondary dyslipidemias are observed in patients with diabetes mellitus with poor metabolic control, the observation of severe hypertriglyceridemia is very rare, so, as some researchers point out, it is advisable to investigate genetic factors and determine ApoE phenotypes related to severe hypertriglyceridemia^{6,13}, however, in our case this research was not carried out, which constitutes a limitation in this report.

Eruptive xanthomas have also been observed in poorly controlled adult diabetic patients with high levels of triglycerides¹²⁻¹⁴, the appearance of this clinical picture in adolescents could be related to the manifestation appearance of diabetes mellitus at younger ages, so more attention should be paid to the diagnosis and good metabolic control in this population group.

Conclusion

this report details our experience with a patient who presented eruptive xanthoma associated with severe hypertriglyceridemia and poorly controlled DM, which improved with the metabolic regulation of lipids and glucose.

Physicians are recommended to pay attention to the cutaneous manifestations of metabolic disorders, which may be warning signs of risks of short- and long-term morbidity and mortality.

Ethical Approval:

As per international standards or university standards written ethical approval has been collected and preserved by the author(s).

Consent

As per international standards or university standards, patient(s) written consent has been collected and preserved by the author(s).

Disclaimer (Artificial intelligence)

Option 1:

Author(s) hereby declare that NO generative AI technologies such as Large Language Models (ChatGPT, COPILOT, etc) and text-to-image generators have been used during writing or editing of manuscripts.

Option 2:

Author(s) hereby declare that generative AI technologies such as Large Language Models, etc have been used during writing or editing of manuscripts. This explanation will include the name, version, model, and source of the generative AI technology and as well as all input prompts provided to the generative AI technology

Details of the AI usage are given below:

- 1.
- 2.
- 3.

References

1. Zaremba J, Zaczekiewicz A, Placek W. Eruptive xanthomas. *Postepy Dermatol Alergol*. 2013;30(6):399-402. doi:10.5114/pdia.2013.39439
2. Marogi EP, Ohiomoba RO, Stone NJ. Eruptive Xanthomas: Importance of Recognition to Reduce Delay of Effective Triglyceride Reduction. *Am J Med*. 2022 Apr;135(4):444-447. doi: 10.1016/j.amjmed.2021.09.026. Epub 2021 Oct 31. PMID: 34732347.
3. Zhao C, Li H. Eruptive xanthoma associated with hypertriglyceridaemia and diabetes. *Aust J Gen Pract*. 2023 Jun;52(6):371-373. doi: 10.31128/AJGP-10-22-6587. PMID: 37291815.
4. Sandhu S, Al-Sarraf A, Taraboanta C, Frohlich J, Francis GA. Incidence of pancreatitis, secondary causes, and treatment of patients referred to a specialty lipid clinic with severe hypertriglyceridemia: a retrospective cohort study. *Lipids Health Dis*. 2011 Sep 11;10:157. doi: 10.1186/1476-511X-10-157.
5. Chahil TJ, Ginsberg HN. Diabetic dyslipidemia. *Endocrinol Metab Clin North Am*. 2006 Sep;35(3):491-510, vii-viii. doi: 10.1016/j.ecl.2006.06.002. PMID: 16959582. Villalón G, Martín JM, Monteagudo C, Alonso V, Montesinos E, Jordá E. Xantomas eruptivos en el debut de diabetes mellitus [Eruptive xanthomas after onset of diabetes mellitus]. *Actas Dermosifiliogr*. 2008 Jun;99(5):426-7. Spanish. PMID: 18501184.
6. Tsuchiya S, Sawada S, Takeda K, Takahashi K, Nakajima T, Kohata M, Kurosawa S, Satake C, Imai J, Kikuchi K, Aiba S, Katagiri H. Eruptive xanthomas in a patient with soft-drink diabetes mellitus and apolipoprotein E4/2. *Endocr J*. 2019 Jan 28;66(1):107-114. doi: 10.1507/endocrj.EJ18-0356. Epub 2018 Nov 2. PMID: 30393272.
7. Ohtaki S, Ashida K, Matsuo Y, Moritaka K, Iwata S, Nagayama A, Kawaguchi A, Koga H, Yoshinobu S, Hasuzawa N, Motomura S, Akiba J, Nakama T, Nomura M. Eruptive xanthomas as a marker for metabolic disorders: A specific form of xanthoma that reflects hypertriglyceridemia. *Clin Case Rep*. 2022 Apr 21;10(4):e05671. doi: 10.1002/ccr3.5671. PMID: 35474985; PMCID: PMC9021930.

8. Inukai K, Nakashima Y, Watanabe M, et al. ANGPTL3 is increased in both insulin-deficient and – resistant diabetic states. *BiochemBiophys Res Commun.* 2004;317(4):1075-1079. doi:10.1016/j.bbrc.2004.03.151 Shimamura M, Matsuda M, Kobayashi S, et al. Angiopoietin-like protein 3, a hepatic secretory factor, activates lipolysis in adipocytes. *BiochemBiophys Res Commun.* 2003;301(2):604-609. doi:10.1016/s0006 -291x(02)03058 -9
9. Zak A, Zeman M, Slaby A, Vecka M. Xanthomas: clinical and pathophysiological relations. *Biomed Pap Med FacUnivPalacky Olomouc Czech Repub.* 2014;158(2):181-188. doi:10.5507/bp.2014.016.
10. Parhofer KG, Laufs U. The diagnosis and treatment of hypertriglyceridemia. *DtschArztebl Int.* 2019;116(49):825-832. doi:10.3238/arzte bl.2019.0825
11. Santos-Baez LS, Ginsberg HN. Hypertriglyceridemia-Causes, Significance, and Approaches to Therapy. *Front Endocrinol (Lausanne).* 2020 Sep 2;11:616. doi: 10.3389/fendo.2020.00616. PMID: 32982991; PMCID: PMC7492386.
12. Kashif M, Kumar H, Khaja M. An unusual presentation of eruptive xanthoma: A case report and literature review. *Medicine (Baltimore).* 2016 Sep;95(37):e4866. doi: 10.1097/MD.0000000000004866. PMID: 27631252; PMCID: PMC5402595.
13. Shinozaki S, Itabashi N, Rokkaku K, Ichiki K, Nagasaka S, Okada K, Fujimoto M, Ohtsuki M, Ishibashi S. Diabetic lipemia with eruptive xanthomatosis in a lean young female with apolipoprotein E4/4. *Diabetes Res ClinPract.* 2005 Nov;70(2):183-92. doi: 10.1016/j.diabres.2005.03.023. Epub 2005 Apr 12. PMID: 16188578.
14. Solak B, Kara RO, Acikgoz SB, Kosem M. First and only symptom of undiagnosed diabetes mellitus: eruptive xanthoma. *BMJ Case Rep.* 2015 Sep 24;2015:bcr2015212160. doi: 10.1136/bcr-2015-212160. PMID: 26404550; PMCID: PMC4593248.