

Successful Percutaneous Coronary Intervention to a Totally Occluded Anomalous RCA originating from left sinus using Ikari catheter

ABSTRACT

AimThe right coronary artery (RCA), originating from the left sinus of Valsalva (LSOV), is a rare congenital anomaly seen in less than 3% of the total congenital coronary anomalies. They are usually asymptomatic, and some may present with symptoms due to ischemia, arrhythmias, or sudden cardiac death. This report is made to illuminate the utility of the Ikari left guiding catheter for use with anomalous RCA from the left sinus of Valsalva.

Case Presentation: A sixty-year-old female presented with an inferior wall myocardial infarction. Coronary angiogram through the right radial approach using a 5F tiger catheter revealed a normal left system with tortuosities in LAD. After many unsuccessful attempts with the tiger catheter, RCA was engaged with 3.0 JR and found to be arising from the left aortic sinus with the mid RCA cut off. We used a 3.0 IKARI left guiding catheter for engaging the RCA through the femoral route, and successful percutaneous coronary intervention was done on the first attempt using a single guiding catheter.

Discussion: The RCA arising adjacent to the ostium of the left main coronary artery is the most common and is a technical challenge to engage. A good selection of guiding catheters is important for a successful percutaneous coronary intervention (PCI). We have used the Ikari left guiding catheter (ILGC) in this case, which is a universal catheter suitable for both left and right coronary arteries.

Conclusion: There is no universal ideal guiding catheter for the engagement of all abnormal RCA origin cases. Ikari can usually be considered a preferred catheter for PCI to RCA arising from the left sinus (Type A) and is generally safe too.

Keywords: Anomalous RCA, RCA from Left sinus, PCI to anomalous RCA, Ikari left guiding catheter.

1. INTRODUCTION

"Congenital anomalies in the coronary artery are rare, seen in 0.2% to 1.2% of patients undergoing percutaneous coronary intervention (PCI). Among young athletes, they are the second-most common cause of sudden cardiac death (SCD)"¹. "The right coronary artery (RCA), originating from the left sinus of Valsalva is a rare congenital anomaly encountered in less than 3% of the total congenital coronary artery anomalies. Although anomalous RCA is more common than anomalous left coronary artery (LCA), its incidence in SCD is less than that of anomalous left coronary artery. They are usually asymptomatic, and some may present with symptoms due to ischemia, arrhythmias, or SCD. RCA compression at the proximal end by the aorta and pulmonary artery, an opening that looks like a slit at the origin, an abnormal RCA takeoff at the origin, and spasm of the proximal end may all cause symptoms"². Anomalous left circumflex coronary artery (LCX) originating from the right sinus of Valsalva can occur more frequently than an anomalous RCA from the left aortic sinus.^{3,4} This case report describes a patient with an anomalous RCA who presented with inferior wall myocardial

infarction (IWMI) and was successfully managed with PCI on the first attempt, using a single guiding catheter through the femoral route. We present this report to reaffirm the effectiveness of the Ikari left guiding catheter in treating anomalous RCA from the left sinus of Valsalva (SOV):

2. CASE PRESENTATION

A 60-year-old female was brought to the hospital with complaints of chest pain for 6 hours due to an inferior wall myocardial infarction. She was a **known case of systemic hypertension** on treatment. Electrocardiograms (ECG) and echocardiography were suggestive of inferior wall myocardial infarction (IWMI) along with right ventricular myocardial infarction (RVMI). The left ventricular ejection fraction (LVEF) was 42%. A coronary angiogram (CAG) was done. Her radial and subclavian arteries had a tortuous course, making it the first hurdle to cross with the guide wire. The guide wire was passed, and the left main coronary artery was engaged using a 5F tiger catheter. CAG of the left system was normal, with tortuosities in LAD. The right system was tried to engage with the tiger catheter. After many unsuccessful attempts, a 3.0 JR catheter was used to locate the RCA following multiple sinus shots. RCA was found to be arising from the left aortic sinus. CAG of the RCA revealed a mid-RCA cutoff. We used a 3.0 IKARI left guiding catheter for engaging the RCA through the femoral route during percutaneous coronary intervention (PCI). A 0.014 Rinato wire was used to cross the RCA lesion. Predilatation was done with a 2.25 x 10 mm balloon. Flow was established in the distal RCA, then the RCA lesion was stented with a 2.75 x 48 mm Everolimus drug-eluting stent. Post-dilatation was done with a 3x15-mm balloon. We successfully completed the procedure with the single use of the Ikari left guiding catheter (ILGC). The dye used was 200 ml. **Post-procedure** vitals were stable with normal renal function tests.

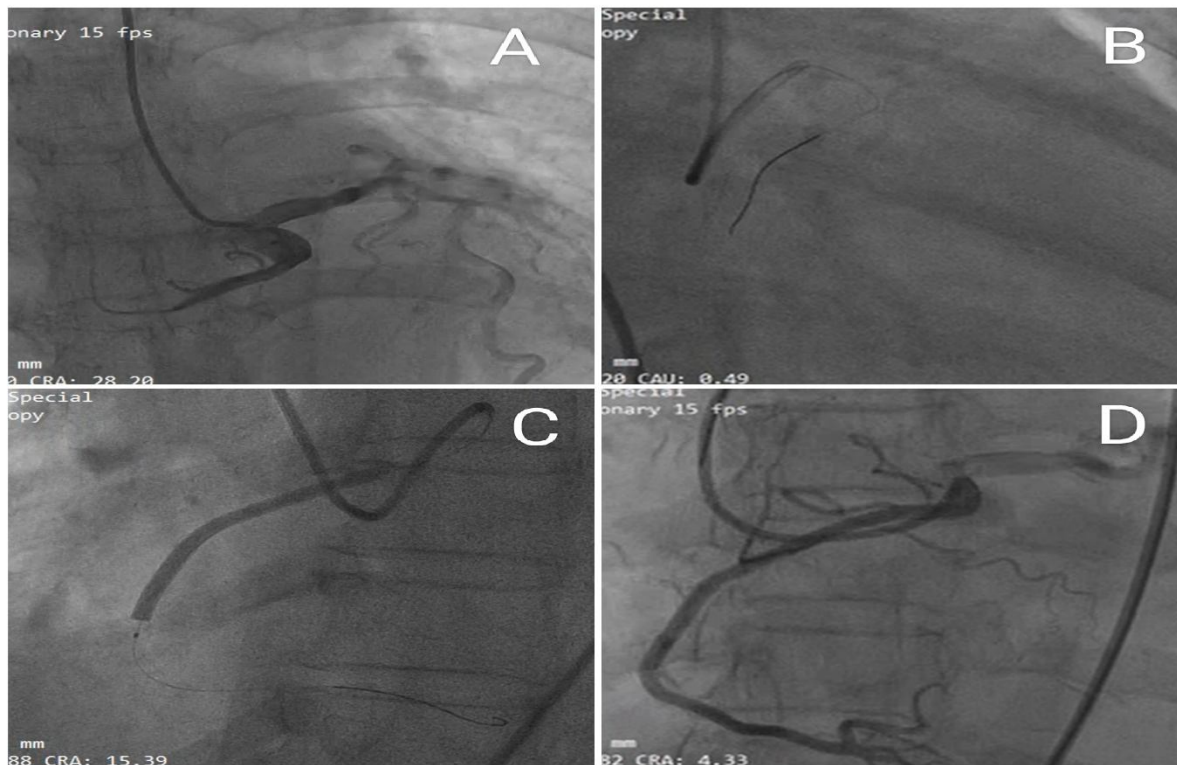


Fig. 1. A- RCA angiogram using 3.0 JR which shows RCA arising from left sinus with mid RCA cut off. B- PCI to RCA, engaging with Ikari left guiding catheter and passing guide wire (RAO Caudal). C- Stenting of RCA with 2.75x48mm Everolimus DES. D- RCA angiogram after post dilatation.

3. DISCUSSION

An anomalous RCA can originate from different locations within the Valsalva aortic sinuses. It is classified into various types. Location A: ostium of the RCA adjacent to the ostium of the left main coronary artery (LMCA) B: ostium of RCA inferior to LMCA ostium. C: ostium of RCA towards the commissure of the right and left aortic cusps. D: ostium of the RCA above the sinotubular plane. E: The ostium of the RCA extends from the superior right aortic cusp towards the left aortic artery. The most common RCA arising adjacent to the ostium of the left main coronary artery (location A) is a technical challenge to engage, as seen in this patient. The **Leva** catheter and the left coronary **Amplatz** at 45° or 90° in 7-F size are two of the best catheters for selectively engaging the RCA⁵. "A suitable selection of guiding catheters is important for successful PCI, either in transfemoral intervention (TFI) or transradial intervention (TRI). While the search for an ideal

universal or multi-purpose catheter is not new⁶⁻⁹, it remains unachieved. In anomalous RCA, the ostium is slit-like and usually lies anterior and cephalad to the left main coronary artery; it also takes an acute rightward course that prevents the coaxial engagement of most of the available catheters¹⁰. "Then consecutive five cases were successful indicating the excellent catheter design. The Ikari left guiding catheter (ILGC) incorporates three modifications compared to the Judkins left" (1) A new primary curve for the brachiocephalic artery. (2) The length between the third and fourth angles is shorter. (3) The length between the first and second angles is longer. In **trans-radial** procedures, the backup force of the Ikari left guiding is greater than the Judkins left (JL) due to the increased angle between the catheter and the reverse side of the aorta. ILGC in **trans-radial** procedures **give** more support than JL in transfemoral procedures¹¹. "Originally, ILGC was designed for **trans-radial** procedures for the left coronary artery, but it is also good for the RCA".¹² The ILGC is a universal catheter suitable for the left and right coronary arteries. One great benefit is lower cost because **of the use of** a single catheter in this procedure. Also, a shorter time for procedures might be vital in patients with ST-segment elevation myocardial infarction. A smart way to decrease door-to-balloon time is to use ILGC.¹³

"Even in elective cases, the average number of guiding catheters used in a single PCI of an anomalous RCA was three or more. The mean fluoroscopy time was 20.7 minutes, and the average amount of contrast used was 210 ml. The use of the Ikari left guide catheter is a simple and safe technique with a 100% procedural success rate for PCI of type A anomalous RCA arising from the left sinus of Valsalva"¹⁵.

4. CONCLUSION

There is no universal ideal guiding catheter for the engagement of all abnormal RCA origin cases. At times, different catheter exchanges may cause spasms or dissections of the RCA ostium. RCA ostial dissection in abnormal anatomy could be disastrous. Ikari can usually be considered a preferred catheter for PCI to RCA arising from the left sinus (Type A) and is generally safe too. If selective engagement cannot be achieved, a guiding catheter can be pointed (non-selectively) towards the ostium, and then the coronary guide wire passes through the ostium and down the coronary artery, followed by the advancement of the guide catheter.

Ethical Approval:

As per international standards or university standards written ethical approval has been collected and preserved by the author(s).

CONSENT

Authors declare that 'written informed consent was obtained from the patient/attenders for publication of this case report and accompanying images."

Disclaimer (Artificial intelligence)

Author(s) hereby declare that NO generative AI technologies such as Large Language Models (ChatGPT, COPILOT, etc) and text-to-image generators have been used during writing or editing of manuscripts.

REFERENCES

1. Kimbiris D., Iskandrian A.S., Segal B.L., Bemis C.E. "Anomalous aortic origin of coronary arteries". *Circulation* 1978;58:606-615.
2. Virmani R., Chun P.K., Goldstein R.E., Robinowitz M., McAllister H.A. Acute takeoffs of the coronary arteries along the aortic wall and congenital coronary ostial valve-like ridges: association with sudden death. *J Am Coll Cardiol.* 1984;3:766-771.
3. Anomalous origin of the right coronary artery from the left coronary sinus with an interarterial course: subtypes and clinical importance. Lee HJ, Hong YJ, Kim HY, et al. *Radiology.* 2012;262:101-108.
4. Anomalous aortic origin of a coronary artery from the inappropriate sinus of Valsalva. Cheezum MK, Liberthson RR, Shah NR, Villines TC, O'Gara PT, Landzberg MJ, Blankstein R. *J Am Coll Cardiol.* 2017;69:1592-1608.
5. Ben-Dor I, Weissman G, Rogers T, Slack M, Pichard A, Ben-Dor N, Hashim H, Bernardo N, Satler LF, Waksman R. Catheter Selection and Angiographic Views for Anomalous Coronary Arteries: A Practical Guide. *JACC Cardiovasc Interv.* 2021 May 10;14(9):995-1008. doi: 10.1016/j.jcin.2021.01.054. PMID: 33958174.

6. Shibata Y, Doi O, Goto T, Hase T, Kadota K, Fujii M, Zenke M, Fujii S, Ashida N, Sugioka J, Yamamoto H, Nishizaki M, Kameko M, Mitsudo K. New guiding catheter for transrad PTCA. *Cathet Cardiovasc Diagn.* 1998 Mar;43(3):344-51. doi: 10.1002/(sici)1097-0304(199803)43:3<344::aid-ccd24>3.0.co;2-k. PMID: 9535380.
7. Kim SM, Kim DK, Kim DI, Kim DS, Joo SJ, Lee JW. Novel diagnostic catheter specifically designed for both coronary arteries via the right transradial approach. A prospective, randomized trial of Tiger II vs. Judkins catheters. *Int J Cardiovasc Imaging.* 2006 Jun-Aug;22(3-4):295-303. doi: 10.1007/s10554-005-9029-8. Epub 2005 Nov 22. PMID: 16328852.
8. Louvard Y, Krol M, Pezzano M, Sheers L, Piechaud JF, Marien C, Benaim R, Lardoux H, Morice MC. Feasibility of routine transradial coronary angiography: a single operator's experience. *J Invasive Cardiol.* 1999 Sep;11(9):543-8. PMID: 10745593
9. Sanmartin M, Esparza J, Moxica J, Baz JA, Iñiguez-Romo A. Safety and efficacy of a multipurpose coronary angiography strategy using the transradial technique. *J Invasive Cardiol.* 2005 Nov;17(11):594-7. PMID: 16264204
10. Yoshimachi F, Ikari Y. Patient Preparation, Vascular Access, and Guiding Catheter Selection. 2018 Jul 14. In: Watson TJ, Ong PJJ, Tcheng JE, editors. *Primary Angioplasty: A Practical Guide [Internet].* Singapore: Springer; 2018. Chapter 7. PMID: 31314438.
11. Ikari Y, Masuda N, Matsukage T, Ogata N, Nakazawa G, Tanabe T, Morino Y. Backup force of guiding catheters for the right coronary artery in transfemoral and transradial interventions. *J Invasive Cardiol.* 2009 Nov;21(11):570-4. PMID: 19901410.
12. Chow J, Tan CH, Tin AS, Ong SH, Tan VH, Goh YS, Gan HW, Tan KS, Lingamanaicker J. Feasibility of transradial coronary angiography and intervention using a single Ikari left guiding catheter for ST elevation myocardial infarction. *J IntervCardiol.* 2012 Jun;25(3):235-44. doi: 10.1111/j.1540-8183.2011.00710.x.Epub 2012 Feb 7. PMID: 22308978.
13. Villa AD, Sammut E, Nair A, Rajani R, Bonamini R, Chiribiri A. Coronary artery anomalies overview: The normal and the abnormal. *World J Radiol.* 2016 Jun 28;8(6):537-55. doi: 10.4329/wjr.v8.i6.537. PMID: 27358682; PMCID: PMC4919754.
14. Uthayakumaran K, Subban V, Lakshmanan A, Pakshirajan B, Solirajaram R, Krishnamoorthy J, Janakiraman E, Panduranghi UM, Kalidoss L, Sankaradas MA. Coronary intervention in anomalous origin of the right coronary artery (ARCA) from the left sinus of Valsalva (LSOV): a single center experience. *Indian Heart J.* 2014 Jul-Aug;66(4):430-4. doi: 10.1016/j.ihj.2014.05.029. Epub 2014 Jul 26. PMID: 25173202; PMCID: PMC4150032.
15. Karthikeyan Balakrishnan, Suma M. Victor, Avinash Kumar, Vijayakumar Subban, Percutaneous coronary intervention of anomalous right coronary artery arising from the left sinus of Valsalva with the novel use of Ikari left guide catheter- A case series, *IHJ Cardiovascular Case Reports (CVCR),* Volume 6, Issue 1, 2022, Pages 1-4, ISSN 2468-600X, <https://doi.org/10.1016/j.ihjccr.2021.12.007>.

ABBREVIATIONS

RCA- Right Coronary Artery
 LSOV- Left sinus of Valsalva
 ILGC- Ikari left guiding catheter
 DES- Drug Eluting Stent
 CAG- Coronary angiogram
 PCI- Percutaneous coronary intervention.
 IWMI- Inferior wall myocardial infarction
 RVMI- Right ventricular myocardial infarction
 TFI- Trans-femoral intervention
 TRI- Trans-radial intervention