

Case report

Enhancing Precision and Comfort in Paediatric Dentistry with Intraoral Scanners and 3D Printers: A Case Report

Abstract

Maintaining primary dentition is crucial for a child's development, influencing speech, chewing, appearance, and guiding permanent teeth. Premature loss of primary teeth can lead to space loss, crowding, and impaction of permanent teeth. Traditionally, fixed space maintainers (SMs) like band and loop types are used to preserve arch length, but these methods are time-consuming and prone to human error due to extensive coordination with dental laboratories.

This paper examines the use of 3D printing in pediatric dentistry for creating space maintainers, featuring a case report of a 9-year-old girl. After a tooth extraction, a digital impression of her dental arch was taken using an intraoral scanner, and a 3D model was printed. This model was used to fabricate a band and loop space maintainer, which was then fitted and cemented in the patient's mouth.

The integration of 3D printing in SM fabrication reduces chair-side and laboratory time, minimizes human error, and enhances patient comfort by avoiding alginate impressions. Additionally, 3D-printed SMs, produced as a single unit, are less prone to breakage and failure, resulting in more precise and durable appliances.

In conclusion, 3D printing technology significantly advances pediatric dentistry by providing a precise, efficient, and patient-friendly alternative to traditional methods, paving the way for improved dental care solutions.

Key words - Primary dentition, space maintainers, 3D printing, digital impressions, band and loop, dental appliances.

INTRODUCTION

It is important to maintain the primary dentition for a child's overall growth also for development. It not only influences speech, chewing, and appearance but also helps prevent harmful oral habits and guides the eruption of permanent teeth.¹ Normally, deciduous teeth exfoliate to facilitate the emergence of permanent teeth. Early loss of primary teeth can interfere with the natural development of the dentition, leading to the forward movement of adjacent teeth. This mesial migration can result in space reduction, crowding, over-eruption of opposing teeth, and impaction of permanent teeth.

Consequently, maintaining primary teeth in their place is the simplest and most effective way to prevent these issues. It's often emphasized that primary teeth serve as the best space maintainers for the proper alignment of permanent teeth¹⁻³

If a primary tooth is lost prematurely, utilizing a space maintainer is the most effective method for preserving the arch length. Space maintainers ensure that the space left by the early loss of primary teeth is kept open for the proper alignment of permanent teeth.⁴ Among the different types of fixed space maintainers, the band and loop types are the most commonly used. Traditionally, the production of SMs is a meticulous process that involves extensive coordination with a dental laboratory to ensure the best results.^{1,5}

Advancements in digital technology, particularly the use of intraoral scanner for recording impression reduces Gag reflex due to alginate impression also three-dimensional printing, have reduced human error by automating the fabrication of dental models and reduces the use of stone or plaster in fabrication of any appliance.^{6,7} This paper explores the application of this technology in paediatric dentistry for the creation of new types of SMs and includes a case report. Despite good patient compliance, traditional appliances face issues like solder failure, caries development, and extended laboratory times.⁸

A case report:

A 9 years old female patient reported to the OPD of Department of Paediatric and Preventive Dentistry complaining of decayed tooth in upper left back tooth region in the last 25 days. Upon examining the patient, it is observed that there is a pulp necrosis wrt 55 [Figure-1]. IOPA was done wrt 55 which showed premolar at Nolla's stage 4. Treatment plan was decided to Extract 55 and to give space maintainer to maintain the space for the eruption of 15. The Extraction done wrt 55 under local anaesthesia. When

socket healed properly the arch was scanned using an intra oral scanner (iTero Element Flex intraoral scanner). After scanning STL file of a scan is formed [Figure-2] and the file is transferred to 3d Printer (ELEGOO Neptune 4 plus FDM 3D Printer) [Figure-3]. After Formation of the 3D model, conventional band and loop space maintainer is formed on the received 3D model [Figure- 4]. The Band and loop Space maintainer was tried clinically with respect to upper Right deciduous second molar and after adapted Properly to the tooth, glass ionomer cement was used to cement it on the tooth surface (Type 2, GC Gole label). The Patient was instructed not to drink water and not to chew tightly for 30 minutes. And recalled after 3 months.

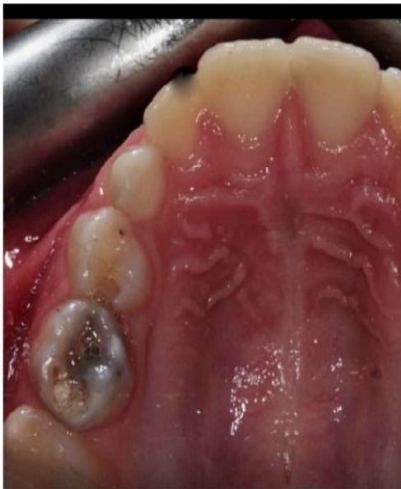

Figure – 1 Intraoral View showing grossly decayed 55

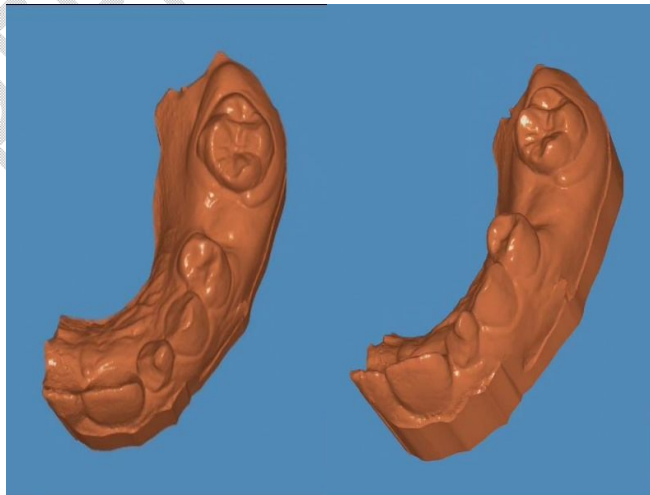


Figure – 2 Scan STL extension obtained from intraoral scanner




Figure – 3 ELEGOO Neptune 4 plus FDM 3D Printer and 3D model



Figure – 4 Fabrication of Conventional Band and loop space maintainer

DISCUSSION

Despite advancements in dentistry and oral health prevention strategies, premature loss of primary teeth in children remains common. It is essential to preserve arch length during the primary, mixed, and early permanent dentition stages after premature tooth loss to ensure the proper development of future permanent occlusion.⁸⁻¹⁰ Neglecting to preserve this space can lead to disturbances in both vertical and horizontal occlusal relationships in both primary and permanent dentitions. Thus, it is crucial to maintain the space created by the premature loss of primary teeth until the eruption of permanent successors. Space maintainers are highly recommended for this purpose as they prevent dental shifting and preserve the arch perimeter, thereby averting potential complications.

The literature reports several drawbacks that may contribute to the failure of traditional appliances. The modern design of the space maintainer (SM) incorporates 3D printing technology, which constructs a three-dimensional solid object based on a digital file.¹² The process involves intraoral scanning to take an impression of the patient, creating a 3D model, digitizing it, replicating the cast, and designing the space maintainer (SM) using conventional methods. This approach significantly improves the precision of the appliance, reduces human error, and enhances patient comfort. Traditional methods involving alginate impressions can trigger gag reflexes and discomfort due to taste, making this digital method particularly beneficial for such patients.¹³

While if the appliance is made from CAD CAM design the lot of laboratory work, including stabilization of the loop, soldering it onto the band in buccal and lingual side, and polishing, those procedures were not necessary, which saves clinicians chair-side

time. Additionally, the appliance fabricated is printed as a single unit, so minimizes breakage, and thereby reduces the likelihood of failure. Compared to conventional appliances, a 3D-printed model features a more complex structure with greater precision.^{14,15}

CONCLUSION

The traditional band and loop space maintainer method has commonly been utilized for space maintenance but is associated with several drawbacks. These include triggering the gag reflex during impressions, potential cement disintegration, and increased time required by clinicians both chairside and in the laboratory, making the procedure cumbersome. In contrast, the innovative digital design of 3D-printed space maintainers is precise, straightforward, and efficient. As 3D printing technology advances, it enables the accurate production of three-dimensional structures with ease and speed.

Ethical Approval:

As per international standards or university standards written ethical approval has been collected and preserved by the author(s).

Consent

As per international standards, **parental written consent** has been collected and preserved by the author(s).

REFERENCES

1. Pahuja, N. Simplify your practice with 3D printed space maintainer. University journal of dental sciences, (2023) ;9(2)82 - 85
2. Barbería E, Lucavechi T, Cárdenas D, Maroto M. Free-end space maintainers: Design, utilization and advantages. J Clin Pediatr Dent 2006; 31:5-8.
3. Setia V, Pandit IK, Srivastava N, Gugnani N, Sekhon HK. Space maintainers in dentistry: Past to present. J Clin Diagn Res 2013; 7:2402-5.
4. Wright GZ, Kennedy DB. Space control in the primary and mixed dentitions. Dent Clin North Am 1978; 22:579- 601.
5. Kirziođlu Z, Ertürk MS. Success of reinforced fiber material space maintainers. J Dent Child (Chic) 2004; 71:158-62.
6. Karaman AI, Kir N, Belli S. Four applications of reinforced polyethylene fiber material in orthodontic practice. Am J Orthod Dentofacial Orthop 2002; 121:650-4.
7. Kargul B, Caglar E, Kabalay U. Glass fibre reinforced composite resin as fixed space maintainer in children 12 month clinical follow up. J Dent Child. 2005; 72:109-12.
8. Kargul B, Caglar E, Kabalay U. Glass fiber reinforced composite resin space maintainer: Case reports. J Dent Child (Chic) 2003; 70:258-61.
9. Sharma S, Goel S. 3D printing and its future in medical world. J Med Res Innov 2019;3: e000141.
10. Ahamed SS, Reddy VN, Krishnakumar R, Mohan MG, Sugumaran DK, Rao AP. Prevalence of early loss of primary teeth in 5-10-year-old school children in Chidambaram town. Contemp Clin Dent 2012; 3:27-30.
11. Murshid SA, Al-Labani MA, Aldhorae KA, Rodis OM. Prevalence of prematurely lost primary teeth in 5-10- year-old children in Tamar city, Yemen: A crosssectional study. J Int Soc Prev Community Dent 2016;6: S126-30.

12. Horax S. Fixed space maintainer with molar band in premature loss of primary first molar teeth (case report). *J Med Nurs* 2006; 27:174-6.
13. Law CS. Management of premature primary tooth loss in the child patient. *J Calif Dent Assoc* 2013; 41:612-8. 13. Qudeimat MA, Sasa IS. Clinical success and longevity of band and loop compared to crown and loop space maintainers. *Eur Arch Paediatr Dent* 2015; 16:391-6.
14. Sykes LM, Parrott AM, Owen CP, Snaddon DR. Applications of rapid prototyping technology in maxillofacial prosthetics. *IntJProsthodont*2004; 17:454- 9
15. Lal K, White GS, Morea DN, Wright RF. Use of stereolithographic templates for surgical and prosthodontic implant planning and placement. Part I. The concept. *J Prosthodont* 2006;15:51-8.