

INCIDENCE AND RISK FACTORS FOR SPINAL FRACTURES IN CANINES: a retrospective Study

Abstract:

A survey was conducted to analyze vertebral fractures in dogs presented to the Madras Veterinary College Orthopaedic Outpatient Unit during a period of one and half year. A total of 24 cases were included, predominantly males with an average weight of 16 to 18 kilograms. The primary causes identified were road traffic accidents (n=15) and high-rise syndrome (n=9), affecting predominantly dogs aged 5 months to 2 years (n=14). Non-descript breeds were most commonly affected. Fractures were most frequently observed in the caudal thoracic vertebrae (T11 to L1). CT myelography revealed ventral displacement in cases of luxation, primarily affecting the thoracolumbar and lumbosacral regions. This study underscores the prevalence and characteristics of vertebral fractures in dogs, highlighting the need for prompt diagnosis and appropriate management strategies.

Key words: Vertebral fractures, dogs, road traffic accidents

Introduction:

Spinal cord injuries in dogs are particularly severe due to the extremely limited regenerative potential of neural tissue. Spinal trauma, which often results in spinal cord dysfunction, frequently involves vertebral fractures, luxation's, or subluxations (Bagley, 2000) and accounts for approximately 10% of all neurological presentations in dogs (Simpson *et al.*, 2009).

These fractures or luxation's are commonly caused by external trauma (Marioni-Henry *et al.*, 2004), with road traffic accidents accounting for 41–63% of cases (Hettlicher *et al.*, 2010). Other reported traumatic events include falls from heights, dog fights, and falling objects (Dewey *et al.*, 2013). The severity and type of injury depend on the animal's position at the time of impact, the type and area of force applied, and the inherent strengths and weaknesses of the vertebral column (Carlson *et al.*, 2003).

Vertebral fractures and luxation's (VFL) almost invariably cause pain and neurological deficits. Neurological deficits result from compression or contusion of neural tissue, while pain may arise due to neural compression, direct mechanical injury, or instability of mesenchymal tissues (Jeffery, 2010). Due to the spinal cord being enclosed by a rigid, inelastic bony structure (vertebrae) and its relatively soft texture, any reduction in canal diameter can lead to spinal cord injury. Mechanical damage to nervous tissue, particularly axons, disrupts nervous impulses, causing various pathophysiological effects such as ischemia, haemorrhage, changes in spinal cord blood flow, and edema (Shores, 1992).

Materials and Methods:

Twenty-four cases presented to the Madras Veterinary College Orthopedic Outpatient Unit with a history of paresis and plegia caused by vertebral fractures from August 2022 to March 2024 were included in the study. All cases underwent a detailed physical, orthopedic, and neurological examination, followed by radiography. CT contrast myelography was performed to determine the location and severity of the fracture and spinal cord compression. Dogs with suspected vertebral fractures or luxation were handled gently to prevent further trauma and were stabilized before undergoing intensive diagnostic tests.

After stabilization for life-threatening comorbidities, all dogs underwent CT myelography. This technique involved performing a cisternal puncture by placing the dogs in lateral recumbency and flexing the head 90° to the neck. A non-ionic, water-soluble contrast medium, such as Iohexol, at a dosage of 0.3 ml/kg body weight, was injected into the subarachnoid space. General anesthesia was

achieved by premedication with Butorphanol and Diazepam at 0.2 mg/kg body weight intravenously, followed by induction with Propofol at 3 mg/kg body weight intravenously. Maintenance anesthesia was provided with a vaporizer setting of 2-2.5% Isoflurane mixed with 100% oxygen.

For CT imaging, all dogs were positioned in sternal recumbency with their forelimbs extended cranially and hind limbs caudally. A computed tomographic scan was performed using a 16-slice Toshiba Alexion helical scanner with a slice thickness of 1 mm, a pitch of 0.6, 120 kVp, and 150 mAs, from the tip of the nose to the coccygeal vertebrae. Sagittal and coronal reformatting, multiplanar reconstruction (MPR), and 3D reconstructions were then carried out.

Data collected included signalment, cause of injury, time elapsed before presentation, concurrent injuries, and treatment method (conservative or surgical stabilization). Information about age, weight, neurological status, radiographic findings, CT findings, and fracture site was included. Each case was clinically graded according to the severity of neurological dysfunction into one of five groups: I (pain only), II (proprioceptive deficits and/or ambulatory para-/tetraparesis), III (non-ambulatory para-/tetraparesis), IV (para-/tetraplegia), and V (para-/tetraplegia with loss of deep pain perception) (Sharp and Wheeler, 2005).

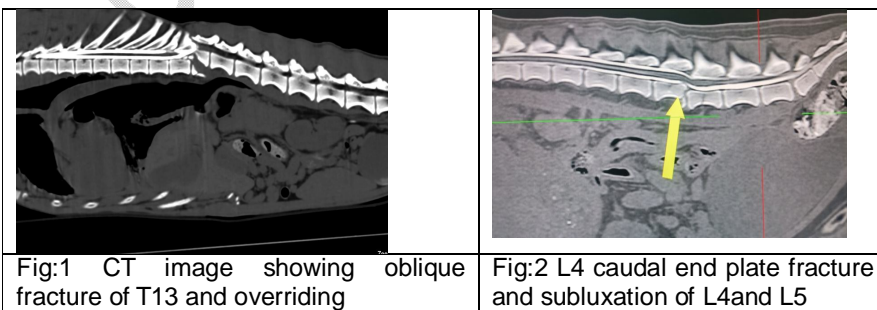
Results:

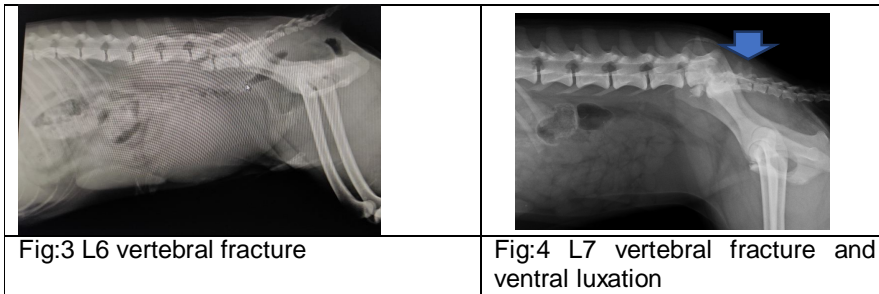
Of the 24 cases with vertebral fractures, 66.6% were male (n=16) and 33.3% were female (n=8), with an average weight of approximately 16 to 18 kilograms. The etiology was noted to be road traffic accidents in 62.5% of cases (n=15), followed by high-rise syndrome in 37.5% of cases (n=9). The age groups affected were as follows: 5 months to 2 years (n=14, 58.3%), 2 to 4 years (n=7, 29.16%), 4 to 6 years (n=2, 8.33%), and above 6 years (n=1, 4.16%).

Among the breeds recorded, non-descript dogs accounted for 41.6% (n=10), followed by Labrador Retrievers (n=4, 16.6%), Siberian Huskies (n=3, 12.5%), German Shepherds (n=2, 8.33%), Chippiparai (n=2, 8.33%), Spitz (n=2, 8.33%), and Rajapalayam (n=1, 4.16%). The sites of fractures were noted as T11 (n=4, 16.6%), T12 (n=6, 25%), T13 (n=5, 20.83%), L2 (n=1, 4.16%), L3 (n=1, 4.16%), L4 (n=1, 4.16%), L7 (n=3, 12.5%) (Fig:4), and C1 (n=1, 4.16%) (Fig : 1, 2 and 3).

Except for one case of tetraplegia, all others were paraplegic. Upon presentation, 16 cases had a loss of nociception, while 8 cases had intact nociception. Concomitant injuries included pneumothorax (n=3), pelvic fracture (n=2), femur fracture (n=1), and hip dislocation (n=1).

In this study, fractures at a single site were observed in 66.6% (n=16) of cases, while multiple sites were involved in 33.3% (n=8) of cases. Vertebral fractures with luxations were noted in 7 cases, predominantly between the mobile and static portions of the vertebral column, specifically in the thoracolumbar region, followed by the lumbosacral region. Among these, the 3 cases of L7 vertebral body fractures were characterized by short oblique fractures with cranioventral displacement of the sacrum. Neurological grading was V in 16 cases, IV in 6 cases, and III in 2 cases. Treatment involved only surgical management, including the use of pedicle screws in 14 cases and string-of-pearls plate fixation in 10 cases.





Neurological examination of the dogs revealed that most exhibited upper motor neuron (UMN) signs, including UMN bladder with incomplete emptying of the bladder. During the physical examination, disparities in vertebral segments at the fracture site were apparent in most dogs, indicating vertebral fracture. Additionally, the cutaneous trunci reflex was a reliable indicator for locating the site of the vertebral lesion.

Discussion:

Road traffic accidents have been identified as the primary cause of vertebral fractures in dogs, consistent with findings reported by Bali *et al.* (2009), who noted that 53% of vertebral fractures resulted from such accidents. The majority of cases were observed in dogs below two years of age, primarily due to their youthful energy and curiosity, which increases their susceptibility to road traffic accidents. Non-descript breeds, often known for their free-roaming habits and their higher population in Chennai city, are particularly vulnerable to such accidents.

Fractures can occur in any part of the vertebral column, but they are most commonly observed in the transition zones between stable and more mobile regions, such as the thoracolumbar region (T3-L3) and the lumbosacral region (L4-S3). In our study, the terminal thoracic region, specifically T11 (n=4), T12 (n=6), and T13 (n=5), was the most frequently affected site. This finding aligns with Bali *et al.* (2009), who identified the thoracolumbar (T3-L3) region as a major site, and Bruce *et al.* (2008), who recorded the thoracolumbar junction (T10-L2) as a very common site, constituting approximately 50% of all spinal fractures in dogs. This contrasts with Feeney and Oliver (1980), who reported the lumbar region (L1-L7) as the primary site of occurrence.

In cases of fracture and luxation, ventral displacement of the caudal segment was noted, which is in agreement with Lang *et al.* (2009). This is mostly due to high-impact injuries from motor vehicle accidents, where muscular forces acting on the vertebrae cause ventral displacement of the caudal vertebrae, depending on the magnitude and direction of the inciting force. The shape and orientation of the vertebral articular facets alter within this region, from ventro-dorsal in the thoracic area to sagittal in the lumbar area, increasing the susceptibility to vertebral fractures and luxations (VFL).

In the cases of L7 fractures, oblique vertebral body fractures with cranio-ventral displacement of the sacrum were observed. These fractures of the vertebral body and articular facets typically occur due to combined loading forces involving flexion and rotation, leading to compression, lateral translation, and rotational forces, causing ventral displacement (Jeffery, 2010).

Cases involving luxation of vertebrae typically have a poor prognosis due to a high likelihood of axonotmesis and neurotmesis of the spinal cord. However, in cases involving the L7 vertebra, the spinal cord typically ends at the level of L5 or L6. At these lower levels, the nerve roots of the cauda equina are more resilient to trauma compared to the spinal cord itself (Beaver *et al.*, 1996). The degree of dislocation and axis deviation were both significantly correlated with worse outcomes in dogs (Lang *et al.*, 2009).

Fractures of the L3 (n=1) and L4 (n=1) vertebrae were associated with absent nociception, urinary retention, and defecation abnormalities. Despite early surgical intervention, there was no neurological improvement. Vertebral fractures and luxations affecting the spinal cord intumescences

(vertebrae C4–T3 and L3–L5) are particularly significant due to the presence of grey matter and nerves supplying the limbs, bladder, and anus (Orgonikova *et al.*, 2021). Injuries to these regions carry a higher risk of permanent paralysis because the grey matter is more susceptible to injury, and these areas have a larger diameter relative to the vertebral canal (Jeffery, 2010).

Dogs that initially showed absent nociception at presentation did not show significant improvement following surgery. However, with intensive physiotherapy, these cases later recovered the ability to walk as spinal walking. The absence of nociception in the limbs below the spinal cord lesion indicates a challenging prognosis for functional recovery (Mullins, 2014; Jeffery, 2010).

All cases underwent radiography as the initial imaging modality, with lateral views by gentle handling. While radiographs were able to diagnose fractures in all cases, they have limitations in assessing the degree of spinal cord compression by fractured fragments. Initial imaging of the vertebral column should be conducted using standard lateral radiographs. However, radiography can miss vertebral fractures, particularly those affecting the middle and dorsal levels of the vertebral column. Additionally, it is ineffective at identifying fracture fragments within the vertebral canal and detecting spinal cord compression (Mullins, 2014).

All cases were then subjected to CT myelography to assess the degree of compression and assist in surgical planning. Computed tomography (CT) is the preferred imaging method for diagnosing vertebral fractures and planning surgery (Mann *et al.*, 2003). The primary factors contributing to vertebral column stability are the vertebral body, intervertebral disc, and articular facet joints. Surgical intervention is typically indicated if more than one of these components is compromised (Smith and Jeffery, 2005). This 3-dimensional imaging modality provides excellent definition of the vertebral bone and, with appropriate adjustments, ligamentous structures. It also allows for detailed visualization of any impingement of disrupted material into the vertebral canal (Watineet *et al.*, 2006).

All cases were initially stabilized before undergoing aggressive diagnostic procedures. Life-threatening concomitant abnormalities, such as pneumothorax, were treated with thoracocentesis and blood patch pleurodesis. It is crucial to address potential systemic abnormalities as well. Thoracic trauma, including pneumothorax, rib fractures, and pulmonary contusion, occurs in 15–35% of patients with vertebral column injuries (Turner, 1987; Bruce *et al.*, 2008).

Conclusion:

In conclusion, this study highlights the significant impact of road traffic accidents and high-rise syndrome as leading causes of vertebral fractures in dogs. The findings underscore the importance of early diagnosis using advanced imaging techniques like CT myelography and the critical role of surgical intervention in managing these injuries. Understanding the prevalence, demographics, and outcomes associated with vertebral fractures in dogs is essential for improving treatment strategies and enhancing patient care in veterinary orthopedics.

References:

- Bruce CW, Brisson BA, Gyselinck K. Spinal fracture and luxation in dogs and cats: a retrospective evaluation of 95 cases. *Vet Comp OrthopTraumatol.* 2008; 21(3):280–4.
- Bagley RS. Spinal fracture or luxation. In: *Vet Clin North Am Small Anim* 2000; 1: 133–153
- Beaver DP, MacPherson GC, Muir P, Johnson KA. Methyl-methacrylate and bone screw repair of seventh lumbar vertebral fracture-luxations in dogs. *J. Small Anim. Pract.* 1996;37:381–386.
- Carlson GD, Gorden CD, Oliff HS, Pillai JJ, LaManna JC. Sustained spinal cord compression: part I: time-dependent effect on long-term pathophysiology. *J Bone Joint Surg Am.* 2003;85(1):86–94.
- Feeney DA, Oliver JE. Blunt spinal trauma in the dog and cat: insights into radiographic lesions. *J Am Vet Med Assoc.* 1980; 16: 885–890.

- Jeffery ND. Vertebral fracture and luxation in small animals. *The Veterinary clinics of North America. Small animal practice.* 2010; 40(5), 809–828.
- Lang J, Jaggy A, Spreng D, Doherr MG, Forterre F, & Bali MS. Comparative study of vertebral fractures and luxations in dogs and cats. *Veterinary and Comparative Orthopaedics and Traumatology.* 2009; 22(01), 47–53.
- Mann FA, Cohen WA, Linnau KF, Hallam DK, Blackmore CC. Evidence-based approach to using CT in spinal trauma. *Eur J Radiol.* 2003;48(1):39–48
- Orgonikova I, Brocal J, Cherubini GB, & Palus V. *Vertebral fractures and luxations in dogs and cats, part 1: evaluation of diagnosis and prognosis. Companion Animal.* 2021; 26(2), 1–10.
- Sharp NJH, Wheeler SJ. Patient examination. In: *small animal spinal disorders: diagnosis and surgery.* 2nd ed. London: Mosby-Wolfe. 2005; 19–33.
- Simpson SA, Syring R, Otto CM. Severe blunt trauma in dogs: 235 cases (1997- 2003). *J Vet Emerg Crit Care.* 2009;19:588–602.
- Smith PM, Jeffery ND. Spinal shock—comparative aspects and clinical relevance. *J Vet Intern Med.* 2005;19(6):788–93.
- Watine S, Cabassu JP, Catheland S, Brochier L, Ivanoff S. Computed tomography study of implantation corridors in canine vertebrae. *J. Small Anim. Pract.* 2006; 47, 651–657.
- Shores A. Pathophysiology and management of traumatic spinal injuries. *Vet Clin North Am Small Anim.* 1992; 22: 859–888

Table 1 : Epidemiological findings

S. no	Breed	Weight (kgs)	Age	Sex	Aetiology	Site of fracture	Neurological grade
1.	Non descript	17	3 Y	Female	Road traffic accident	T11-T12	5
2.	German Shepard	30kgs	2.5y	Male	High raise syndrome	L 1	5
3.	Non descript	14	2 Y	Male	Road traffic accident	L7	4
4.	Labrador retriever	12	7M	Male	High raise syndrome	C5, T12	4
5.	Non descript	17	7M	Male	Road traffic accident	T13	5
6.	Rajapalayam	25	3.5Y	Male	High raise syndrome	T11, T12	5
7.	Labrador retriever	12	9 M	Male	Road traffic accident	L1	5
8	Labrador retriever	22	9M	Male	High raise syndrome	L1,L3,L6,L7	5
9	Non descript	14	3Y	Male	Road traffic accident	L7	5
10	Non descript	12	1.5Y	Male	Road traffic accident	L5-L6	4
11	Non descript	15	6Y	Male	Road traffic accident	L7	4
12	chippiparai	20	6M	Female	Road traffic accident	T13	5
13	Non descript	11	7M	Female	Road traffic accident	T13,L1	5
14	Non descript	14	1.5Y	Female	Road traffic	L3-L4	5

					accident		
15	Non descript	6.6	1.2Y	Female	Road traffic accident	L4-L5	5
16	spitz	8	3Y	Male	Road traffic accident	L6	5
17	Siberian husky	18	1Y	Male	High raise syndrome	L1	5
18	Non descript	16	1.2 Y	Female	Road traffic accident	T 13	4
19	Labrador retriever	21	1.4 Y	Male	High raise syndrome	T 11,	5
20	Siberian husky	18	1.3 Y	Female	High raise syndrome	L1	4
21	German shepherd	24	3.2 Y	Male	High raise syndrome	L5	5
22	Chippiparai	23	1.7 Y	Male	High raise syndrome	T11-L 1	5
23	spitz	8	7 Y	Female	Road traffic accident	L1	5
24	Siberian husky	22	4 Y	Male	Road traffic accident	T12	4
S. no	Breed	Weight (kgs)	Age	Sex	aetiology	Site of fracture	Neurological grade
8.	Non descript	17	3 Y	Female	Road traffic accident	T11-T12	5
9.	German Shepard	30kgs	2.5y	Male	High raise syndrome	L 1	5
10	Non descript	14	2 Y	Male	Road traffic accident	L7	4
11	Labrador retriever	12	7M	M	High raise syndrome	C5, T12	4
12	Non descript	17	7M	M	Road traffic accident	T13	5
13	Rajapalayam	25	3.5Y	M	High rise syndrome	T11, T12	5
14	Labrador retriever	12	9 M	M	Road traffic accident	L1	5
8	Labrador retriever	22	9M	M	High raise syndrome	L1,L3,L6,L7	5
9	Non descript	14	3Y	M	Road traffic accident	L7	5
10	Non descript	12	1.5Y	M	Road traffic accident	L5-L6	4
11	Non descript	15	6Y	M	Road traffic accident	L7	4
12	chippiparai	20	6M	F	Road traffic accident	T13	5
13	Nondescript	11	7M	F	Road traffic accident	T13,L1	5
14	Non descript	14	1.5Y	F	Road traffic accident	L3-L4	5
15	Non descript	6.6	1.2Y	F	Road traffic accident	L4-L5	5
16	spitz	8	3Y	M	Road traffic accident	L6	5
17	Siberian husky	18	1Y	M	High raise syndrome	L1	5
18	Non descript	16	1.2 Y	F	Road traffic accident	T 13	4

19	Labrador retriever	21	1.4 Y	M	High raise syndrome	T 11,	5
20	Siberian husky	18	1.3 Y	F	High raise syndrome	L1	4
21	German shepherd	24	3.2 Y	M	High raise syndrome	L5	5
22	Chippiparai	23	1.7 Y	M	Road traffic accident	T11-L 1	5
23	spitz	8	7 Y	F	Road traffic accident	L1	5
24	Siberian husky	22	4 Y	M	Road traffic accident	T12	4

UNDER PEER REVIEW