

## Case report

# SPONTANEOUS HETEROTOPIC PREGNANCY AFTER A PREVIOUS IPSILATERAL OOPHORECTOMY: A Case Report

### **Abstract**

Heterotopic pregnancy occurs when there is coexisting intrauterine and ectopic pregnancies. The increased incidence of multiple pregnancy with ovulation induction and assisted reproductive technology (ART) increases the risk of both ectopic and heterotopic pregnancy.

It has an incidence ranging from to 1:30,000 pregnancies of spontaneous conceptions to 1:100 to 1:500 with the use of assisted conception. It is a rare event with significant maternal morbidity and mortality due to misdiagnosis and late presentation especially following spontaneous conception where index of suspicion is very low. We present a very rare case of heterotopic pregnancy in a natural conception after a previous contralateral oophorectomy, who subsequently had salpingectomy with normal progression of the intra-uterine pregnancy till date.

**In conclusion**, this case study reminds us of the importance of maintaining a high index of suspicion for heterotopic pregnancies even in spontaneous conceptions. The potential mechanisms and comprehensive management strategies enhances understanding and guides clinical practice.

**Keywords:** Oophorectomy, Spontaneous conception, heterotopic pregnancy. Live birth

### **Introduction**

Heterotopic pregnancy occurs when an intrauterine and an extrauterine pregnancy co-exist in the same patient and it can present with both diagnostic and therapeutic challenges. The increased incidence of multiple gestation with ovulation induction and assisted reproductive technology (ART) increases the risk of both ectopic and heterotopic pregnancy<sup>1</sup>. It is a very rare event in spontaneous conception with an incidence of 1 in 30,000 pregnancies and rising to 1 in 900 with ovulation induction and as much as

1 in 100 to 1 in 500 with ART<sup>1</sup>. It is no longer very uncommon with the advent of assisted conception. Extremely very rare is the finding of a heterotopic pregnancy by spontaneous conception after an adnexectomy or oophorectomy. Several locations of ectopic pregnancy have been described such as tubal in up to 90-95%, ovarian, caesarean section scar, abdominal,<sup>1,2,3</sup> and even cervical, otherwise referred to pregnancies below the internal cervical os.<sup>4</sup> These different types of ectopic pregnancy can co-exist with intra-uterine pregnancy.

The hypothetical mechanisms of ipsilateral ectopic pregnancy after a prior salpingectomy, oophorectomy or adnexectomy includes contralateral fertilization and transmigration from the intact fallopian tube across the endometrial cavity to contralateral tubal stump or transperitoneal migration of the ovum or embryo to the contralateral tubal stump and passage of the spermatozoa to fertilize the ovum in the proximal tubal remnant with some degree of patency or recanalization.<sup>2</sup> The plausible mechanism with regards to heterotopic pregnancy after a contralateral oophorectomy or adnexectomy is unilateral multimolecular ovulation and subsequent fertilization. This is rare in the absence of ovulation induction or ART.<sup>2</sup>

Heterotopic pregnancy can be multiple as well<sup>3</sup>, although majority of reported case are of single intra-uterine gestation, co-existence of multiple intra uterine gestations have also been reported as triplets<sup>4</sup>. Heterotopic pregnancy can vary in presentation and should be considered more likely in the event of; assisted reproductive techniques, persisting or rising chorionic gonadotrophins after dilatation and curettage for an abortion, when the uterine fundus is larger than for menstrual dates, presence of more than one corpus luteum in a natural conception and absence of vaginal bleeding in the presence of signs and symptom of ectopic gestation.<sup>4</sup>

It may also present as lower quadrant pain in early pregnancy and hematometra.<sup>5</sup>

Most of the extrauterine gestation are tubal in location followed by abdominal implantation with higher maternal mortality than that of tubal pregnancies and very much than that of intrauterine pregnancies. Cervical and ovarian heterotopic pregnancies have also been reported. This case therefore

intends to remind gynaecologists especially those practising in less developed world where access to ultrasound may be limited that such cases do exist and can be managed properly when diagnosed early.

### *Case Presentation*

She is a 37-year-old Gravida 2 para 1 lady who was admitted in another facility following minimal vaginal bleeding in a spontaneously conceived pregnancy. An urgent pelvic ultrasound scan done in the referring hospital showed a live intra-uterine gestation. Her vaginal bleeding subsided, and she was discharged after 48 hours on admission to continue bed rest at home. Her previous surgical history includes uncomplicated myomectomy with a unilateral oophorectomy for dermoid cyst of the ovary 4 years ago and a previous caesarean section for twin gestation two years ago.

However, her bleeding per vagina continued and she was later brought to our facility one week later having collapsed at home and was brought to the hospital with severe pallor, severe lower abdominal pains and hypotension.

On presentation her vital signs were, heart rate was 138 beats per minute, blood pressure 60/40 mmHg, respiratory rate of 32 breaths per minute and oxygen saturation of 88%. She was resuscitated with crystalloids and high flow oxygen. Her vital signs post resuscitation were Heart rate 129 beats per minute, blood pressure of 90/50 mmHg, and oxygen saturation of 95%. An urgent pelvic ultrasound scan revealed intra-uterine gestation at 9 weeks and an extra-uterine gestation also at 9 weeks both with cardiac activity with large amount of hemoperitoneum in dependent abdominal and pelvic quadrants. She had an emergency exploratory laparotomy and right salpingectomy. Intraoperative findings were hemoperitoneum of two litres of non-clotting blood, about 5 x 4 cm ruptured right ampullary ectopic pregnancy and 12 weeks size uterus. The right ovary was absent. The left ovary was seen with corpus

luteum cyst, and the left fallopian tube was normal. She had 4 units of blood transfused intraoperatively.

Her immediate post op vitals were heart rate of 125 beats per minute, Blood pressure of 110/60mmHg, respiratory rate of 20 cycles per minute and oxygen saturation of 98%. She was discharged home 3 days after surgery with a PCV of 31%. She is currently being followed up for her intrauterine pregnancy which has been uneventful.

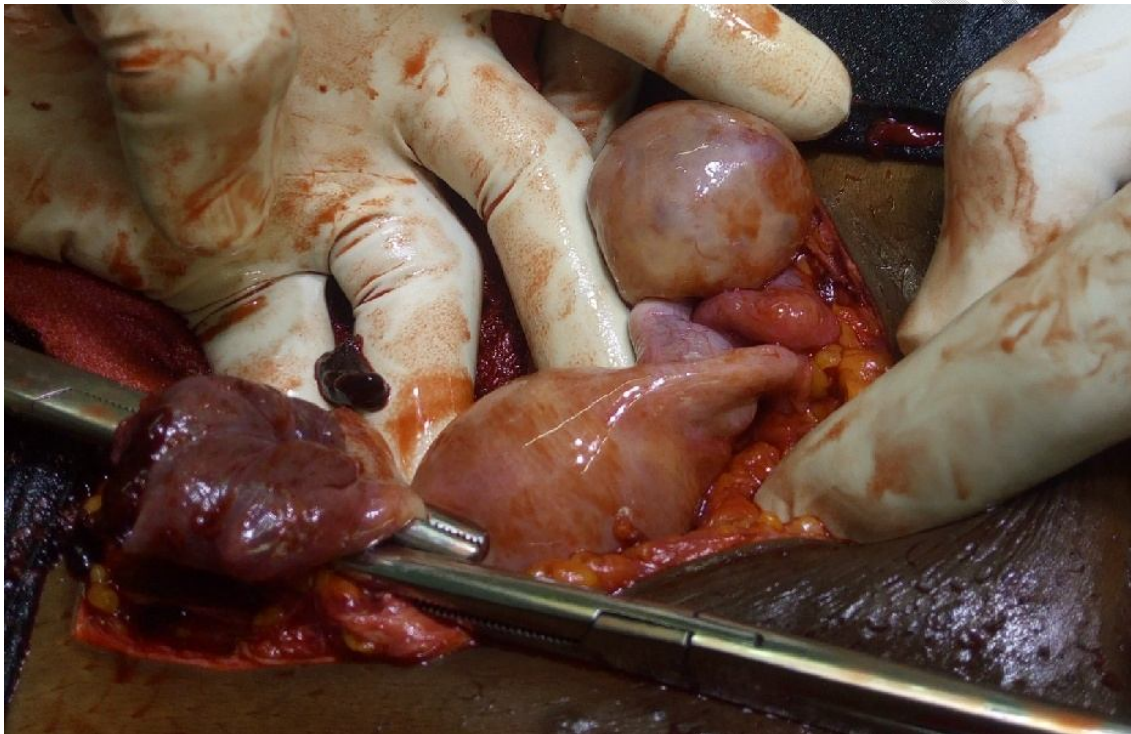


Figure 1. Picture image of right tubal ectopic, normal left fallopian tube and left ovary with corpus luteum

## Discussion

Heterotopic pregnancy may often present with diagnostic difficulty as the regular clinical signs and symptoms are many a times, nonspecific and may be confused with regular or abnormal pregnancy complications.<sup>1,3-6</sup> The measurement of serial b-hCG measurements adds to the confusion as the intrauterine gestation causes an appropriate rise in the b-hCG concentration.<sup>5,6</sup> Early transvaginal

sonography as commonly done following ART helps in early diagnosis however identification of an intrauterine gestation tends to reduce the index of suspicion of an extra uterine gestation especially in the absence of symptoms and eventual delayed presentation.<sup>6</sup> While a positive tap during an abdominal paracentesis in the presence of prior identified intra-uterine gestation may help in diagnosis, a negative tap does not exclude a heterotopic pregnancy.<sup>6</sup>

Intrauterine gestation with hemorrhagic corpus luteum can simulate heterotopic gestation both clinically and on ultrasound as in this case<sup>7</sup>. Other surgical pathologies of acute abdomen are differentials and may simulate heterotopic pregnancy making clinical diagnosis difficult.<sup>6,7</sup> A bicornuate uterus with gestation in both cavities may also simulate a heterotopic pregnancy. High-resolution transvaginal ultrasound with color Doppler is helpful because the trophoblastic tissue in the adnexa in a case of heterotopic pregnancy shows increased flow with a significantly reduced resistance index.<sup>1,5,6</sup> There are a number of risk factors for heterotopic pregnancy, such as previous tubal damage, ectopic pregnancy, and ART techniques such as in vitro fertilization and gamete intrafallopian transfer. Pharmacological ovulation induction is also a reported risk by increasing multifollicular ovulation.<sup>7,8,9,10</sup> Heterotopic pregnancy can occur in the absence of any predisposing risk factors, and the detection of the intrauterine pregnancy does not exclude the possibility of the simultaneous existence of an ectopic pregnancy.<sup>8</sup> The risk factors present in our case are those of pelvic surgeries, belonging to a race prone to multiple gestation and having had a history of twin pregnancy. Her ruptured tubal pregnancy presented as an acute abdomen and hemorrhagic shock. Heterotopic pregnancy is most likely to be missed in natural conception due to the dampened index of suspicion on ultrasound hence, the late presentation with tubal rupture seen as acute abdomen, which can progress to maternal shock, possibly leading to maternal mortality.<sup>7</sup> Just as ectopic pregnancy, it can present as a life-threatening gynaecological emergency,<sup>7</sup> as in the index case.

The aim of management of heterotopic pregnancy is to terminate the extrauterine pregnancy while taking precautions to minimize the possible threat to the intrauterine gestation. This can be laparoscopically or via laparotomy with minimal manipulation of the uterus<sup>3</sup>. The surgical removal of

the extrauterine pregnancy is not without risk to the intrauterine pregnancy. Laparotomy is the usual approach with hemoperitoneum and haemodynamic instability.<sup>9</sup>

As a form of medical or nonsurgical management of heterotopic pregnancy, selective potassium chloride has been applied successfully to cases of tubal, cervical, cesarean scar, and cornual or interstitial pregnancies with preservation of the coexistent intrauterine pregnancy.<sup>10</sup> Success rate of 66.7% deliveries after treatment of heterotopic pregnancies has been reported<sup>11</sup>.

The intrauterine pregnancy associated with a heterotopic pregnancy is at increased risk for spontaneous abortion; in cases of ongoing pregnancy, it seems that the prognosis depends on the time of delivery.<sup>9</sup>

Reduction in the risk of spontaneous abortion of the intrauterine gestation during management should include taking care to avoid damage to the corpus luteum, minimal handling or manipulation of the uterus, and various prophylactic uterine relaxants to reduce uterine irritability most of which are not evidenced based such as progesterone, salbutamol, NSAIDS and magnesium sulphate.<sup>8-11</sup>

It requires a high index of suspicion for early and timely diagnosis. Prompt intervention can result in a successful outcome for the intrauterine fetus, and it may also prevent tubal rupture and hemorrhagic shock, which can cause severe morbidity and maternal mortality.<sup>11,12</sup>

**In conclusion**, this case study reminds us of the importance of maintaining a high index of suspicion for heterotopic pregnancies even in spontaneous conceptions. The potential mechanisms and comprehensive management strategies enhances understanding and guides clinical practice.

**Disclaimer (Artificial intelligence)**

**Option 1:**

**Author(s) hereby declare that NO generative AI technologies such as Large Language Models (ChatGPT, COPILOT, etc) and text-to-image generators have been used during writing or editing of manuscripts.**

## References

1. Olamijulo, Joseph Ayodeji<sup>1,2</sup>; Okusanya, Babasola Oluwatomi<sup>1,2</sup>; Adenekan, Muisi Alli<sup>2</sup>; Ugwu, Aloy Okechukwu<sup>2</sup>; Olorunfemi, Gbenga<sup>3</sup>; Okojie, Osemen<sup>2</sup>. Ectopic Pregnancy at the Lagos University Teaching Hospital, Lagos, South-Western Nigeria: Temporal Trends, Clinical Presentation and Management Outcomes from 2005 to 2014. *Nigerian Postgraduate Medical Journal* 27(3):p 177-183, Jul–Sep 2020. | DOI: 10.4103/npmj.npmj\_35\_20
2. Abdelmonem AH, Sayed G, Abugazia AE, Kohla S, Youssef R. Heterotopic pregnancy after a spontaneous conception a case report with a review of clinical, laboratory and imaging findings. *Clin Case Rep.* 2021 Aug 16;9(8):e04649. doi: 10.1002/ccr3.4649. PMID: 34430013; PMCID: PMC8365543.
3. Wang YN, Zheng LW, Fu LL, Xu Y, Zhang XY. Heterotopic pregnancy after assisted reproductive techniques with favorable outcome of the intrauterine pregnancy: A case report. *World J Clin Cases.* 2023 Jan 26;11(3):669-676. doi: 10.12998/wjcc.v11.i3.669. PMID: 36793642; PMCID: PMC9923848.
4. Ugwu AO, Makwe CC, Omisakin SI, Ani-ugwu NK, Augustine E, Ojiefoh LG, et al. Successful management of cervical ectopic pregnancy following invitro fertilisation. *Hellenic Journal of Obstetrics and Gynecology.* 2021 Oct 3;20(4):221–4.

5. Černiauskaitė M, Vaigauskaitė B, Ramašauskaitė D, Šilkūnas M. Spontaneous Heterotopic Pregnancy: Case Report and Literature Review. *Medicina*. 2020; 56(8):365.  
<https://doi.org/10.3390/medicina56080365>
6. Anozie OB, Esike CU, Eze JN, Mba UE, Nwafor JI, Ukaegbe CI, Mamah JE. Heterotopic pregnancy in a natural conception presenting as an acute abdomen: Management and delivery of a live baby at term. *Int J Case Rep Images* 2019;10:101011Z010A2019.
7. Oluwole AA, Ugwu AO, Omisakin SI, Adaramoye VO. Ectopic pregnancy: A life-threatening gynaecological emergency revisited in Lagos, Southwest, Nigeria. *Niger J Med* 2023;32:113-6
8. Ljuca D, Hudić I, Hadzimehmedović A. Heterotopic pregnancy in natural conception: our initial experience: case report. *Acta Clin Croat*. 2011;50: 249-252.
9. Jan F, Naikoo GM, Rather MH, Sheikh TA, Rather YH. Ruptured heterotopic pregnancy: a rare cause for hemoperitoneum; report of three cases from Kashmir, India. *Indian J Surgery*. 2010;72:404-406.
10. Yeh J, Aziz N, Chueh J. Nonsurgical management of heterotopic abdominal pregnancy. *Obstet Gynecol*. 2013;121:489-495.
11. Fan Y, Du A, Zhang Y, Xiao N, Zhang Y, Ma J, Meng W, Luo H. Heterotopic cervical pregnancy: Case report and literature review. *J Obstet Gynaecol Res*. 2022 May;48(5):1271-1278. doi: 10.1111/jog.15193. Epub 2022 Feb 21. PMID: 35191138; PMCID: PMC9303410.

12. Černiauskaitė M, Vaigauskaitė B, Ramašauskaitė D, Šilkūnas M. Spontaneous Heterotopic Pregnancy: Case Report and Literature Review. *Medicina (Kaunas)*. 2020 Jul 22;56(8):365. doi: 10.3390/medicina56080365. PMID: 32707853; PMCID: PMC7466362.

UNDER PEER REVIEW