

Stent Oversizing in In-stent Restenosis- A Clinical Vignette

ABSTRACT

Aims: Percutaneous coronary intervention (PCI) is one of the important management options for intra-stent restenosis (ISR) following PCI. Undersized stents may lead to suboptimal results. Hence, adequate stent size relative to the vessel of the target is crucial. In this case, we have placed an oversized stent inside a smaller stent with ISR and followed up.

Case Presentation: A 48-year-old male came with complaints of exertional angina for 2 months. We proceeded with a coronary angiogram, which revealed ISR in the RCA and a patent stent in the LCX. Initial suboptimal predilatation and the non-availability of a cutting balloon were challenging. RCA stenting was done with a larger sized stent. He is doing well at the 22-month follow-up, asymptomatic, and on regular medications.

Discussion: The drug-eluting stent technology at present offers an effective antiproliferative effect. Hence, the demerit of vessel injury was counterbalanced by the merits of bigger final stent dimensions due to oversized stents. Similar to our case, this positive effect of stent oversizing was documented in procedural as well as clinical outcomes.

Conclusion: Selection of larger-size stents (preferably alternative DES) with appropriate attention to the edge effects can be considered an effective strategy for ISR while also optimizing long-term outcomes. Drug-coated balloons (DCB) may be taken into account for broadened use if they are proven to be non inferior to DES in randomized control trials.

Keywords: In-stent Restenosis (ISR), Drug eluting stent, oversized stent, PCI complications.

1. INTRODUCTION

Percutaneous coronary intervention (PCI) is one of the important management options for patients with coronary artery disease and intra-stent restenosis (ISR) following PCI [1]. In-stent restenosis (ISR) is characterized by the presence of plaque within 5 mm of the stent edge, accompanied by a stenosis greater than 50% [2]. There is a 15%–30% incidence of ISR for stents [3]. The problem of ISR was tried to overcome with drug-eluting stents (DES) by making use of antiproliferative drugs like paclitaxel and sirolimus, which decrease proliferation of smooth muscles, delay re-endothelialization, and reduce neointimal formation [4,5]. In comparison with bare metal stents, the first-generation drug-eluting stents decreased the rate of ISR but increased the development of subacute, late, and very late stent thrombosis. These were associated with major adverse cardiac events, including myocardial infarction and death [5–7]. There is literature evidence that undersized stents lead to suboptimal results, mainly underexpansion of stents that result in ISR and stent thrombosis [8–10]. Hence, adequate stent size relative to the vessel of the target is crucial.

2. CASE PRESENTATION

48-year-old male who is known to be diabetic and hypertensive has been on treatment for the past 12 years. History of an old inferior wall myocardial infarction (IWMI) in 2020, for which he was thrombolysed with streptokinase and proceeded with a coronary angiogram (CAG) elsewhere. CAG showed 70% stenosis in the distal left circumflex (LCX) and 80%

stenosis in the mid-RCA. Percutaneous coronary intervention (PCI) was done, and 3.0 x 28 mm sirolimus DES was deployed in the right coronary artery (RCA), and 2.75 x 16 mm sirolimus DES was deployed. 2 years later (2022), he came with a history of a 2-month duration of exertional angina. Electrocardiography revealed old IWMI, and echocardiography showed left ventricular (48%) mild left ventricular systolic dysfunction. We proceeded with a coronary angiogram, which showed 90% ISR in the RCA with a patent stent in the LCX.. We proceeded from PCI to RCA. A 3.5 EBU guiding catheter was used to engage the RCA, and a blue wire was passed. Optimal predilatation couldn't be achieved with a 2.75 x 12 mm balloon even after multiple times at 16 atm for 20 sec. Due to the non-availability of cutting balloons, multiple predilatations are done by changing the position of the cougar XT wire, assuming it is the atherotome of cutting balloons at different angles. Predilatation was done with a 2.75 x 12 mm balloon. RCA stenting was done with a 3.5 x 44 mm everolimus drug-eluting stent into the old 3.0 x 28 mm sirolimus DES. Multiple post-dilatations were done with 3x8mm and 3.5x8mm balloons. Ostial flaring was done with a 4x8-mm balloon. The patient was followed up regularly in cardiology OPD after the procedure. In spite of initial suboptimal predilatation, the non-availability of cutting balloons, and intracoronary imaging, the procedure was successful, and he is doing well at the 22-month follow-up. He is now asymptomatic on regular medications.

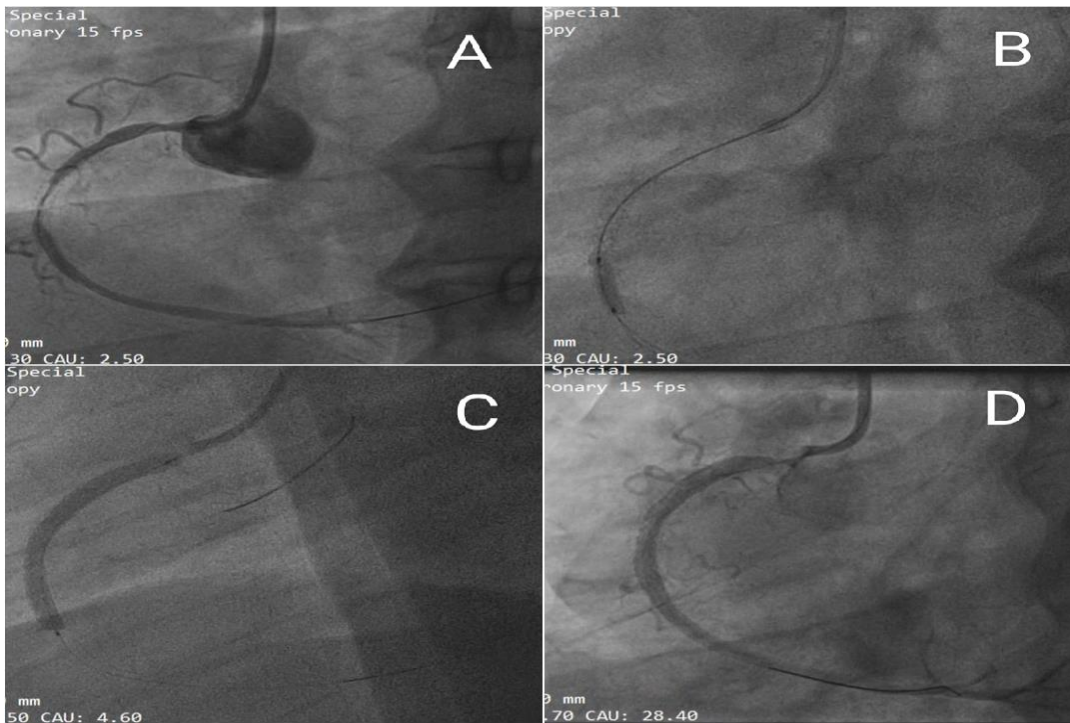


Fig. 1. A- RCA angiogram showing instent restenosis
B- Predilatation during PCI to RCA using 2.75x 12 mm balloon.
C- Stenting of RCA with 3.5 X 44 mm everolimus drug eluting stent into the old 3.0 X 28 mm sirolimus DES.
D- RCA angiogram after post dilatation.

3. DISCUSSION

Instent restenosis is characterized by the development of hyperplasia of the endometrium due to mechanical, biological, technical, and complex factors related to the patient that cause the destruction of target blood vessels and a spike in adverse cardiac events [11]. Hence, anticipation, early detection, and prevention of ISR are vital. It has been found that systemic hypertension, diabetes mellitus, greater than 1 lesion in coronary arteries, unstable angina, left anterior descending artery involvement, stent diameter greater than or equal to 3 mm, stent length more than 20 mm, and LDL cholesterol more than or equal to 1.9 mmol/L were the independent risk factors following PCI for ISR. Preventing these factors is essential to preventing ISR [12].

One of the main risk factors for coronary artery disease (CAD) is hypertension. The blood increases the shear force on the vessel wall and damages the endothelial cells if there is a fluctuation in the blood pressure (BP) levels or a persistent increase in BP, which increases the incidence of ISR [13]. Therefore, patients with hypertension must strictly control their blood pressure after surgery.

Even though the strategy of bigger stents was previously accepted in the baremetal stent era, it has also been mentioned that implantation of oversized stents may result in neointimal proliferation [14, 15], which is probably caused by vessel injury due to overstretching [15–17]. The drug-eluting stent technology at present offers an effective antiproliferative effect. Hence, the demerit of vessel injury was counterbalanced by the merits of bigger final stent dimensions due to oversized

stents [18]. Similar to our case, this positive effect of stent oversizing was documented in procedural as well as clinical outcomes. Even in DES deployment, aggressive selection of bigger stents with good attention to the edge effects can optimize long-term outcomes. [18] POBA alone has a high recurrence rate; selecting another layer of stent (preferably an alternative DES) is most commonly used but not desired. This leaves drug-coated balloons as a potential treatment, but they are subjected to effective randomized control trials for their future utilization [19, 20].

4. CONCLUSION

The selection of larger-size stents (preferably alternative DES) with appropriate attention to the edge effects can be considered an effective strategy for ISR while also optimizing long-term outcomes. Drug-coated balloons (DCB) may be taken into account for broadened use if they are proven to be non inferior to DES in randomized control trials.

CONSENT

All authors declare that written informed consent was obtained from the patient/attender for publication of this case report and accompanying images.

REFERENCES

1. Murata N, Takayama T, Hiro T, Hirayama A. Balloon pin-hole rupture during percutaneous coronary intervention for recurrent, calcified in-stent restenosis: a case report. *Catheter Cardiovasc Interv.* 2018;91(7):1287–1290. doi: 10.1002/ccd.27405.
2. Yu Y, Zhou Y, Ma Q, Jia S, Wu S, Sun Y, Liu X, Zhao Y, Liu Y, Shi D. The conical stent in coronary artery improves hemodynamics compared with the traditional cylindrical stent. *Int J Cardiol.* 2017;227:166–171. doi: 10.1016/j.ijcard.2016.11.065.
3. Alfonso F, Perez-Vizcayno MJ, Cuesta J, Garcia Del Blanco B, Garcia-Touchard A, Lopez-Minguez JR, Masotti M, Zueco J, Cequier A, Velazquez M, et al. 3-year clinical follow-up of the RIBS IV clinical trial: a prospective randomized study of drug-eluting balloons versus everolimus-eluting stents in patients with in-stent restenosis in coronary arteries previously treated with drug-eluting stents. *JACC Cardiovasc Interv.* 2018;11(10):981–991. doi: 10.1016/j.jcin.2018.02.037.
4. Moses J.W., Leon M.B., Popma J.J. et al. Sirolimus-eluting stents versus standard stents in patients with stenosis in a native coronary artery. *N Engl J Med.* 2003; 349: 1315-1323
5. Stettler C., Wandel S., Allemann S. et al. Outcomes associated with drug-eluting and bare-metal stents: a collaborative network meta-analysis. *Lancet.* 2007; 370: 937-948
6. Hong M.K., Mintz G.S., Lee C.W. et al. Intravascular ultrasound predictors of angiographic restenosis after sirolimus-eluting stent implantation. *Eur Heart J.* 2006; 27: 1305-1310
7. Jensen L.O., Thayssen P., Christiansen E.H. et al. Safety and efficacy of everolimus- versus sirolimus-eluting stents: 5-year results from SORT OUT IV. *J Am Coll Cardiol.* 2016; 67: 751-762
8. Fujii K, Carlier SG, Mintz GS, Yang YM, Moussa I, Weisz G, Dangas G, Mehran R, Lansky AJ, Kreps EM, Collins M, Stone GW, Moses JW, Leon MB. Stent underexpansion and residual reference segment stenosis are related to stent thrombosis after sirolimus-eluting stent implantation: an intravascular ultrasound study. *J Am Coll Cardiol.* 2005;45:995–998. doi: 10.1016/j.jacc.2004.12.066.

9. Cook S, Wenaweser P, Togni M, Billinger M, Morger C, Seiler C, Vogel R, Hess O, Meier B, Windecker S. Incomplete stent apposition and very late stent thrombosis after drug-eluting stent implantation. *Circulation*. 2007;115:2426–2434. doi: 10.1161/CIRCULATIONAHA.106.658237.
10. Song HG, Kang SJ, Ahn JM, Kim WJ, Lee JY, Park DW, Lee SW, Kim YH, Lee CW, Park SW, Park SJ. Intravascular ultrasound assessment of optimal stent area to prevent in-stent restenosis after zotarolimus-, everolimus-, and sirolimus-eluting stent implantation. *Catheter Cardiovasc Interv*. 2014;83:873–878. doi: 10.1002/ccd.24560.
11. Hong L, Wang H, Yin QL, Li LF, Lai HL, Chen ZQ, Lu LX, Li B, Huang Q. Percutaneous coronary intervention of patients with complex small coronary artery lesion unsuitable for coronary artery bypass graft. *Zhonghua Yi Xue Za Zhi*. 2010;90(2):107–109
12. Alfonso F, Perez-Vizcayno MJ, Garcia Del Blanco B, Garcia-Touchard A, Lopez-Minguez JR, Masotti M, Zueco J, Melgares R, Mainar V, Moreno R, et al. Everolimus-eluting stents in patients with bare-metal and drug-eluting in-stent restenosis: results from a patient-level pooled analysis of the RIBS IV and V trials. *Circ Cardiovasc Interv*. 2016;9(7):003479. doi: 10.1161/CIRCINTERVENTIONS.115.003479.
13. Holmberg J, Bhattachariya A, Alajbegovic A, Rippe C, Ekman M, Dahan D, Hien TT, Boettger T, Braun T, Sward K, et al. Loss of vascular myogenic tone in miR-143/145 knockout mice is associated with hypertension-induced vascular lesions in small mesenteric arteries. *Arterioscler Thromb Vasc Biol*. 2018;38(2):414–424. doi: 10.1161/ATVBAHA.
14. Hoffmann R, Mintz GS, Mehran R, Kent KM, Pichard AD, Satler LF, Leon MB. Tissue proliferation within and surrounding Palmaz-Schatz stents is dependent on the aggressiveness of stent implantation technique. *Am J Cardiol*. 1999;83:1170–1174.
15. Russo RJ, Silva PD, Yeager M. Coronary artery overexpansion increases neointimal hyperplasia after stent placement in a porcine model. *Heart*. 2007;93:1609–1615. doi: 10.1136/hrt.2006.105981.
16. Gunn J, Arnold N, Chan KH, Shepherd L, Cumberland DC, Crossman DC. Coronary artery stretch versus deep injury in the development of in-stent neointima. *Heart*. 2002;88:401–405.
17. Schwartz RS, Chronos NA, Virmani R. Preclinical restenosis models and drug-eluting stents: still important, still much to learn. *J Am Coll Cardiol*. 2004;44:1373–1385. doi: 10.1016/j.jacc.2004.04.060.
18. Kitahara H, Okada K, Kimura T, Yock PG, Lansky AJ, Popma JJ, Yeung AC, Fitzgerald PJ, Honda Y. Impact of Stent Size Selection on Acute and Long-Term Outcomes After Drug-Eluting Stent Implantation in De Novo Coronary Lesions. *Circ Cardiovasc Interv*. 2017 Oct;10(10):e004795. doi: 10.1161/CIRCINTERVENTIONS.116.004795. PMID: 28951394.
19. Costa RA, Mandal SC, Hazra PK, Chopda M, Chandra P, Damiani LP, Abizaid A, Hiremath S. Sirolimus-Coated Balloon With a Microsphere-Based Technology for the Treatment of De Novo or Restenotic Coronary Lesions. *Cardiovasc Revasc Med*. 2022 Dec;45:18-25. doi: 10.1016/j.carrev.2022.08.037. Epub 2022 Sep 5. PMID: 36192319.
20. Bo Xu, Runlin Gao, Jian'an Wang, Yuejin Yang, Shaoliang Chen, Bin Liu, Fang Chen, Zhanquan Li, Yaling Han, Guosheng Fu, Yelin Zhao, Junbo Ge, A Prospective, Multicenter, Randomized Trial of Paclitaxel-Coated Balloon Versus Paclitaxel-Eluting Stent for the Treatment of Drug-Eluting Stent In-Stent Restenosis: Results From the PEPCAD China ISR Trial, *JACC: Cardiovascular Interventions*, Volume 7, Issue 2, 2014, Pages 204-211, ISSN 1936-8798, <https://doi.org/10.1016/j.jcin.2013.08.011>.

ABBREVIATIONS

ISR - In-stent Restenosis

RCA- Right Coronary Artery

LCX- Left circumflex coronary artery

DES- Drug Eluting Stent

CAG- Coronary angiogram

PCI- Percutaneous coronary intervention

UNDER PEER REVIEW