

Huge ganglioneuroma of the suprarenal gland: a surgery case report of a rare location

Abstract:

Ganglioneuroma is a benign neoplasm that originate from neural crest cells and characterized by well-differentiated cells such as mature Schwann cells, ganglion cells. Ganglioneuroma rarely occurs in the adrenal gland, making diagnosis challenging. Ganglioneuromas do not produce excessive catecholamines or steroid hormones, and they often remain clinically silent and asymptomatic, even when they reach a large size. The detection of this tumor has improved due to the availability of imaging techniques such as ultrasonography, computed tomography, and magnetic resonance imaging. However, histopathology remains the gold standard for confirming the diagnosis definitively and distinguishing it from a malignant tumor.

Key words: adrenal ganglioneuroma, computed tomography, non-secreting tumor, surgical resection

Introduction:

Ganglioneuroma is a benign tumor derived from the neural crest, composed of mature ganglion cells and Schwann cells. Adrenal localization and occurrence in young adults are very rare [1]. Through this case, we report a giant non-secreting ganglioneuroma of the right adrenal gland in a young individual.

Case report:

A 17-year-old patient, with no notable medical history, presented with chronic right flank pain. Clinical examination suggested a palpable mass on lumbar contact. A CT scan revealed a right adrenal compartment mass measuring 18x13x12 cm with homogeneous tissue density and mild contrast uptake, in contact with the inferior vena cava, likely of neurogenic origin (figure 1). The laboratory tests were normal, ruling out a secreting mass.

The surgical exploration of our subject through laparotomy revealed a large right adrenal mass in contact with the superior vena cava and the renal vein (figure 2, figure 3). Histological examination of the specimen showed a benign tumor proliferation composed of spindle-shaped cells, with elongated nuclei without cytonuclear atypia or mitosis. This proliferation is organized in bundles with clear neural differentiation and includes mature ganglion cells in some areas, indicative of a ganglioneuroma.

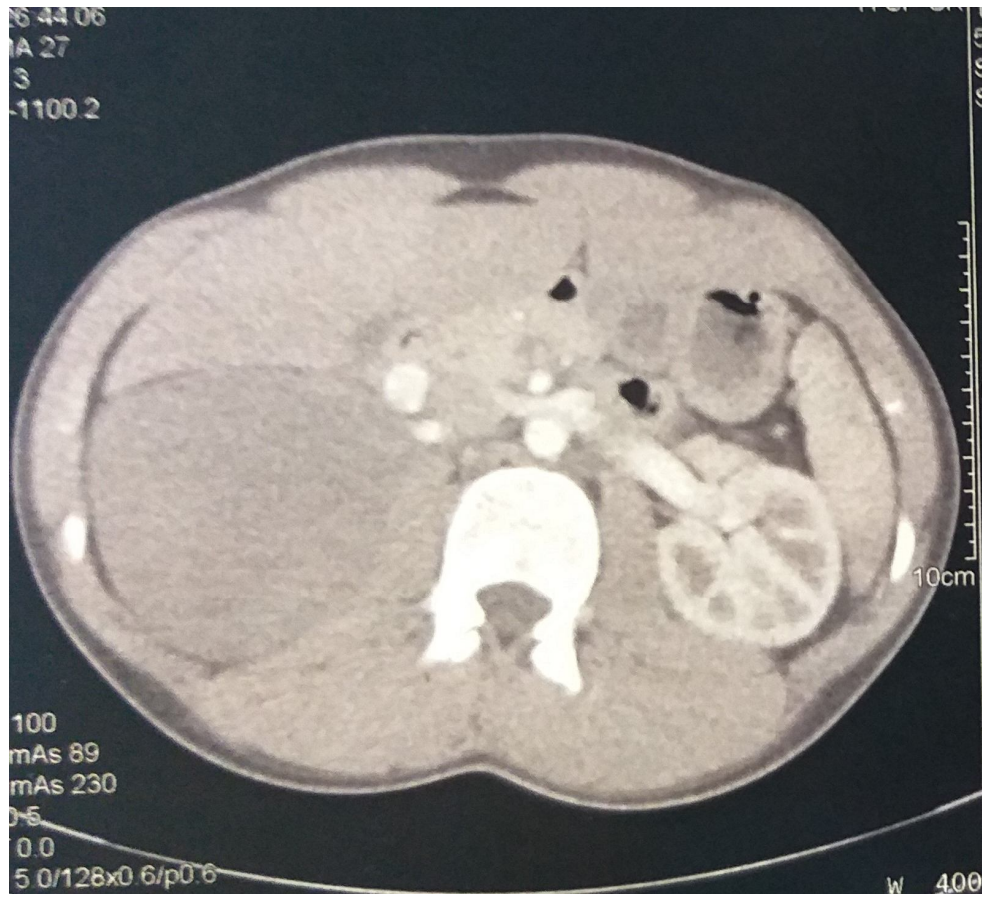


Figure 1: Right adrenal compartment mass measuring 18x13x12 cm with homogeneous tissue density and mild contrast uptake, in contact with the inferior vena cava, likely of neurogenic origin.

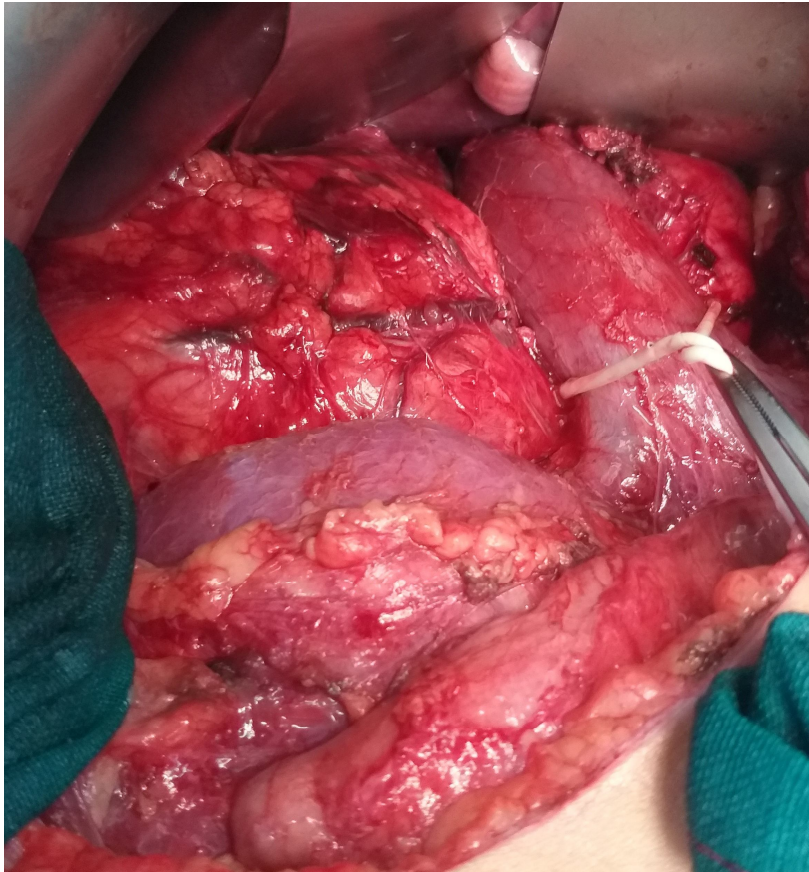

Figure 2: Intraoperative view showing the vascular relationships where the mass is compressing the inferior vena cava and the right renal vein.

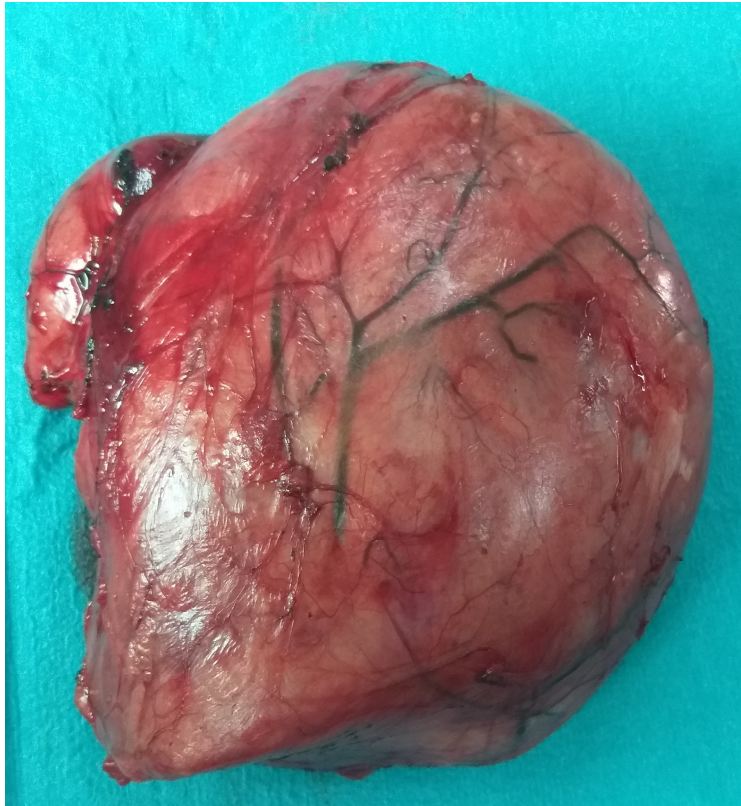

Figure 3: Surgical specimen.

Discussion:

Ganglioneuroma is a rare benign tumor of neuroectodermal origin, developed from the sympathetic nervous system. It consists of mature ganglion cells and stroma containing nerve cells associated with a Schwann cell component, unlike neuroblastoma and ganglioneuroblastoma, which are composed of more immature ganglion cells with a greater potential for progression [2]. Adrenal ganglioneuromas are more frequent in children and individuals in their fourth or fifth decade of life, and rarely in adulthood. Women are more frequently affected, with a male-to-female ratio of 0.75. The most common sites of ganglioneuromas are the retroperitoneal region (32-52%), the mediastinal region (39-43%), or the cervical region (8-9%), and only rarely in the adrenal gland [3]

Clinically, ganglioneuromas are often asymptomatic and are discovered incidentally during radiological examinations performed for other conditions. In some cases, they may present with nonspecific abdominal pain or an abdominal mass. Ganglioneuromas can compress surrounding organs, leading to various symptoms, including urinary,

neurological, vascular, or digestive disorders. Typically, these tumors are non-functional, meaning they do not produce excess hormones. However, in rare cases, ganglioneuromas may secrete substances such as catecholamines or vasoactive intestinal peptide, which can cause symptoms such as diarrhea and hypertension [4]. In our case, the patient is a 17-year-old who presented with chronic pain in the right flank without any other associated symptoms.

Ganglioneuromas are typically discovered incidentally on imaging studies. Ultrasound Shows a well-defined, homogeneous, and hypoechoic mass [5]. Computed Tomography Reveals a homogeneous or slightly heterogeneous mass that often surrounds major blood vessels without compressing or occluding them. The tumor is well-defined, hypodense, and poorly enhanced by contrast medium. Calcifications are seen in approximately 42-60% of cases, with early enhancement of linear septae and delayed heterogeneous contrast uptake in some cases [6]. Magnetic Resonance Imaging T1-weighted shows a homogeneous mass with a signal intensity lower than that of the liver, while T2-weighted MRI shows a heterogeneous mass with a predominant signal intensity higher than that of the liver. T2-weighted MRI also shows no absolute change in signal intensity on chemical shift imaging. The high, heterogeneous signal intensity on T2-weighted images is presumed to be caused by a combination of the myxoid matrix and relatively low numbers of ganglion cells. These imaging characteristics are important for the diagnosis and management of patients with ganglioneuromas [7]. For our subject, the CT scan revealed a right adrenal compartment mass measuring 18x13x12 cm with homogeneous tissue density and mild contrast uptake, in contact with the inferior vena cava, likely of neurogenic origin.

The laboratory tests are only of interest in the differential diagnosis, the search for urinary metanephrines and chromogranin A allows to confirm the secreting or non-secreting nature of the lesion and to guide towards an ectopic paraganglioma. The measurement of NSE, an enzyme expressed by neurons and cells of the APUD system ("amine precursor uptake and decarboxylation"), is useful for the diagnosis of neuroblastoma. In our case, the ganglioneuroma was non-secreting. The diagnosis of ganglioneuroma could be made thanks to a fine needle aspiration biopsy. Some authors emphasize that cytological aspiration is a less traumatic examination guiding the diagnosis [8]

The definitive diagnosis will only be made after a histological study of the surgical specimen. Indeed, complete analysis of the excised specimen is necessary due to the possibility of neuroblastoma or pheochromocytoma components within the ganglioneuroma. Surgical treatment remains the mainstay, consisting of tumor excision;

a procedure that becomes more challenging when the tumor is large and has intimate relationships with adjacent structures, particularly major vessels such as the inferior vena cava and aorta. The approach is generally through a transperitoneal laparotomy, primarily for large masses. However, a laparoscopic approach remains possible and even preferred for small, well-defined retroperitoneal masses without intimate involvement with major vessels [9]. The surgical exploration of our subject through laparotomy revealed a large right adrenal mass in contact with the superior vena cava and the renal vein. Histological examination of the specimen showed a benign tumor proliferation composed of spindle-shaped cells, with elongated nuclei without cytonuclear atypia or mitosis. This proliferation is organized in bundles with clear neural differentiation and includes mature ganglion cells in some areas, indicative of a ganglioneuroma.

The progression of these tumors is slow, but an increase in volume is common in the absence of treatment. The prognosis is good with complete excision, and complications are mainly mechanical in nature. Local recurrence is rare; however, the possibility of malignant transformation into a ganglioneuroblastoma exists, highlighting the importance of prolonged surveillance [10].

Conclusion:

The diagnostic approach to an adrenal incidentaloma is well established. This involves thorough endocrine exploration and assessment of radiological characteristics, which can confirm the precise diagnosis. However, in some cases, confirmation of the diagnosis can only be achieved through histological examination, as is the case with this patient.

Conflicts of Interest

The authors declare no conflicts of interest.

Author Contributions

All authors have read and approved the final version of the manuscript.

Ethical Approval:

As per international standards or university standards written ethical approval has been collected and preserved by the author(s).

Consent

As per international standards, parental written consent has been collected and preserved by the author(s).

Disclaimer (Artificial intelligence)

Option 1:

Author(s) hereby declare that NO generative AI technologies such as Large Language Models (ChatGPT, COPILOT, etc) and text-to-image generators have been used during writing or editing of manuscripts.

Option 2:

Author(s) hereby declare that generative AI technologies such as Large Language Models, etc have been used during writing or editing of manuscripts. This explanation will include the name, version, model, and source of the generative AI technology and as well as all input prompts provided to the generative AI technology

Details of the AI usage are given below:

- 1.
- 2.
- 3.

References

[1] Juana Olivar and al. Adrenal ganglioneuroma: Clinical and surgical dilemma concerning an incidental finding. *Endocrinol Nutr.* 2013;60(10):e37-e40

[2] Baizri H, Zoubeir Y, Elhadri S, Elanzaoui J, Chahbi Z, Kaddouri S, Qacif H, Touiti D, Zyani M. Une cytolysse hépatique révélant un ganglioneurome surrénalien [Hepatic cytolysis

revealing adrenal ganglioneuroma]. Pan Afr Med J. 2014 Mar 21;17:224. French. doi: 10.11604/pamj.2014.17.224.3744. PMID: 25170368; PMCID: PMC4145279.

[3] Patel RD, Vanikar AV and Trivedi HL: Non-functional adrenal gland ganglioneuroma: case report. Res J Endocrinol Metab 2013, 1:1. <http://dx.doi.org/10.7243/2053-3640-1-1>

[4] S.Attafi et al. Un incidentalome surrenalien inhabituel : le ganglioneurome. Journal africain d'urologie, ISSN : 1110-5704, Vol : 22, Numéro : 4, Page : 240-242

[5] Yamaguchi K, Hara I, Takeda M, Tanaka K, Yamada Y, Fujisawa M, Kawabat G: Two cases of ganglioneuroma. Urology 2006, 67:622.e1-e4.

[6] Zugor V, Schott GE, Kühn R, Labanaris AP: Retroperitoneal ganglioneuroma in childhood—a presentation of two cases. Ped Neonatology 2009, 50:173–176.

[7] Majbar et al.: Imaging features of adrenal ganglioneuroma: a case report. BMC Research Notes 2014 7:791.

[8] Pelletier F, Manzoni P, Heyd B, et al. Ganglioneurome rétropéritonéal révélé par une colique néphrétique compliquée. La Revue de médecine interne 2006; 27:409–1

[9] N. Rebai, A. Chaabouni, M. Bouassida, M. Fourati, K. Chabchoub, M. Hadj Slimen, M.N. Mhiri. Le ganglioneurome rétropéritonéal: À propos de 5 cas et revue de la littérature. African Journal of Urology (2013) 19, 215–218

[10] Adraoui J, El Jai SR, Chehab F, Khaiz D, Bouzidi A. Ganglioneurome rétropéritonéal. Journal Marocain d'Urologie 2008; 10:34–6.