

Molecular diagnosis of *Mycoplasma haemofelis* and 'Candidatus *Mycoplasma haemominutum*' in domestic feline: A case report

ABSTRACT

The aim of this work was to report the molecular diagnosis of *Mycoplasma haemofelis* and 'Candidatus *Mycoplasma haemominutum*' in a domestic feline. *Mycoplasma* spp. are pleomorphic bacteria that parasitize the surface of red blood cells in several domestic species, mainly cats, being responsible for feline mycoplasmosis, which can cause hemolytic anemia. Cats can become infected through blood transfusions, social interactions via fights and flea bites. In this report, the patient exhibited in the clinical exam, pale and icteric mucous membranes, and enlargement of the popliteal and submandibular lymph nodes. Based on the symptoms presented, a blood sample was collected to search for hemoparasites using blood smears and also molecular examination by polymerase chain reaction (PCR). The blood smear revealed inclusions characteristic of *Mycoplasma* spp. observed in red blood cells, and the diagnosis of mycoplasmosis was confirmed by PCR. This report highlights the importance of screening for hemoparasites in the feline clinical routine, with molecular tests being the most recommended due to their high sensitivity and specificity.

Keywords: Cats, hemotropic mycoplasma, PCR.

1. INTRODUCTION

Feline mycoplasmosis also called Feline hemotropic mycoplasmosis (FHM) or Feline infectious anemia is caused by the bacteria of the genus *Mycoplasma*. *Mycoplasma haemofelis* (Mhf), 'Candidatus *Mycoplasma haemominutum*' (CMhm) and 'Candidatus *Mycoplasma turicensis*' (CMt) are gram-negative bacteria, showing a coccoid form, that parasitize the surface of red blood in felines (1). Infection occurs through blood transfusions, vertical transmission, social interactions via fights and flea bites (*Ctenocephalides felis*) (2).

The majority of related cases of mycoplasmosis are subclinical adhesion of this bacteria to the surface of erythrocytes can lead to its destruction by the mononuclear phagocytic system, causing hemolytic anemia, from mild to severe (3). The majority of infected cats are asymptomatic, but when the symptoms appear, the clinical signs include anorexia, fever, loss of weight and pale and/or jaundiced mucous membranes (4). Splenomegaly, jaundice, and lymphadenopathy may also be present (5).

The infection is considered opportunistic, occurring mainly in immunosuppressed animals, such as those that are stressed animals or showing co-infections, mainly by retroviruses, like feline leukemia virus (FeLV) and feline immunodeficiency virus (FIV) (6).

44 The clinic manifestation depends on the pathogenicity of the bacteria, *M.haemofelis* being the
45 most pathogenic species, able to cause disease in immunocompetent animals, while the
46 infection by '*Candidatus Mycoplasma haemominutum*' is considered less pathogenic, being
47 detected many times through PCR in healthy animals (7).

48

49 The diagnosis is based on the bacteria observation in blood smears, although it presents low
50 sensitivity. Therefore the molecular methods, as Polymerase chain reaction (PCR), are the
51 recommendation for the diagnosis, because they have high sensitivity and specificity (1).

52

53 The aim of this study was to relate the molecular diagnosis of *Mycoplasma haemofelis* and
54 '*Candidatus Mycoplasma haemominutum*' in domestic feline.

55

56 **2. PRESENTATION OF CASE**

57

58 A feline, male, neutered, adult, and mixed breed was attended at the veterinary hospital of the
59 Federal University of Pelotas. Upon inspection, skin lesions were found on the back, with
60 pruritus and an ulcerated nodule on the ear. In the anamnesis, the owner reported that they had
61 adopted the animal about two months ago, already showing the aforementioned lesions. On
62 clinical examination, pale and icteric mucous membranes were observed, as well as enlarged
63 popliteal and submandibular lymph nodes. The other evaluated parameters were within the
64 physiological limits for the feline species.

65

66 As complementary exams, a blood sample was collected by venipuncture for blood count and
67 biochemical examination. Due to the symptoms observed, an aliquot was sent for hemoparasite
68 research through blood smear and molecular examination by polymerase chain reaction (PCR).
69 An ultrasound imaging examination was also performed and due to the skin lesions, collection
70 of material for cytology was performed with the aid of a cervical brush.

71

72

73

74

75 **3. Results and Discussion**

76

77 The Complete Blood Count Test (Table 1) showed macrocytic/hypochromic anemia, with
78 regeneration due to the presence of reticulocytes. Anisocytosis, polychromasia and the
79 presence of Howell-Jolly bodies were also observed. There are two possible mechanisms for
80 the occurrence of anemia: direct damage to the red blood cell membrane by the bacteria and
81 immunomodulation, resulting in a decline in the number of red blood cells due to hemolysis (2).

82 Some studies indicate that *Mycoplasma* spp. is a predisposing condition for anemia and
83 demonstrate that positive cats are more likely to be anemic than negative cats (8, 9, 10).

84

85 Thrombocytopenia was also observed and the presence of jaundiced plasma. Decrease in
86 platelets was described by other authors, as Martinez *et al.* (11), that realized hematologic
87 analysis in domestic felines diagnosed with mycoplasmosis in the municipality of Osasco, found
88 thrombocytopenia in 46.7% of the cats and by Raimundo *et al.* (9), in Rio de Janeiro, who
89 observed that of the nine positive cats for *M. haemofelis*, eight had thrombocytopenia. However,
90 in these same studies, negative animals also had low platelet concentrations, indicating that
91 thrombocytopenia is probably related to other causes, since changes in platelet counts are not
92 consistent with hemoplasma infections (12).

93

94 Another alteration observed in the blood count was an increase in total plasma proteins (TPP)
95 (9.0 g/dL). The concentration of total proteins is normally within reference values, but in some
96 cases it may be increased due to hyperglobulinemia, associated with the host's immune
97 response, or in cases of dehydration (13).

98

99 **Table 1:** Result of the feline blood count diagnosed with Mycoplasmosis.

Eritrogram	Result	Reference value	Leucogram	Result	Reference value
Red Blood cells	3.1 milhões/ul	5-10 milhões/ul	Total leukocytes	9800 /uL	5500-19500 /uL
Hemoglobine	6.0 g/dL	8-15 g/dL	Neutrophils	3430 /uL	2500-12500 /uL
Hematocrit	22.8 %	24-45 %	Lymphocytes	5586/uL	1500-7000/uL
MCV	74.3 fL	39-55 fL	Monocytes	686 /uL	0-850 /uL
MCHC	26.3 %	31-35 %	Eosinophils	98 /uL	0-1500 /uL
Platelets	63 (mil/uL)	300-800 (mil/uL)	TPP	9.0 g/dL	6-8 g/dL

100

101 Ultrasonography detected heterogeneous splenomegaly with splenic lymph node enlargement
102 and hepatomegaly, which may be related to extramedullary hematopoiesis, erythrocyte
103 sequestration and/or increased activity of splenic macrophages(2).

104

105 In the investigation of hemoparasites through blood smears, characteristic inclusion bodies of
106 *Mycoplasma* spp. in red blood cells (Figure 1). To confirm the diagnosis found in the direct
107 examination, PCR was performed. Total genomic DNA (gDNA) extraction using the PetNAD™
108 Nucleic Acid Co-prep Kit column was performed. To detect *Mycoplasma haemofelis* DNA (Mhf)
109 and/or '*Candidatus Mycoplasma haemominutum*' (CMhm) a conventional PCR was performed,
110 in which primers directed to the 16S rRNA gene for Mhf and CMhm were used (7,14) where the

111 forward primer (Hf-F, 5'-ACGAAAGTCTGATGGAGCAATA-3') and reverse primer (Hf-R, 5'-
112 ACGCCCAATAAATCCGRATAAT-3') produced amplicons of 170 bp of Mhf and 193 bp of
113 CMhm, **confirming** the diagnosis of mycoplasmosis (Figure 2).

114

115 **Figure 1.**Photomicrograph showing inclusion bodies in red blood cells, characteristic of
116 *Mycoplasma* spp., observed through optical microscopy, 1000x magnification

117

118

119

120

121

122

123


124

125

126

127

128



129 **Figure 2.** 1.5% agarose gel after electrophoresis. *Mycoplasma* detection by amplification of the
130 16S rRNA gene for Mhf (170 bp) and CMhm (193 bp) by conventional PCR. **PM:** Molecular
131 weight marker (100 bp), **P1:**Mhf positive control; **P2:**CMhm positive control; **1:**Mhf and CMhm
132 positive sample; **N:**Negative control

133

134

135

136

137

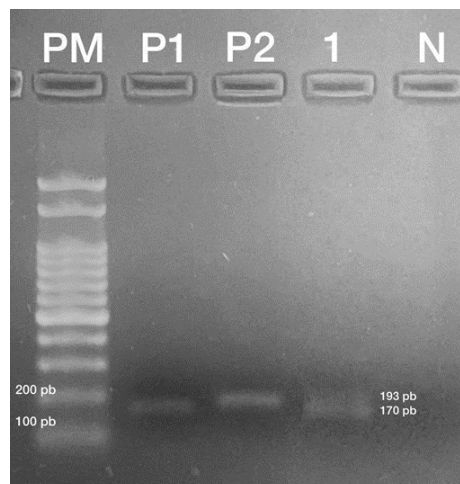
138

139

140

141

142



143 Although the bacteria was observed in the smear and the PCR was positive, some authors
144 comparing the two diagnostic techniques indicated greater sensitivity and specificity of PCR, as
145 Raimundo *et al.* (9), in Rio de Janeiro and Pekel and Duru (15) in Turkey, who, analyzing blood
146 samples from domestic cats **finding** 11.2% and 22.8% of positive samples for *Mycoplasma* spp.
147 using PCR and 6% and 13% with smear. Despite being commonly used for *Mycoplasma* spp.
148 research, the blood smear technique has low specificity and sensitivity, with the possibility of
149 false positive and negative results (16).

150

151 *Candidatus Mycoplasma haemominutum* (CMhm) is the most cited hemotropic *Mycoplasma* of
152 felines, when compared to *Mycoplasma haemofelis* (Mhf). Some studies confirm **this**, such as
153 Aragão-de-Souza (17) and Raimundo *et al.* (9), that reported a prevalence of 7.96% e 11.7% for
154 CMhm and 1.96% and 4.6% for Mhf. These authors **along with** Jenkins *et al.* (18) and
155 Kamyngkird *et al.* (19), **noted** the same association of both species, **in** the feline of this report.

156

157 Cats with coinfections, mainly by retrovirus are more susceptible to infection, **due to**
158 **immunosuppression**. Some studies were performed with the **aim** to determine the prevalence
159 and risk factors for hemoplasmas infections in domestic cats naturally infected by feline
160 immunodeficiency virus (FIV) and/or feline leukemia (FeLV), as Duarte *et al.* (20) who observed
161 that 45% of FIV+ cats and 23.5% of FeLV+ cats were positive for *Mycoplasma* spp. Maciel *et al.*
162 (21) in southern Brazil, also found that of the 18 cats positive for *Mycoplasma haemofelis*,
163 33.3% had co-infection with FeLV, 5.6% with FIV, and 5.6% with FIV and FeLV. In a study
164 carried out by Vergara *et al.* (22) in Chile, FIV positive cats had 3.77 times more risk of being
165 infected by **hemoplasma infection** than negative ones.

166

167 Outdoor male felines are more predisposed to infection, due to greater exposure to vectors, as
168 well as being more subject to fights and co-infections (23). Maciel *et al.* (21), **while**
169 **analysing** factors associated with *Mycoplasma haemofelis* infection in cats in the state of Santa
170 Catarina, Brazil, observed that male cats were seven times more likely to be infected than
171 females (OR 7.07), **and** those that had access to the street were twice as likely as those who
172 lived only indoors (OR 2.26). Petry *et al.* (24), determining the prevalence of hemotropic
173 mycoplasmas in cats in the central region of Rio Grande do Sul, observed that of the infected
174 animals, 75% (21/28) were males and 25% (7/28), females. In New Zealand, Jenkins *et al.* (18),
175 **identified a fivefold higher risk of infection in males**.

176

177 In the analysis of the skin cytology of the patient **in** the present report, the presence of
178 *Sporothrix* spp. was observed, indicating a case of sporotrichosis, in addition, he was rescued
179 from the street, corroborating the hypothesis that cats that present co-infections and **outdoor**
180 **access** are more predisposed to developing mycoplasmosis.

181

182 The recommended therapy consisted of **administration** of Doxycycline, 10 mg/kg, orally, SID, for
183 21 days. Doxycycline is a broad-spectrum antibiotic, which does not **exhibit** nephrotoxicity and
184 with reduced side effects and hepatotoxicity in cats (2). Furthermore, this drug is bacteriostatic,
185 liposoluble, rapidly absorbed, reaching satisfactory serum and intracellular concentrations (25).

186

187 It is important to emphasize that oral administration of doxycycline can lead to a severe
188 inflammatory process, resulting in esophagitis and esophageal stenosis in cats. Thus, to avoid

189 this problem, water or wet food should be provided after administration of the drug, in order to
190 reduce the time of contact of the drug with the esophageal mucosa (26).

191

192 **4. CONCLUSION**

193

194 From this report, it is evident the importance of researching hemoparasites in the feline clinical
195 **practice is crucial**, as the confirmation of the **causative agent** through complementary exams is
196 of paramount importance for the ideal treatment to be advocated. And for this, molecular tests
197 are the most suitable for the diagnosis, as they have high sensitivity and specificity.

198

199 **COMPETING INTERESTS**

200 Authors have declared that no competing interests exist.

201

202 **REFERENCES**

203 1. Barker E, Tasker S. Haemoplasmas: Lessons learnt from cats. *New Zealand Veterinary*
204 *Journal*. 2013;61(4):184-192.

205 2. Tasker S. Haemotropic mycoplasmas: what's their real significance in cats? *Journal of Feline*
206 *Medicine and Surgery*. 2010;12(5):369-381.

207 3. Messick JB. Hemotropic mycoplasmas (hemoplasmas): a review and new insights into
208 pathogenic potential. *Veterinary Clinical Pathology*. 2004;33(1):2-13.

209 4. Hicks CAE, Willi B, Riond B, Novacco M, Meli ML, Stokes CR, Helps CR, Hofmann-Lehmann
210 R, Tasker S. Protective Immunity against Infection with *Mycoplasma haemofelis*. *Clinical and*
211 *Vaccine Immunology*. 2015;22(2):108-18.

212 5. Thrall MA, Weiser G, Allison RW, Campbell TW. *Veterinary hematology and clinical*
213 *chemistry*. 2nd ed. Ames: Wiley-Blackwell, 2012.

214 6. Harrus S, Klement E, Aroch I, Stein T, Bark H, Lavy E, Mazaki-Tovi M, Baneth G.
215 Retrospective study of 46 cases of feline haemobartonellosis in Israel and their relationships
216 with FeLV and FIV infections. *Veterinary Record*. 2002;151(3):82-85.

217 7. Jensen WA, Lappin MR, Kamkar S, Reagan WJ. Use of a polymerase chain reaction assay
218 to detect and differentiate two strains of *Haemobartonella felis* in naturally infected cats.
219 *American Journal of Veterinary Research*. 2001;62(4):604-608.

220 8. Roura X, Peters IR, Altet L, Tabar MD, Barker EN, Planellas M, Helps CR, Francino O, Shaw
221 SE, Tasker S. Prevalence of hemotropic mycoplasmas in healthy and unhealthy cats and dogs
222 in Spain. *Journal of Veterinary Diagnostic Investigation*. 2010;22(2):270-274.

223 9. Raimundo JM, Guimarães A, Rodrigues RB, Botelho CFM, Peixoto MP, Pires MS, Machado
224 CH, Santos HA, Massard CL, André MR, Machado RZ, Baldani CD. Hematological changes
225 associated with hemoplasma infection in cats in Rio de Janeiro, Brazil. *Revista Brasileira de*
226 *Parasitologia Veterinária*. 2016;25(4):441-449.

227 10. Obara H, Fujihara M, Watanabe Y, Ono HK, Harasawa R. A feline hemoplasma *Candidatus*
228 *Mycoplasma haemominutum*, detected in dog in Japan. *Journal of Veterinary Science*.
229 2011;73(6):841-843.

- 230 11. Martinez MS, Santos IFC, Kolber M, Del Poente MD.
231 Análise hematológica em gatos domésticos (felis silvestris catus) diagnosticados com
232 micoplasmaose em Osasco, São Paulo – Brasil. Revista Lusófona de Ciência e
233 Medicina Veterinária. 2016;8:1-9.
- 234 12. Sykes JE. Feline hemotropic mycoplasmosis (feline hemobartonellosis). Veterinary Clinics of
235 North America: Small Animal Practice. 2003;33(4):773-789.
- 236 13. Tasker S. Haemoplasmosis. In Michael, J. D. & Kohn, B. BSAVA Manual of Canine and
237 Feline Haematology and Transfusion Medicine. 2ª edição. p. 67-72 Wiley Gloucester, 2012.
- 238 14. Tasker S, Binns SH, Day MJ, Gruffydd-Jones TL, Harbour DA, Helps CR, Jensen WA, Olver
239 CS, Lappin MR. Use of a PCR assay to assess the prevalence and risk factors for Mycoplasma
240 haemofelis and 'Candidatus Mycoplasma haemominutum' in cats in the United Kingdom.
241 Veterinary Record. 2003;152(7):193-198.
- 242 15. Pekel O, Duru SY. Determination of Mycoplasma haemofelis Incidence in Cats Visiting
243 Veterinary Clinics in Kırıkkale. International Journal of Veterinary and Animal Research.
244 2022;5(2):40-46.
- 245 16. Sykes JE. Feline hemotropic Mycoplasmas. Journal of Veterinary Emergency and Critical
246 Care. 2010;20(1):62-69.
- 247 17. Aragão-de-sousa SKS, Sampaio-Junior FD, Sousa LO, Santos RC, Gonçalves EC, Scofield
248 A, Góes-Cavalcante G. Diagnóstico molecular da infecção por hemoplasmas
249 em gatos domésticos naturalmente infectados da cidade de Belém, Pará. Pesquisa Veterinária
250 Brasileira. 2013;33(9):1116-1120.
- 251 18. Jenkins KS, Dittmer KE, Marshall JC, Tasker S. Prevalence and risk factor analysis of feline
252 haemoplasma infection in New Zealand domestic cats using a real-time PCR assay. Journal of
253 Feline Medicine and Surgery. 2013;15(12):1063-1069.
- 254 19. Kamyngkird K, Jiyipong T, Amavisit P, Stich, Jittapalapong, S. Molecular detection of
255 Mycoplasma haemofelis, 'Candidatus Mycoplasma haemominutum' and 'Candidatus
256 Mycoplasma turicensis' of stray cats residing in Bangkok monasteries, Thailand. Agriculture and
257 Natural Resources. 2021;55(3):423-430.
- 258 20. Duarte A, Marques V, Correia JHD, Neto I, São Bráz B, Rodrigues C, Martins T, Rosado R,
259 Ferreira JP, Santos-Reis M, Tavares L. Molecular detection of haemotropic Mycoplasma
260 species in urban and rural cats from Portugal. Journal of Feline Medicine and Surgery.
261 2015;17(6):516-522.
- 262 21. Maciel AR, Biezu G, Cristo TG, Miletto LC, Maciel UC, Medeiros ALV, Xavier MGN,
263 Casagrande RA. Mycoplasma haemofelis infection and its correlation with feline leukemia virus
264 (FeLV) and feline immunodeficiency virus (FIV) in cats in Southern Brazil. Comparative
265 Immunology, Microbiology and Infectious Diseases. 2023;93:101941.
- 266 22. Vergara RW, Galleguillos FM, Jaramillo MG, Almosny NRP, Martínez PA, Behne PG,
267 Acosta-Jamett G, Muller A. Prevalence, risk factor analysis, and hematological findings
268 of hemoplasma infection in domestic cats from Valdivia, Southern Chile. Comparative
269 Immunology, Microbiology and Infectious Diseases. 2016;46:20-26.
- 270 23. Carli, E.; Trotta, M.; Chinelli, R.; Drigo, M.; Sinigoi, L.; Tosolini, P.; Furlanello, T.; Millotti, A.;
271 Caldin, M.; Solano-Gallego, L. Cytauxzoon sp. infection in the first endemic focus described in
272 domestic cats in Europe. Veterinary Parasitology. 2012;183(3-4):343-352.
- 273 24. Petry LS, Santos AP, Dornelles GL, Mello CBE, Silva AS, Dillmann JB, Lopes STA.
274 Hemotropic Mycoplasma in domestic cats from the central region of Rio Grande do Sul state,
275 Brazil. Ciência Animal. 2020;30(1):1-10.
- 276 25. Davoust B, Keundjian A, Rous V, Maurizi DP. Validation of chemoprevention of canine
277 monocytic ehrlichiosis with doxycycline. Veterinary Microbiology. 2005;107(3-4):279-283.
- 278 26. German AJ, Cannon MJ, Dye C, Booth MJ, Pearson GR, Reav CA, Gruffydd-Jones TJ.
279 Oesophageal strictures in cats associated with doxycycline therapy. Journal of Feline Medicine
280 and Surgery. 2005;7(1):33-41.
- 281

