

Case report

Molecular diagnosis of *Mycoplasma haemofelis* and 'Candidatus *Mycoplasma haemominutum*' in domestic feline, case report

Comment [AKHTER1]: : A

ABSTRACT

The aim of this work was to report the molecular diagnosis of *Mycoplasma haemofelis* and 'Candidatus *Mycoplasma haemominutum*' in a domestic feline. *Mycoplasma* spp. are pleomorphic bacteria that parasitize the surface of red blood cells of several domestic species, mainly cats, being responsible for feline mycoplasmosis, which can cause hemolytic anemia. The animal can become infected through blood transfusions, social interactions via fights and flea bites. The patient of this report presented in the clinical exam, pale and icteric mucous membranes, and enlargement of the popliteal and submandibular lymph nodes. Due to the symptoms presented, a blood sample was collected to search for hemoparasites through blood smears and also molecular examination by polymerase chain reaction (PCR). Through the blood smear, inclusions characteristic of *Mycoplasma* spp. were observed in red blood cells, and the diagnosis of mycoplasmosis was confirmed by PCR. From this report, the importance of researching hemoparasites in the feline clinical routine is evident, and molecular tests are the most indicated, as they have high sensitivity and specificity.

Keywords: Cats, hemotropic mycoplasma, PCR.

Comment [AKHTER2]: in

Comment [AKHTER3]: Cats

Comment [AKHTER4]: In this report, the patient exhibited...

Comment [AKHTER5]: Based on

Comment [AKHTER6]: using

Comment [AKHTER7]: The blood smear revealed

Comment [AKHTER8]: Delete

Comment [AKHTER9]: This report highlights the importance of screening for hemoparasites in the feline clinical routine, with molecular tests being the most recommended due to their high sensitivity and specificity.

1. INTRODUCTION

Feline mycoplasmosis also called Feline hemotropic mycoplasmosis (FHM) or Feline infectious anemia is caused by the bacteria of the genus *Mycoplasma*. *Mycoplasma haemofelis* (Mhf), 'Candidatus *Mycoplasma haemominutum*' (CMhm) e 'Candidatus *Mycoplasma turicensis*' (CMT) are gram-negative bacteria, showing a coccoid form, that parasitize the surface of red blood of felines (1). Infection occurs through blood transfusions, vertical transmission, social interactions via fights and flea bites (*Ctenocephalides felis*) (2).

Comment [AKHTER10]: genus

Comment [AKHTER11]: ?

Comment [AKHTER12]: in

The majority of related cases of mycoplasmosis are subclinical. However, adhesion of this bacteria to the surface of erythrocytes can lead to its destruction by the mononuclear phagocytic system, causing hemolytic anemia, from mild to severe (3). The majority of infected cats are asymptomatic, but when the symptoms appear, the clinical signs include anorexia, fever, loss of weight and pale and/or jaundiced mucous membranes (4). Splenomegaly, jaundice, and lymphadenopathy may also be present (5).

The infection is considered opportunistic, occurring mainly in immunosuppressed animals, as in stressed animals or presenting co-infections, mainly by retroviruses, like feline leukemia virus (FeLV) and the feline immunodeficiency virus (FIV) (6).

Comment [AKHTER13]: such as those that are

Comment [AKHTER14]: showing

Comment [AKHTER15]: delete

The clinic manifestation depends on the pathogenicity of the bacteria, *M. haemofelis* being the most pathogenic species, able to cause disease in immunocompetent animals, while the infection by '*Candidatus Mycoplasma haemominutum*' is considered less pathogenic, being detected many times through PCR in healthy animals (7).

The diagnosis is based on the bacteria observation in blood smears, although it presents low sensibility. In this way, the molecular methods, as Polymerase chain reaction (PCR), are the recommendation for the diagnosis, because they have high sensitivity and specificity (1).

Comment [AKHTER16]: sensitivity

Comment [AKHTER17]: Therefore

Therefore, the aim of this study was to relate the molecular diagnosis of *Mycoplasma haemofelis* and '*Candidatus Mycoplasma haemominutum*' in domestic feline.

Comment [AKHTER18]: Delete

2. PRESENTATION OF CASE

A feline, male, neutered, adult, and mixed breed was attended at the veterinary hospital of the Federal University of Pelotas. Upon inspection, skin lesions were found on the back, with pruritus and an ulcerated nodule on the ear. In the anamnesis, the tutor reported that he had adopted the animal about two months ago, already showing the aforementioned lesions. On clinical examination, pale and icteric mucous membranes were observed, as well as enlarged popliteal and submandibular lymph nodes. The other evaluated parameters were within the physiological limits for the feline species.

Comment [AKHTER19]: owner

Comment [AKHTER20]: they

As complementary exams, a blood sample was collected by venipuncture for blood count and biochemical examination, and due to the symptoms observed, an aliquot was sent for hemoparasite research through blood smear and molecular examination by polymerase chain reaction (PCR). An ultrasound imaging examination was also performed and due to the skin lesions, collection of material for cytology was performed with the aid of a cervical brush.

Comment [AKHTER21]: Delete
Start with Due to..

3. Results and Discussion

The Complete Blood Count Test (Table 1) showed macrocytic/hypochromic anemia, with regeneration due to the presence of reticulocytes. Anisocytosis, polychromasia and the presence of Howell-Jolly bodies were also observed. There are two possible mechanisms for the occurrence of anemia: direct damage to the red blood cell membrane by the bacteria and immunomodulation, resulting in a decline in the number of red blood cells due to hemolysis (2). Some studies indicate that *Mycoplasma* spp. is a predisposing condition for anemia and demonstrate that positive cats are more likely to be anemic than negative cats (8, 9, 10).

Thrombocytopenia was also observed and the presence of jaundiced plasma. Decrease in platelets was described by other authors, such as Martinez *et al.* (11), that realized hematologic analysis in

domestic felines diagnosed with mycoplasmosis in the municipality of Osasco, found thrombocytopenia in 46.7% of the cats and by Raimundo *et al.* (9), in Rio de Janeiro, who observed that of the nine positive cats for *M. haemofelis*, eight had thrombocytopenia. However, in these same studies, negative animals also had low platelet concentrations, indicating that thrombocytopenia is probably related to other causes, since changes in platelet counts are not consistent with hemoplasma infections (12).

Another alteration observed in the blood count was the increase in total plasma proteins (TPP) (9.0 g/dL). The concentration of total proteins is normally within reference values, but in some cases they may be increased due to hyperglobulinemia, associated with the host's immune response, or in cases of dehydration (13).

Comment [AKHTER22]: an

Comment [AKHTER23]: it

Table 1: Result of the feline blood count diagnosed with Mycoplasmosis.

Eritrogram	Result	Referencevalue	Leucogram	Result	Reference value
Red Blood cells	3.1 milhões/ul	5-10 milhões/ul	Total leukocytes	9800 /uL	5500-19500 /uL
Hemoglobine	6.0 g/dL	8-15 g/dL	Neutrophils	3430 /uL	2500-12500 /uL
Hematocrit	22.8 %	24-45 %	Lymphocytes	5586/uL	1500-7000/uL
MCV	74.3 fL	39-55 fL	Monocytes	686 /uL	0-850 /uL
MCHC	26.3 %	31-35 %	Eosinophils	98 /uL	0-1500 /uL
Platelets	63 (mil/uL)	300-800 (mil/uL)	TPP	9.0 g/dL	6-8 g/dL

Ultrasonography detected heterogeneous splenomegaly with splenic lymph node enlargement and hepatomegaly, which may be related to extramedullary hematopoiesis, erythrocyte sequestration and/or increased activity of splenic macrophages(2).

In the investigation of hemoparasites through blood smears, characteristic inclusion bodies of *Mycoplasma* spp. in red blood cells (Figure 1). To confirm the diagnosis found in the direct examination, PCR was also performed, where the sample was subjected to total genomic DNA (gDNA) extraction using the PetNAD™ Nucleic Acid Co-prep Kit column method. To detect *Mycoplasma haemofelis* DNA (Mhf) and/or '*Candidatus Mycoplasma haemominutum*' (CMhm) a conventional PCR was performed, in which primers directed to the 16S rRNA gene for Mhf and CMhm were used (7,14) where the forward primer (Hf-F, 5'-ACGAAAGTCTGATGGAGCAATA-3') and reverse primer (Hf-R, 5'-ACGCCAATAAATCCGRATAAT-3') produced amplicons of 170 bp of Mhf and 193 bp of CMhm, which confirmed the diagnosis of mycoplasmosis (Figure 2).


Comment [AKHTER24]: delete

Comment [AKHTER25]: delete and start with Total ...

Comment [AKHTER26]: was performed

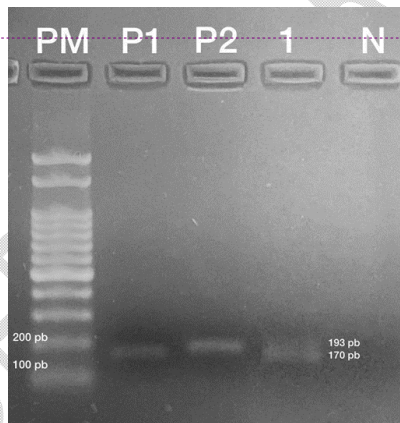
Comment [AKHTER27]: confirming

Figure 1. Photomicrograph showing inclusion bodies in red blood cells, characteristic of *Mycoplasma* spp., observed through optical microscopy, 1000x magnification



Comment [AKHTER28]: show the inclusions with an arrow in image

Figure 2. 1.5% agarose gel after electrophoresis. *Mycoplasma* detection by amplification of the 16S rRNA gene for Mhf (170 bp) and CMhm (193 bp) by conventional PCR. **PM:** Molecular weight marker (100 bp), **P1:** Mhf positive control; **P2:** CMhm positive control; **1:** Mhf and CMhm positive sample; **N:** Negative control



Comment [AKHTER29]: Designate the specific bands in image with marker

Although the bacteria was observed in the smear and the PCR was positive, some authors comparing the two diagnostic techniques indicated greater sensitivity and specificity of PCR, as Raimundo *et al.* (9), in Rio de Janeiro and Pekel and Duru (15) in Turkey, who, analyzing blood samples from domestic cats, found respectively 11.2% and 22.8% of positive samples for *Mycoplasma* spp. using PCR and 6% and 13% with smear. Despite being commonly used for *Mycoplasma* spp. research, the blood smear technique has low specificity and sensitivity, with the possibility of false positive and negative results (16).

Comment [AKHTER30]: finding

Candidatus Mycoplasma haemominutum (CMhm) is the most cited hemotropic *Mycoplasma* of felines, when compared to *Mycoplasma haemofelis* (Mhf). Some studies confirm that information, such as Aragão-de-Souza (17) and Raimundo *et al.* (9), that reported a prevalence of 7.96% e 11.7% for

Comment [AKHTER31]: this

CMhm and 1.96% e 4.6% for Mhf. These same authors and others, as Jenkins et al. (18) e Kamyngkird et al. (19), related the same association of both species, as the feline of this report.

- Comment [AKHTER32]: and
- Comment [AKHTER33]: delete
- Comment [AKHTER34]: along with
- Comment [AKHTER35]: and
- Comment [AKHTER36]: noted
- Comment [AKHTER37]: in
- Comment [AKHTER38]: due to immunosuppression
- Comment [AKHTER39]: aim

Cats with coinfections, mainly by retrovirus are more susceptible to infection, due the fact that the immunosuppressed animals are more predisposed to develop the disease. Some studies were performed with the idea to determine the prevalence and risk factors for hemoplasmas infections in domestic cats naturally infected by feline immunodeficiency virus (FIV) and/or feline leukemia (FeLV), as Duarte et al. (20) who observed that 45% of FIV+ cats and 23.5% of FeLV+ cats were positive for *Mycoplasma* spp. Maciel et al. (21) in southern Brazil, also found that of the 18 cats positive for *Mycoplasma haemofelis*, 33.3% had co-infection with FeLV, 5.6% with FIV, and 5.6% with FIV and FeLV. In a study carried out by Vergara et al. (22) in Chile, FIV positive cats had 3.77 times more risk of being infected by hemoplasmas than negative ones.

- Comment [AKHTER40]: hemoplasma infection

Outdoor male felines are more predisposed to infection, due to greater exposure to vectors, as well as being more subject to fights and co-infections (23). Maciel et al. (21), analyzing factors associated with *Mycoplasma haemofelis* infection in cats in the state of Santa Catarina, Brazil, observed that male cats were seven times more likely to be infected than females (OR 7.07), while those that had access to the street were twice as likely as those who lived only indoors (OR 2.26). Petry et al. (24), determining the prevalence of hemotropic mycoplasmas in cats in the central region of Rio Grande do Sul, observed that of the infected animals, 75% (21/28) were males and 25% (7/28), females. In New Zealand, Jenkins et al. (18), analyzing the risk factors for infection by hemotropic *Mycoplasmas* in cats, identified five times more chances of males becoming infected.

- Comment [AKHTER41]: while analysing

- Comment [AKHTER42]: and

- Comment [AKHTER43]: delete

- Comment [AKHTER44]: identified a fivefold higher risk of infection in males.

- Comment [AKHTER45]: in

In the analysis of the skin cytology of the patient of the present report, the presence of *Sporothrix* spp. was observed, indicating a case of sporotrichosis, in addition, he was rescued from the street, corroborating the hypothesis that cats that present co-infections and with access to the street are more predisposed to developing mycoplasmosis.

- Comment [AKHTER46]: outdoor access

The recommended therapy consisted of the use of Doxycycline, 10 mg/kg, orally, SID, for 21 days. Doxycycline is a broad-spectrum antibiotic, which does not present nephrotoxicity and with reduced side effects and hepatotoxicity in cats (2). Furthermore, this drug is bacteriostatic, liposoluble, rapidly absorbed, reaching satisfactory serum and intracellular concentrations (25).

- Comment [AKHTER47]: administration

- Comment [AKHTER48]: exhibit

It is important to emphasize that oral administration of doxycycline can lead to a severe inflammatory process, resulting in esophagitis and esophageal stenosis in cats. Thus, to avoid this problem, water or wet food should be provided after administration of the drug, in order to reduce the time of contact of the drug with the esophageal mucosa (26).

4. CONCLUSION

From this report, it is evident the importance of researching hemoparasites in the feline clinical routine, as the confirmation of the agent through complementary exams is of paramount importance for the ideal treatment to be advocated. And for this, molecular tests are the most suitable for the diagnosis, as they have high sensitivity and specificity.

Comment [AKHTER49]: practice is crucial

Comment [AKHTER50]: causative agent

REFERENCES

1. Barker E, Tasker S. Haemoplasmas: Lessons learnt from cats. *New Zealand Veterinary Journal*. 2013;61(4):184-192.
2. Tasker S. Haemotropic mycoplasmas: what's their real significance in cats? *Journal of Feline Medicine and Surgery*. 2010;12(5):369-381.
3. Messick JB. Hemotropic mycoplasmas (hemoplasmas): a review and new insights into pathogenic potential. *Veterinary Clinical Pathology*. 2004;33(1):2-13.
4. Hicks CAE, Willi B, Riond B, Novacco M, Meli ML, Stokes CR, Helps CR, Hofmann-Lehmann R, Tasker S. Protective Immunity against Infection with *Mycoplasma haemofelis*. *Clinical and Vaccine Immunology*. 2015;22(2):108-18.
5. Thrall MA, Weiser G, Allison RW, Campbell TW. *Veterinary hematology and clinical chemistry*. 2nd ed. Ames: Wiley-Blackwell, 2012.
6. Harrus S, Klement E, Aroch I, Stein T, Bark H, Lavy E, Mazaki-Tovi M, Baneth G. Retrospective study of 46 cases of feline haemobartonellosis in Israel and their relationships with FeLv and FIV infections. *Veterinary Record*. 2002;151(3):82-85.
7. Jensen WA, Lappin MR, Kamkar S, Reagan WJ. Use of a polymerase chain reaction assay to detect and differentiate two strains of *Haemobartonella felis* in naturally infected cats. *American Journal of Veterinary Research*. 2001;62(4):604-608.
8. Roura X, Peters IR, Altet L, Tabar MD, Barker EN, Planellas M, Helps CR, Francino O, Shaw SE, Tasker S. Prevalence of hemotropic mycoplasmas in healthy and unhealthy cats and dogs in Spain. *Journal of Veterinary Diagnostic Investigation*. 2010;22(2):270-274.
9. Raimundo JM, Guimarães A, Rodrigues RB, Botelho CFM, Peixoto MP, Pires MS, Machado CH, Santos HA, Massard CL, André MR, Machado RZ, Baldani CD. Hematological changes associated with hemoplasma infection in cats in Rio de Janeiro, Brazil. *Revista Brasileira de Parasitologia Veterinária*. 2016;25(4):441-449.
10. Obara H, Fujihara M, Watanabe Y, Ono HK, Harasawa R. A feline hemoplasma *Candidatus Mycoplasma haemominutum*, detected in dog in Japan. *Journal of Veterinary Science*. 2011;73(6):841-843.
11. Martinez MS, Santos IFC, Kolber M, Del Poente MD. Análise hematológica em gatos domésticos (*Felis silvestris catus*) diagnosticados com micoplasmose em Osasco, São Paulo – Brasil. *Revista Lusófona de Ciência e Medicina Veterinária*. 2016;8:1-9.
12. Sykes JE. Feline hemotropic mycoplasmosis (feline hemobartonellosis). *Veterinary Clinics of North America: Small Animal Practice*. 2003;33(4):773-789.
13. Tasker S. Haemoplasmosis. In Michael, J. D. & Kohn, B. *BSAVA Manual of Canine and Feline Haematology and Transfusion Medicine*. 2ª edição. p. 67-72 Wiley Gloucester, 2012.
14. Tasker S, Binns SH, Day MJ, Gruffydd-Jones TL, Harbour DA, Helps CR, Jensen WA, Olver CS, Lappin MR. Use of a PCR assay to assess the prevalence and risk factors for *Mycoplasma haemofelis* and '*Candidatus Mycoplasma haemominutum*' in cats in the United Kingdom. *Veterinary Record*. 2003;152(7):193-198.

15. Pekel O, Duru SY. Determination of *Mycoplasma haemofelis* Incidence in Cats Visiting Veterinary Clinics in Kirikkale. *International Journal of Veterinary and Animal Research*. 2022;5(2):40-46.
16. Sykes JE. Feline hemotropic *Mycoplasmas*. *Journal of Veterinary Emergency and Critical Care*. 2010;20(1):62-69.
17. Aragão-de-sousa SKS, Sampaio-Junior FD, Sousa LO, Santos RC, Gonçalves EC, Scofield A, Góes-Cavalcante G. Diagnóstico molecular da infecção por hemoplasmas em gatos domésticos naturalmente infectados da cidade de Belém, Pará. *Pesquisa Veterinária Brasileira*. 2013;33(9):1116-1120.
18. Jenkins KS, Dittmer KE, Marshall JC, Tasker S. Prevalence and risk factor analysis of feline haemoplasma infection in New Zealand domestic cats using a real-time PCR assay. *Journal of Feline Medicine and Surgery*. 2013;15(12):1063-1069.
19. Kamyngkird K, Jiyipong T, Amavisit P, Stich, Jittapalpong, S. Molecular detection of *Mycoplasma haemofelis*, 'Candidatus *Mycoplasma haemominutum*' and 'Candidatus *Mycoplasma turicensis*' of stray cats residing in Bangkok monasteries, Thailand. *Agriculture and Natural Resources*. 2021;55(3):423-430.
20. Duarte A, Marques V, Correia JHD, Neto I, São Bráz B, Rodrigues C, Martins T, Rosado R, Ferreira JP, Santos-Reis M, Tavares L. Molecular detection of haemotropic *Mycoplasma* species in urban and rural cats from Portugal. *Journal of Feline Medicine and Surgery*. 2015;17(6):516-522.
21. Maciel AR, Biezus G, Cristo TG, Miletti LC, Maciel UC, Medeiros ALV, Xavier MGN, Casagrande RA. *Mycoplasma haemofelis* infection and its correlation with feline leukemia virus (FeLV) and feline immunodeficiency virus (FIV) in cats in Southern Brazil. *Comparative Immunology, Microbiology and Infectious Diseases*. 2023;93,101941.
22. Vergara RW, Galleguillos FM, Jaramillo MG, Almosny NRP, Martínez PA, Behne PG, Acosta-Jamett G, Muller A. Prevalence, risk factor analysis, and hematological findings of hemoplasma infection in domestic cats from Valdivia, Southern Chile. *Comparative Immunology, Microbiology and Infectious Diseases*. 2016;46:20-26.
23. Carli, E.; Trotta, M.; Chinelli, R.; Drigo, M.; Sinigoi, L.; Tosolini, P.; Furlanello, T.; Millotti, A.; Caldin, M.; Solano-Gallego, L. *Cytauxzoon* sp. infection in the first endemic focus described in domestic cats in Europe. *Veterinary Parasitology*. 2012;183(3-4):343-352.
24. Petry LS, Santos AP, Dornelles GL, Mello CBE, Silva AS, Dillmann JB, Lopes STA. Hemotropic *Mycoplasma* in domestic cats from the central region of Rio Grande do Sul state, Brazil. *Ciência Animal*. 2020;30(1):1-10.
25. Davoust B, Keundjian A, Rous V, Maurizi DP. Validation of chemoprevention of canine monocytic ehrlichiosis with doxycycline. *Veterinary Microbiology*. 2005;107(3-4):279-283.
26. German AJ, Cannon MJ, Dye C, Booth MJ, Pearson GR, Reav CA, Gruffydd-Jones TJ. Oesophageal strictures in cats associated with doxycycline therapy. *Journal of Feline Medicine and Surgery*. 2005;7(1):33-41.