

# Identification, cause and surgical management of traumatic fibroma in the buccal mucosa: a case report

---

## ABSTRACT

**Aims:** the objective of the present study is to report a clinical case aimed at the diagnosis and treatment of a traumatic fibroma located in the region of the unilateral buccal mucosa based on clinical and histopathological examination.

**Case Report:** A 43-year-old male patient, melanoderma, normosistemic, attended the Nilton Lins University dental clinic reporting the existence of a large nodule in the cheek region. Based on the clinical appearance of the lesion, the diagnostic hypothesis of traumatic fibroma was established, therefore, the surgical excision of the lesion was determined for subsequent referral to confirm the hypothesis. The removed content was transferred to a container containing a 10% formaldehyde solution and sent to the Department of Pathology and Legal Medicine of the Federal University of Amazonas for histopathological analysis. Given the characteristics presented in the analyzed histological picture, the definitive diagnosis was reactive fibroepithelial hyperplasia.

**Conclusion:** Performing a previous diagnosis of the lesion was therefore essential for planning the surgical procedure. The use of the conventional technique for the removal of reactive fibroepithelial hyperplasia obtained satisfactory results, both for postoperative recovery and for preventing recurrence, achieving the treatment objectives.

*Keywords: fibroma; oral surgery; hyperplasia; pathology, oral.*

## 1. INTRODUCTION

Fibrous hyperplasias are disorders characterized by appearing as benign proliferative tumors of exophytic tissue growth of non-infectious origin [1]. These lesions have a reactive character, and their development occurs through exposure to harmful habits or continuous chronic irritation [2]. Among the main examples, we can highlight: bite of the buccal mucosa, prosthetic maladjustments, diastemas, restorations or fractured teeth and traumas caused by orthodontic appliances.<sup>3</sup> In addition, psychological disorders such as stress, anxiety and irritability can also favor the development of the lesion [1,2].

In their characteristics, these lesions present a nodular aspect of variable sizes with coloration similar to the mucosa [4]. Regarding its base, it can be sessile or

pedunculated with a smooth or ulcerated surface [5]. Generally asymptomatic, it presents a firm, smooth consistency with slow gradual growth [6]. This growth may have consequences for speech, chewing and esthetics [1,3].

Because they are common injuries found in the oral region, they have patterns similar to other commonly found injuries [7]. Pyogenic granuloma, mucocele, ranula and papilloma are some pathologies similar in appearance to traumatic fibroma [8]. Histologically, it is identified in sections, highlighting the presence of stratified squamous epithelial tissue, consisting of abundant collagen fibers, in addition to variable blood vessels and inflammatory infiltrates [9]. The definitive diagnosis can only be obtained from a histopathological analysis [8,9].

Biopsy is the procedure responsible for collecting the pathological content, whether liquid or solid, as a complement to the clinical examination [10]. This technique is divided into: incisional, acting on the partial removal of the lesion, or excisional for the complete removal of the pathological content [7,10]. Thus, the treatment of choice will correspond to surgical removal of the lesion which may be complete in cases of favorable prognosis with a benign hypothesis, or partial when there is suspicion of malignancy, in addition to the removal of a possible aggressive agent causing the trauma [1,5].

That said, the objective of the present study is to report a clinical case aimed at the diagnosis and treatment of a traumatic fibroma located in the region of the unilateral buccal mucosa based on clinical and histopathological evaluations.

## **2. CASE REPORT**

A 43-year-old male patient, melanoderma, normosistemic, attended the Nilton Lins University dental clinic reporting the existence of a large nodule in the cheek region. After signing the consent form, care continued. During the anamnesis, he reported having a deleterious habit of biting the mucosa to relieve daily stress. He noted the existence of the lesion since he was young with gradual growth. He also reported being a smoker and denied having chronic diseases or drug allergies.

In the extraoral physical examination, palpation and inspection of the lymph node chain were carried out without any alteration. In the intraoral clinical examination, the following were observed: presence of third molars in the upper arch,

accumulation of calcified biofilm, crown staining, unsatisfactory amalgam restorations, root remnants and halitosis. In addition, a tonodular lesion measuring approximately 1.5 cm in diameter, pink in color, smooth surface, fibrous consistency and sessile base located unilaterally in the jugal mucosa where simple Fordyce granules were also found (Figures 1a and 1b).

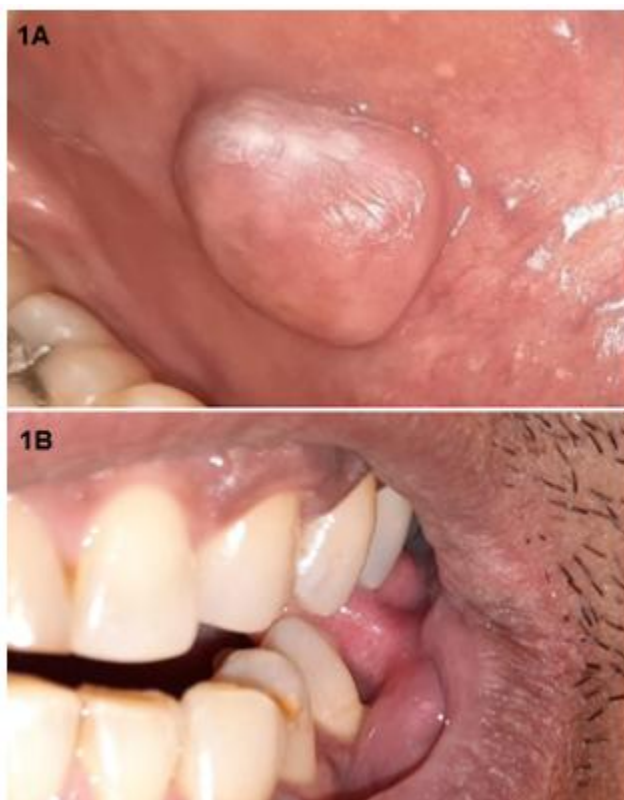

Figure 1: a) Intraoral appearance of the lesion; b) Simulation of deleterious oral habits.

Based on the clinical appearance of the lesion, the diagnostic hypothesis of traumatic fibroma was established, therefore, the surgical excision of the lesion was determined for subsequent referral to confirm the hypothesis. At first, the adaptation of the oral cavity was performed by means of supragingival scaling with Gracey curettes in the upper and lower arches, respectively. Subsequently, a sodium bicarbonate jet was applied to remove the dark spots on the dental surfaces. The patient was released with a scheduled return to perform the surgical procedure of excisional biopsy.

For the excisional biopsy, intraoral antiseptics were performed with 0.12% chlorhexidine digluconate through mouthwash for 1 minute, topically extraorally with 2% chlorhexidine digluconate with subsequent assembly of the operative field. The anesthetic 2% lidocaine salt associated with epinephrine at a concentration of 1:100,000 was administered infiltratively in the mental nerve with a peripheral complement close to the lesion, respecting the distance of 1 cm (Figure 2A). After the total desired anesthetic effect was achieved, the lesion was clamped and pulled with the aid of an Adson clamp (Figure 2B). Subsequently, using a #15c scalpel blade, an incision was made around the base of the hyperplastic tissue in order to remove the entire lesion (Figures 2C e 2D).

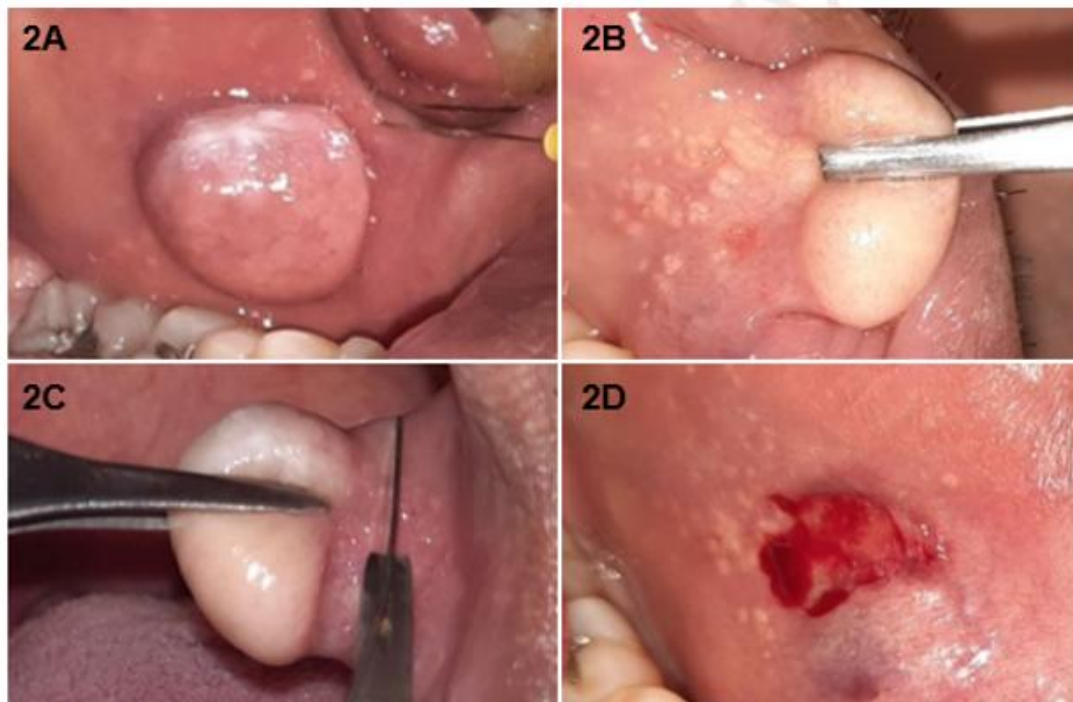


Figure 2: a) Administration of anesthesia; b) Clamping of the lesion; c) Removal of the traumatic fibroma; d) Aspect of the mucosa after removal.

Next, the affected region was abundantly irrigated with 0.9% saline and for the hemostasis, the surgical site was compressed using a sterile gauze pad with subsequent tissue synthesis with a 4-0 nylon suture (Figure 3A). The removed content was transferred to a container containing a 10% formaldehyde solution and

sent to the Department of Pathology and Legal Medicine of the Federal University of Amazonas for histopathological analysis (Figure 3B).

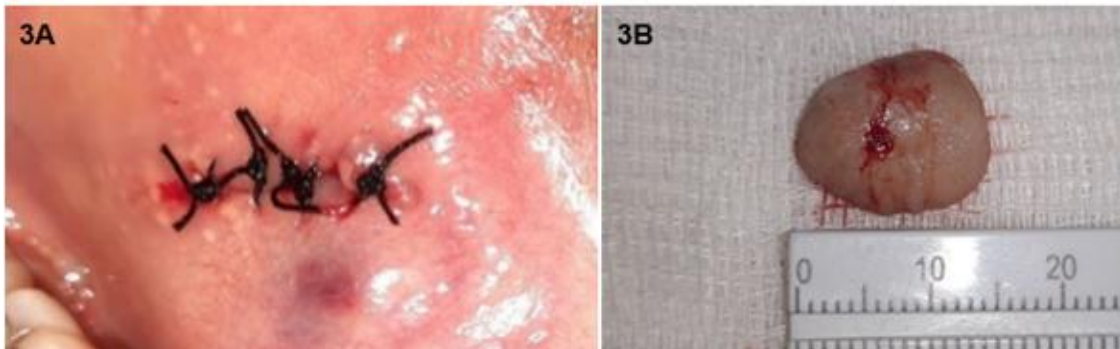


Figure 3: a) Tissue synthesis; b) Surgical piece.

For postoperative care, anti-inflammatory medication (nimesulide 100mg) was prescribed, 1 tablet every 12 hours for 3 days and analgesic medication (dipyron sodium 500mg), 1 tablet every 6 hours for 2 days. The patient was instructed regarding the possibility of relapse if he continued with any deleterious habits. After 7 days, he returned for suture removal, where no edema was observed in the region. In the final clinical aspect after 6 months, it was possible to highlight adequate healing of the affected mucosal tissue, showing effectiveness for the chosen resolution (Figure 4). The patient remains under follow-up.

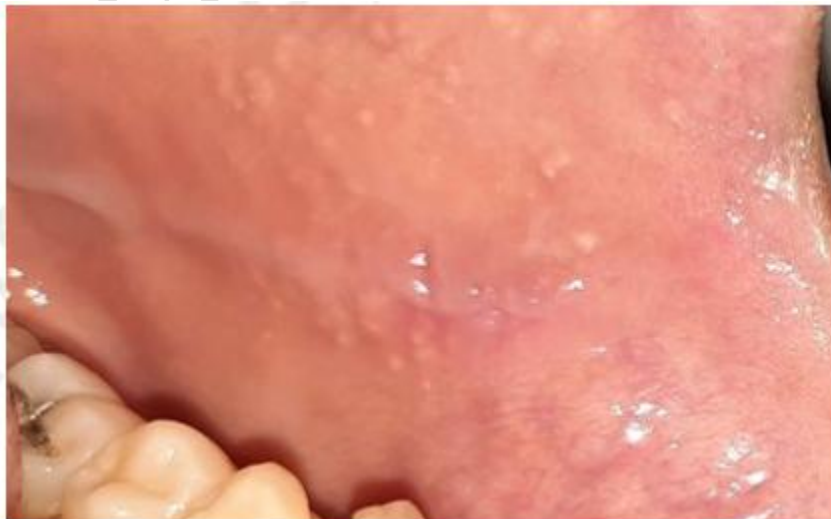

Figure 4: 6months postoperative period.

The histological sections revealed a lesion characterized by vascular neoformation, fibroblastic proliferation and intense deposition of dense, mature collagen fibers in a mild chronic inflammatory environment. At its extremes, the epithelium lining was thickened with several layers of cells with areas of acanthosis and a parakeratinized surface. Given the characteristics presented in the analyzed histological picture, the definitive diagnosis was reactive fibroepithelial hyperplasia (Figures 5 and 6).

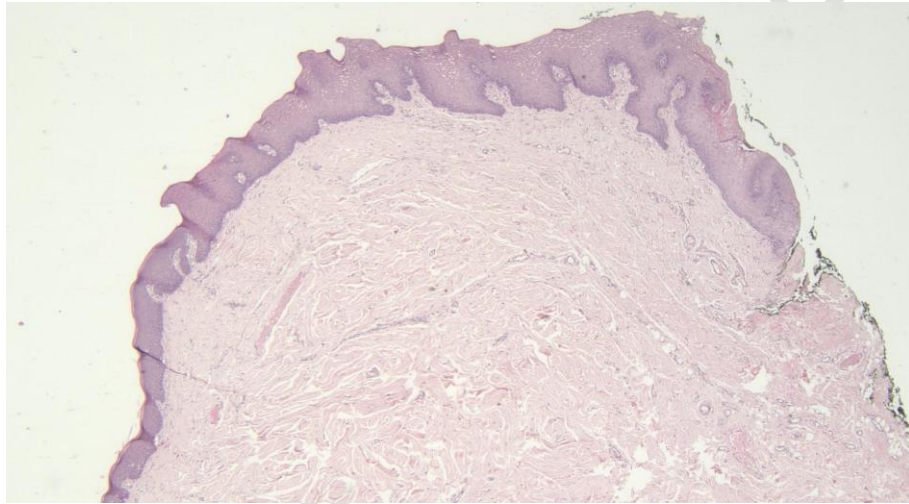


Figure 5: Hematoxylin and eosin-stained (20x) histological sections of jugal mucosa showing epithelial and connective tissue hyperplasia.

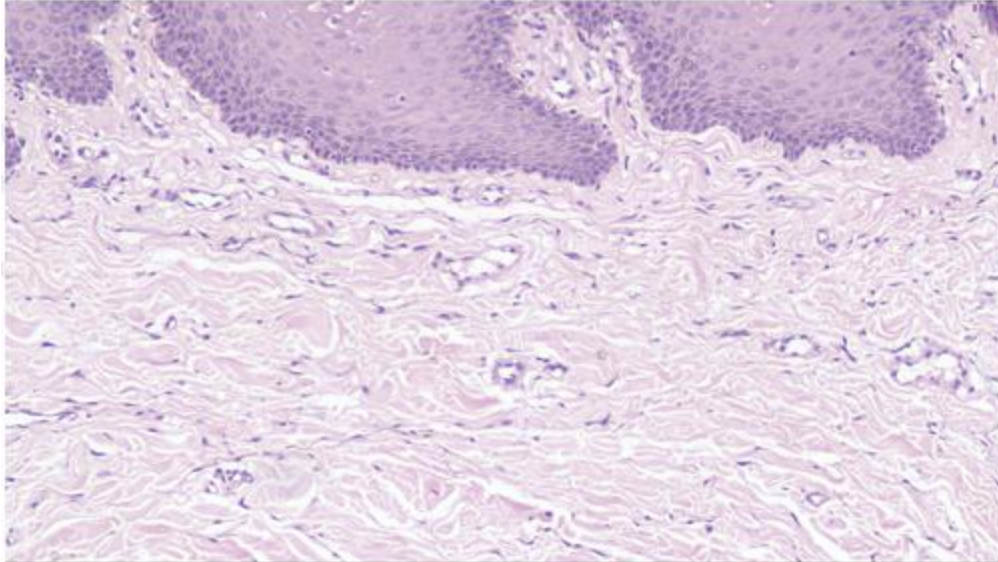


Figure 6: Epithelial and connective tissue hyperplasia. Showing (100x) dense deposition of mature collagen fibers.

### 3. DISCUSSION

Fibrous hyperplasias are nodular protuberances of non-neoplastic origin resulting from local trauma and irritation, usually found in the buccal mucosa and tongue, however, they can affect adjacent areas with unilateral formation [4]. These traumatic fibrous lesions are consistent with a sessile or pedunculated base, presenting with a smooth, painless, or in some cases, ulcerated surface with symptomatic swelling [3,6]. In clinical practice, when it comes to detecting oral hyperplastic reactions, these pathologies resulting from trauma continue to be one of the main benign reactive disorders with a common character [2].

Regarding the factors that lead to the development of traumatic fibroma, they include irritants such as: fractured teeth, diastema, calculus and residual roots leading to the process of tissue adaptation [11]. Correa et al., [5] believe that this damage can also be caused by foreign bodies, which include orthodontic appliances, prosthetic maladaptations or even continuous chewing habits in a certain area. In the reported case, compiling the characteristics of the literature, the patient stated that to relieve stress, he often bit the mucosa, generating the formation of the pathological condition which raised the hypothesis of possible anxiety and direct influence of psychological conditions on the onset of localized hyperplasia.

Reactive lesions have a notoriously predominant prevalence based on the greater involvement of females compared to males, in addition, it is worth mentioning that the main occurrence is between the 2nd and 6th decade of life [12,13]. According to Oliveira et al., [3], the lesion has a predilection for women of more advanced age and white, possibly due to the emotional variation factor, which in fact has already been identified in reported cases. In the aforementioned clinical case, the patient presented is contrary to much of the literature, belonging to the male gender, melanoderma, being a smoker in the 4th decade of life, which indicates the common occurrence in the patient due to habitual intrinsic factors.

Because it is a benign tissue tumor, it is necessary to carry out a careful evaluation through precise examinations for the correct diagnosis and, consequently, the most appropriate treatment [14]. This pathology may transform into a malignant tumor when diagnosed late. According to Souza [8], this is due to the abnormal response of the fibrous tissue. Thus, the differential diagnosis should include hemangioma, sarcoma and carcinoma, in addition to lesions of similar patterns such as mucocele, ranula and pyogenic granuloma [8,13]

Biopsy is the essential diagnostic method to guarantee the real result of the hypothesis raised preliminarily. It is with the result of the report that the true identification is contested [10,15]. In the aforementioned clinical case, after the patient's report during the anamnesis, combined with the clinical analysis, the initial hypothesis was traumatic fibroma, requiring a biopsy to confirm the diagnosis, which confirmed the hypothesis. The condition that defines its diagnosis lies in the analysis of the specimen of nodular lesion, revealing fibrous conjunctival origin in sections, the presence of parakeratinized and stratified squamous epithelium, in addition to dense bundles of collagen fibers, inflammatory infiltrates and variable blood vessels [11,13,16].

For cases involving this clinical picture, excisional biopsy followed by postoperative guidelines in order to remove the etiological factor are characterized as the main form of treatment, providing rare recurrences [5,9,17]. There are other forms of clinical resolutions. According to Bakhtiari et al., [18] the use of a diode laser for incisions has advantages when compared to the conventional technique, such as less bleeding, pain and infection, in addition to better coagulation and tissue healing. While Dutra et al., [7] already associates the technique of resection by strangulation for injuries of up to 5mm, using dental floss and incision at the base of the nodule, not producing bleeding, fast execution and dispensing with the need for suture. In the aforementioned case, the conventional removal technique with a 15c scalpel blade was used, not only because of its agility and reliability, but also because of its low cost compared to the other techniques described, disputing the possibility of recurrence with a favorable prognosis. Multiprofessional assistance for the treatment of the psychological part is essential to prevent the recurrence of the lesion, so it is necessary to refer the patient to the psychology team to approach the psychological and emotional factors involved.

#### **4. CONCLUSION**

Performing a previous diagnosis of the lesion was therefore essential for planning the surgical procedure. The use of the conventional technique for the removal of the reactive fibroepithelial hyperplasia obtained satisfactory results, both for the postoperative recovery and for the infeasibility of recurrence, thus providing satisfactory comfort to the patient.

#### **ETHICAL APPROVAL**

As per international standards or university standards, Participants' written consent has been collected and preserved by the author(s). This work was submitted to the Ethics and Research Committee on Human Beings, approved under opinion 5.632.283

#### **REFERENCES**

1. Carvalho CO, Santos FAOS, Miquelleto DEC. Traumatic fibroma: case report. Rev Gest Saúde. 2019;21(2):38-46.

2. Salaria SK, Kalra P, Belkhede SG, Vinnakota G. Successful management of recurrent irritational fibroma and associated residual soft tissue defect in the posterior teeth through single-stage surgery: A rare case report. *J Indian Soc Periodontol*. 2021;25(3):258-61.
3. Oliveira BM, Silva LM, Gargione AC, Bianchi CMPC, Deps TD, Crepaldi MV, et al. Hiperplasia fibrosa inflamatória. *Revista Faipe*. 2021;11(1):41-7.
4. Vidyanath S, Shameena PM, Johns DA, Shivashankar VY, Sudha S, Varma S. Reactive hyperplastic lesions of the oral cavity: A survey of 295 cases at a tertiary health institution in Kerala. *J Oral Maxillofac Pathol*. 2015;19(3):330-4.
5. Correa PE, Mendieta SA. Fibroma resection in oral mucosa. Strangulation technique. *CES Odontol*. 2016;29(1):82-7.
6. Mello-Moura ACV, Santos AMA, Bonini GAVC, Zardetto CG, Moura-Netto C, Wanderley MT. Giant cell fibroma in a two-year-old child. *Case Rep Dent*. 2016;2016:7058356.
7. Dutra KL, Longo L, Grandó LJ, Rivero ER. Incidence of reactive hyperplastic lesions in the oral cavity: a 10 year retrospective study in Santa Catarina, Brazil. *Braz J Otorhinolaryngol*. 2019;85(4):399-407.
8. **Souza FV. Epidemiology of lesions in the oral mucosa found in a Dental School Clinic. *Unimontes Scientific Magazine*. 2017;19(1):62–9.**
9. **Srivastava KC. Constellation of oral inflammatory hyperplastic lesions: case series with review of literature. *Int J Med Res Health Sci* 2019;8(4):101-6.**
10. **Brazao-Silva MT, Carvalho BO, Pinto RA. Biopsy in dental practice: Literature review. *RvAcBO*. 2018;7(3):197-203.**
11. **Mishra A, Pandey RK. Fibro-epithelial polyps in children: A report of two cases with a literature review. *Intractable Rare Dis Res*. 2016;5(2):129-32.**
12. **Martins JC, Essvein G, Vargas-Ferreira F, Silva AD, Neves M. Prevalence of oral lesions diagnosed at the ULBRA Canoas of Dental Diagnosis Service. *Stomatol*. 2017;23(44):24-32.**
13. **Rocafuerte LOVES. Traumatic fibroma in the oral cavity – a review. *KIRU*. 2019;16(1):41-6.**
14. **Katanec T, Bakula A, Filipović-Zore I, Kuna T. Symmetrical fibrous hyperplasia of the palate. *Acta Stomatol Croatian*. 2021;55(2):207-11.**
15. **Santos DPMA, Hiramatsu JM, Favretto CO, Silva JPP. Inflammatory fibrous hyperplasia in the oral mucosa: case report. *Arch Health Invest*. 2021;10(2):292-5.**
16. **Navas-Aparicio MC, Hernández-Rivera P. Focal fibrous hyperplasia: benign lesion of the oral mucosa. Literature review. *Rev Stomatol Herediana*. 2021;31(3):186-93.**
17. **Santos TVMS, Silva FB, Aguiar FM, Silva Júnior JP, Oliveira AT. Conventional prosthetic rehabilitation after surgical removal of fibrous hyperplasia: case report. *APCD Magazine*. 2021;(1):24-32.**

18. Bakhtiari S, JB Taheri, Sehatpour M, Asnaashari M, Moghadam SA. Removal of an Extra-large Irritation Fibroma with a combination of diode laser and scalpel. J Lasers Med Sci. 2015;6(4):182-4.

UNDER PEER REVIEW