

Intestinal Obstructionocclusion revealing metastatic gastrointestinal neuroendocrine tumor

ABSTRACT:

Neuroendocrine tumors (NETs) are rare tumors that are capable of secreting hormones into the bloodstream. They can affect any organ, but are most commonly found in the digestive system, particularly in the small intestine.

we present a case of a neuroendocrine tumor with intestinal obstruction revealed by an obstructive syndrome along with a literature review

Keywords: Neuroendocrine tumors, Obstructionocclusion, surgery

INTRODUCTION:

Neuroendocrine tumors (NETs) are rare tumors. Most often asymptomatic, these tumors are sometimes incidentally discovered during surgery, or even more rarely revealed by a clinical carcinoid syndrome. Herein, we present a case of a neuroendocrine tumor revealed by an obstructive syndrome along with a literature review

Case Presentation:

A 43-year-old patient was admitted to the emergency department for obstructive syndrome without vomiting, evolving in a context of general deterioration with a weight loss of 20 kg over 9 months and asthenia. Patient was conscious, oriented and hemodynamically stable. Clinical examination revealed a conscious patient, stable hemodynamically and respiratory. Abdominal examination showed diffuse tenderness on palpation without abdominal distension or palpable mass with exaggerated bowel sounds. The rest of the clinical examination was unremarkable, and the laboratory tests were normal. Abdominal CT scan revealed small bowel obstruction upstream due to of a non-complicated small bowel intussusception with circumferential and regular wall thickening suggestive of inflammation (Figure 1)

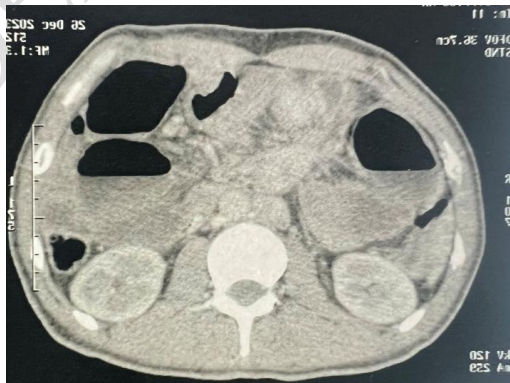

Fig 1: Emergency abdominal CT scan

Comment [GJ1]: Rewrite the abstract and make it into 200 words.

Comment [GJ2]: Please mention it as subacute intestinal obstruction.

Comment [GJ3]: In the image please show with arrow marks the site of intussusception and wall thickening

After consultation with a resuscitation specialist, the patient was transferred to the operating room for an open laparotomy. Exploration revealed a large mass involving the small intestine 5 centimeters from the ileocecal valve associated with upstream small bowel distension and presence of two suspicious hepatic nodules (Figure 2).

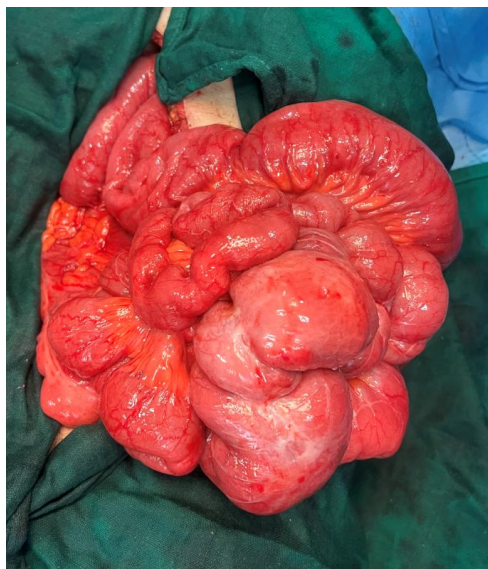

Fig 2: Intraoperative appearance

Comment [GJ4]: Please mark the obstructed bowel with arrow

The surgical procedure consisted of ileocecal resection (Figure 3) with side-to-side small bowel-colon anastomosis using a mechanical clamp, along with resection of a hepatic nodule. Postoperative recovery was uneventful.

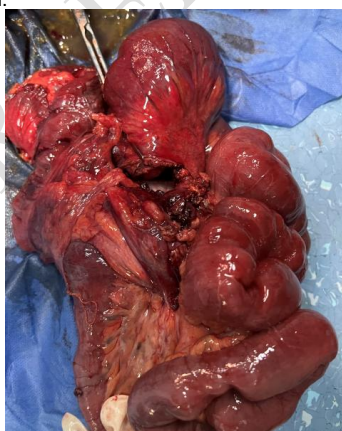


Fig 3: Surgical specimen

Histopathological results favored a multifocal grade 2 neuroendocrine tumor involving the small bowel wall and mesentery, with Ki67 at 5% and mitotic index at 4 infiltrating the intestinal wall up to the subserosa, stage pT3N1M1. The patient was referred to an oncology consultation for further management. A follow-up liver MRI showed liver metastases (segments I, III, IV, VII, VIII) (Figure 4).

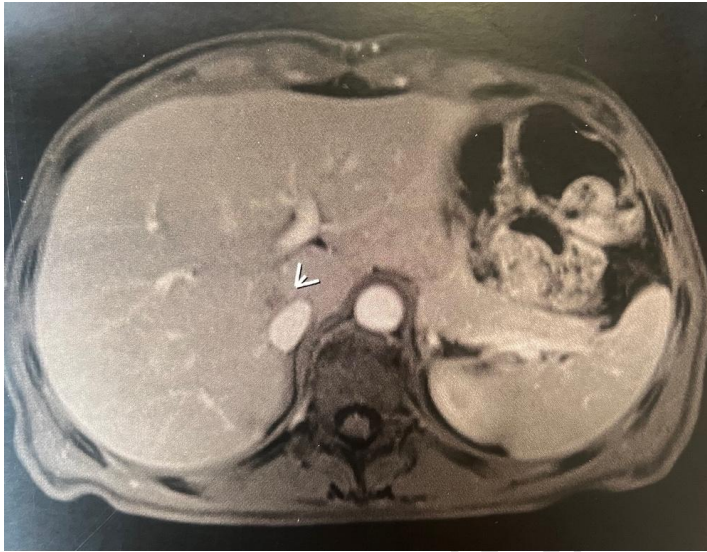


Fig 4: Post-operative MRI of the liver

DISCUSSION :

Digestive neuroendocrine tumors (NETs) are a group of rare tumors. Their incidence has been increasing over the last decades and is currently estimated at five cases per 100,000. The small bowel is the most common site of digestive neuroendocrine tumors, along with the appendix (30% of digestive neuroendocrine tumors). Symptoms vary depending on the secreted hormone, but there are also non-functional tumors (80% of NETs) without clinical symptoms related to hormonal secretion. At advanced stages, they are often multiple, locally advanced at the time of diagnosis, and can cause obstructive symptoms. They are sometimes associated with carcinoid syndrome, usually correlated with the presence of hepatic metastases.

Chromogranin A is the main biochemical marker of digestive NETs, increased in 85% of patients with digestive NETs. Urinary 5HIAA (5-hydroxyindoleacetic acid) levels over 24 hours for 1 to 2 days with appropriate diet can be useful to confirm the presence of carcinoid syndrome in patients with motor diarrhea.

Morphological diagnosis presents variable difficulties depending on the site of the primary tumor and the presence of hepatic metastases. The two useful radiological assessments in patients with symptomatic neuroendocrine tumors are enteroscopy and somatostatin receptor scintigraphy, sometimes supplemented with ileoscopy or small bowel MRI to detect small bowel tumors or [even capsule endoscopy](#). For staging, a thoraco-abdomino-pelvic CT scan with arterial and portal phases will be performed. However, MRI is more sensitive than CT for detecting hepatic metastases.

The treatment of localized small bowel NETs is based on surgical resection combined with mesenteric lymphadenectomy, removing at least 8 lymph nodes to identify N+ tumors.

In the presence of metastases, management of associated carcinoid syndrome should be carried out before any surgical procedure.

Curative surgery remains the "gold standard" in the management of small bowel NETs. It should be considered as soon as possible, even at a metastatic stage. Cholecystectomy should be systematically discussed in patients with high-risk small bowel NETs due to the subsequent risk of gallstone formation.

Comment [GJ5]: It is not routinely recommended. Please remove capsule endoscopy..

For well-differentiated metastatic tumors, the benefit of targeted therapies and metabolic radiotherapy is well established. In cases of surgical emergency for obstructive syndrome, a stoma is proposed while organizing elective [surgery](#).

CONCLUSION:

Neuroendocrine tumors of the small intestine are rare tumors with an increasing incidence. They present a dual challenge: early diagnosis and therapeutic management. [Surgery can treat NETs without complete resection](#) [Surgical resection even in patients with advanced or metastatic NET's helps](#) by reducing their size to alleviate symptoms and clear scarred or obstructed areas of the intestine.

REFERENCES:

- (1) Yao JC, Hassan M, Phan A, Dagohoy C, Leary C, Mares EJ et al. One hundred years after "carcinoid": epidemiology of and prognostic factors for neuroendocrine tumors in 35,825 cases in the United States. *Journal of Clinical Oncology*. 2008;26(18): 3063-3072.
- (2) Niederle MB, Niederle B. Diagnosis and treatment of gastroenteropancreatic neuroendocrine tumors: current data on a prospectively collected, retrospectively analyzed clinical multicenter investigation. *Oncologist*. 2011;16(5): 602-13.
- (3) De Mestier L, Lepage C, Baudin E, et al. Thésaurus National de Cancérologie Digestive (TNCD). Digestive Neuroendocrine Neoplasms (NEN): French Intergroup clinical practice guidelines for diagnosis, treatment and follow-up (SNFGE, GTE, RENATEN, TENPATH, FFCD, GERCOR, UNICANCER, SFCD, SFED, SFRO, SFR). *Dig Liver Dis* 2020; 52(5):473-492.
- (4) Motz BM, Lorimer PD, Boselli D et al. Optimal Lymphadenectomy in Small Bowel Neuroendocrine Tumors: Analysis of the NCDB. *J Gastrointest Surg*. 2017, 17.
- (5) Louis de Mestier, Come Lepage, Eric Baudin, Romain Coriat, Frédéric Courbon, Anne Couvelard et al. Digestive Neuroendocrine Neoplasms (NEN): French Intergroup clinical practice guidelines for diagnosis, treatment and follow-up (SNFGE, GTE, RENATEN, TENPATH, FFCD, GERCOR, UNICANCER, SFCD, SFED, SFRO, SFR). *Digestive and Liver Disease*. 2020;52(5): 473-492.

Comment [GJ6]: Discussion points to be added:

Intraoperative usage of octreotide in NETs to be added and discussed.

Please add a small paragraph on metastatic NET and also the role of SSA's in the management of this patients.

Apart from Somatostatin receptor scintigraphy, nowadays Gallium dotatate PET scan is preferred for staging and surveillance in well differentiated NETs.