

THERAPEUTIC AND OBSTETRICAL MANAGEMENT OF TWIN MUMMIFIED FETUSES IN SURTI DOE

Abstract

Fetal mummification is uncommon in small ruminants like goat and sheep. The twin mummification of fetuses confirmed by history, a clinical sign, ultrasonographical and per-vaginal examination in a five years old Surti doe of fourth parity. The case was successfully managed therapeutically using intravenous administration of 3.0 ml Dexamethasone[®], 20IU-Oxytocin[®], 500ml-Normal saline and 30ml-Calcium magnesium borogluconate, whereas 5ml-Valethamate bromide (Epidosin[®]) was given intramuscularly. The goat resumed to normal appetite and appearing active and alert within a week post treatment.

Keywords: Surti doe, Uterine inertia, Ultrasonography, Twin Mummified fetuses.

Introduction

Goat being one of the highly fertile animals among the domesticated animal provides meat, milk, fibers and leather. Being a small size ruminant, management and rearing are usually done easily by poor farmers and household women. Fetal mummification in most animals is characterized by death of conceptus followed by resorption of fetal fluids, persistence of corpus luteum, involution of uterus to an extent that it contracts tightly over the fetus and resembles to a contracted hard mass (Noakes *et al.*, 2009). It is also characterized by death of the fetus and fetus being retained in uterus owing to the failure of normal parturition or abortion mechanisms (Arthur *et al.*, 1989). The incidence of foetal mummification is commonly observed in domestic animals occurring in the middle last third of gestation but it is uncommon in sheep and goat (Roberts, 1971). The death of fetus is encountered generally due to several factors of genetic abnormalities involving autosomes or sex chromosomes, torsion, compression of the umbilical cord, placental defects, overcrowding of fetuses and infections during the second or third trimester of gestation after the formation of the placenta and substantial ossification of fetal bony remnance (Roberts, 1971). Braun *et al.* (2007) reported that energy and protein deficiencies, particularly on day 90 to 120 of gestation also cause fetal mummification. The present case report describes the successful delivered of twin dead mummified fetuses in a Surti doe by the successful therapeutic and obstetrical management.

Case History and Clinical observation

A five year old Surti doe in its 4th parity was presented with the history of incomplete gestation period, straining, restlessness and tenesmus since last two days. The vital physiological parameters were recorded: temperature-103.8^oF, respiration rate-19/minute and heart rate-80/minute (slightly elevated-tachycardia). The goat was anorectic, dull, depressed, slightly dehydrated in standing position (Fig-1).

Comment [A1]: Such as

Comment [A2]: Twin

Comment [A3]: Five-years-old

Comment [A4]: Highly fertile

Comment [A5]: animals goat

Comment [A6]: Their small size makes them easy to manage and rear, especially

Comment [A7]: fetal

Comment [A8]: This case report details

Comment [A9]: through a

Comment [A10]: fourth

Comment [A11]: a history

Comment [A12]: for the past




Fig 1: Dull, depressed and Standing condition in Doe

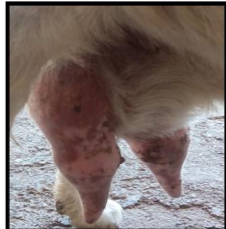

Fig 2: Mammary glands fully engorged with milk



Fig 3: Reddish chocolate coloured discharged was observed

Clinical examination revealed pinkish conjunctival and vaginal mucous membranes, engorged mammary gland (Fig-2), tinged vulval lips with abnormal pinkish to reddish coloured discharge (Fig-3). Abdominal ballottement revealed that hard freely movable mass suggesting the presence of fetus, which was further, confirmed by real time B mode transabdominal ultrasonography (Sonosite, Titan Ltd. Hitchin, United Kingdom). Two hyperechoic striations of thoracic cage without cardiac motility and lack of fetal fluid indicated the presence of mummified fetuses (Fig-4). The pervaginal examination with proper lubrication revealed empty birth canal with only one finger dilated cervix. Based on the history, a clinical signs, ultrasonographical and pervaginal examination the case was diagnosed as a dystocia due to incomplete cervical dilatation with twin mummified fetuses.

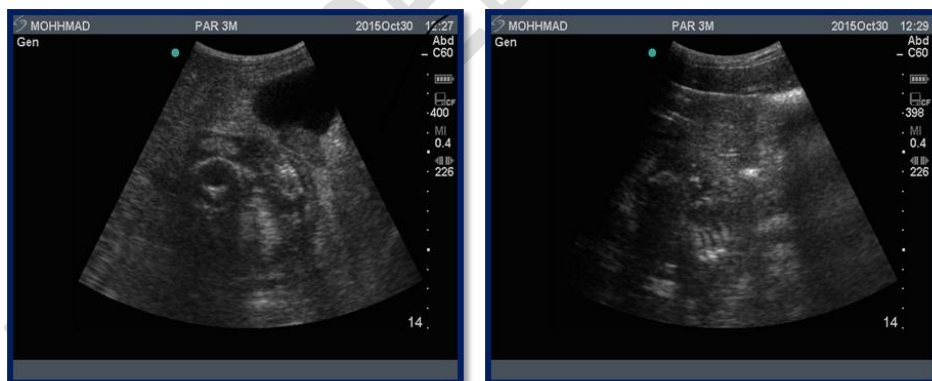

Fig- 4: Hyper-echoic striations of thoracic cage without cardiac motility and lack of fetal fluid in mummified fetuses

Therapeutic and Obstetrical Management

Following confirmatory diagnosis of twin fetal mummification, the goat was medicated with intravenous administration of 3.0 ml Dexamethasone[®], 20IU-Oxytocin[®], 30ml-calcium

Comment [A13]: confirmation

borogluconate and 500ml Normal saline, whereas 5ml valethamate bromide (Epidosin[®]) was given intramuscularly. After 7-8 hrs of medicinal treatment goat started straining and placental membrane was hanging out through vaginal region was observed (Fig-5). Per-vaginal examination revealed complete cervical dilation with sufficient available space for handling of fetus. The mummified fetuses (male in posterior presentation and female in anterior presentation) were delivered per-vaginally by grasping tiny limbs along with mild extraction (Fig-6).

Then the goat was medicated with intramuscularly administration of 3ml-Chlorpheniramine maleate[®] (Antihistamines), 5ml-Vitamin B-complex Injection, Melonex[®] (Meloxicam-Intas, India) @ 0.5mg/kg. b.wt. IM OD and Quintas[®] (Enrofloxacin-Intas, India) @ 5mg/kg. B.wt. IM OD; whereas 500ml Dextrose normal saline was given intravenously with placement of two Furea bolus (control the uterine infection- Allopathic remedies, India) in the uterus. The Liquid Exapar[®] (Indigenous herbal uterine cleanser and restorative-Natural Remedies, India) @ 20 ml twice PO and liquid Gluca-boost (To maintain the energy/glucose-Natural Remedies, India) @ 30ml twice PO. Intramuscularly antibiotic, analgesic and antihistamine treatment was continued for 5 days.

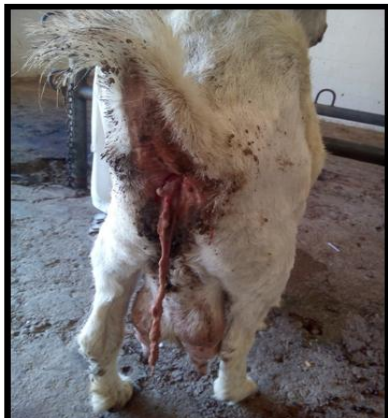

Fig-5: Feto-placental membrane was hanging out



Fig-6: Manually delivered dead mummified fetuses with mild extraction

Results and Discussion

Information of the patient was taken telephonically every alternate day following discharge from hospital. The goat was found active and alert resuming normal appetite within a week post treatment. Eventually, the doe recovered uneventfully. Tutt (1991) reported that the foetal mummification is rare in goat but appears to be more common in twin pregnancy which was in agreement with present case observation. Characteristics of the delivered mummified fetuses in form of the weight of the mummified fetus along with placenta; mummified fetus

Comment [A14]: Valethamate

Comment [A15]: administered

Comment [A16]: at a dose of 5ml, im.

Comment [A17]: Observed hanging

Comment [A18]: Delete the phrase

Comment [A19]: space

Comment [A20]: traction

Comment [A21]: OD. Additionally

Comment [A22]: Comments: The treatment given doesn't seem to be given rationally as all the possible drugs have been given without stressing upon one line of treatment. The treatment schedule seems to be haphazardly given and not on scientific lines. Some specific therapy with good parenteral antibiotic plus single ecboic would have been a better option.

Comment [A23]: For writing a case report in a scientific Journal the follow up should have been monitored personally rather on phone calls.

alone were (205.2 ; 129.0 grams): (100.1; 65.0 grams); the number of rows of fetal cotyledons on placenta were 9:4; total length of placenta were (125.0 cm: 65.0 cm); also the measurements of fetuses such as crown-rump length (CRL); heart girth (HG); head crest; neck length; fore limb length; hind limb length and Umbilical cord length were recorded to (18.6; 13.4; 3.4; 4.5; 14.4; 15.6 and 17.5 cm) : (10.27; 7.38; 1.88; 2.38; 8.06; 8.61 and 9.0 cm) of first large male and second small female mummified fetuses (Fig-7) respectively. Amer (2008), Chauhan *et al.* (2014) and Bisla *et al.* (2018) have also reported the fetal death at almost similar stage of gestation as observed in the present case. Markandey *et al.* (1991), Doijode (1993) and Nakhashi *et al.*, (2005) have also reported cases of mummification in goats. Ogbu *et al.* (2011) reported a case of dystocia due to mummification where both the foetuses were dead corroborated with present report.

Comment [A24]: Placenta was

In present case study, the both of male and female fetuses were observed with lack eye ball and ear probably due to resorption of skin, subcutaneous layers and were also layered with chocolate gummy tenacious exudates which resembled to typical body configuration of hematinic type of mummification as reported by Roberts (1971). Although spontaneous abortion of a mummified foetus can occur, expulsion of the foetus usually requires veterinarian intervention. The main reason for non expulsion of mummified fetus in the present case was due to incomplete cervical dilatation. Gouru *et al.* (2017) and Singh *et al.* (2018) have also use and suggested that the beneficial effect of Epidosin® (valethamate bromide) in incomplete cervical dilatation of fetal mummification in goats. So, the doe was treated with Valethamate bromide, Dexamethasone, Oxytocin, calcium borogluconate and other supportive therapy for relive dystocia from cervical dilation and uterine inertia.

Comment [A25]: The present study has revealed no new thing as per the given references. The case report on one case has nothing new and innovative in it.

Comment [A26]: Incomplete cervical dilatation and fetal mummification need some supporting reference

Comment [A27]: Treatment given seems to be only symptomatic rather based on principles.

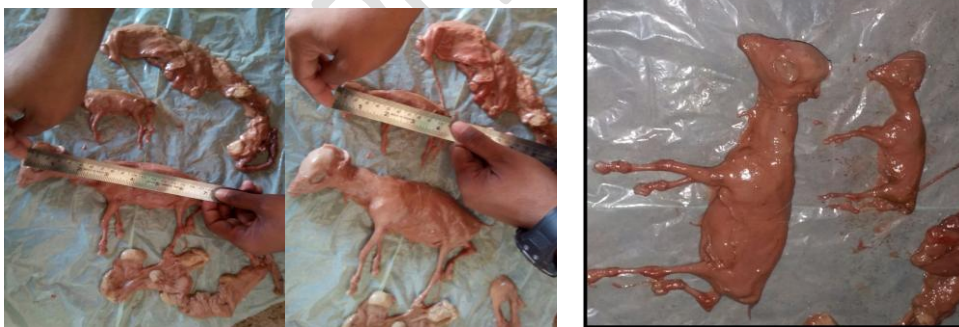

Fig-7: Hematinic mummified large male and small female fetuses layered with chocolate gummy tenacious exudates with placenta.

CONCLUSION

In present case sound diagnosis and timely interventions lead to successful delivery of mummified fetuses as well as save life of the doe without any complications. Thus, the present case reports successful management of twin fetal mummification in a Surti doe without any complications.

REFERENCES

- Amer, H. A. (2008). Determination of first pregnancy and measurements in Egyptian Baladi goats (*Capra hircus*). *Veterinaria Italiana*, **44**(2): 429-437.
- Arthur, G. H.; Noakes, D. E. and Pearson, H. (1989). *Veterinary Reproduction and Obstetrics*. 6th edn. London, Bailliere Tindall. 114. Aziz and Taha, 1996.
- Bisla, A.; Kumar, B.; Kurhe, R.; Behera, H.; Ngou, A. A.; Shah, I. and Khan, J. A. (2018). Dystocia due to fetal mummification in a non-descript goat. *Journal of Experimental Biology and Agricultural Sciences*, **6**(3):613 -616.
- Braun, WF. Jr. (2007). Noninfectious prenatal pregnancy loss in the doe. In: Youngquist RS, Threlfall WR, editors. *Current Therapy in Large Animal Theriogenology*. 2nd ed. Philadelphia: WB Saunders: 555-561.
- Chauhan, P. M.; Kapadiya, P. S.; Sutaria, T. V, Nakhshi, H. C. and Sharma, V. K. (2014). Retention of Mummified Fetus due to Uterine Inertia after Kidding in Doe. *Veterinary Clinical Science*, **2**(4):64-66
- Doijode, S. V. (1993). A rare case of foetal mummification in goat. *Indian Journal of Animal Reproduction*, **14**: 60.
- Gouru, R.; Pottabathula, M. and Reddy, N. V. K. (2017). Dystocia due to fetal mummification in a non-descript doe. *The Pharma Innovation Journal*, **6**(8): 163-164.
- Markandey, N. M.; Pargonkar, D. R.; Baksi, S. A. and Doijode, S. V. (1991). Fetal mummification in goat-a case report. *Indian Journal of Animal Reproduction*, **12**:107-108.
- Nakhshi, H. C.; Chaudhary, S. R. and Faruquie, S. (2005). Premature kidding along with a retained mummified fetus in a twin pregnancy- A Case Report. *Indian Journal of Field Veterinarian*, **2**: 62-63.
- Noakes, D. E.; Parkinson, T. J. and England, G. C.W. (2009). *Arthurs' Veterinary reproduction and obstetrics, 9th edition, Saunders, Edinburg, London*.
- Roberts, S.J. (1971). *Veterinary Obstetrics and Genital Diseases*, 2nd edn. CBS Publishers and Distributors, New Delhi, 170-174.
- Singh, L. K.; Pipelu, W.; Mishra, G. K. and Patra, M. K. (2018). Fetal mummification in a non-descript doe and its successful management. *International Journal of Science, Environment and Technology*, **7**(1):254 -257.
- Tutt, C. L. C. (1991). Post-partum mummification of a co-twin fetus in a Cameroon Dwarf doe. *Journal of Veterinary Record*, **40**: 229-231.