

Case study

“Folliculitis Decalvans and Lichen Planopilaris” Phenotypic Spectrum: Report of Three cases

ABSTRACT:

Introduction: folliculitis decalvans (FD) and lichen planopilaris (LPP) are two primary cicatricial alopecias (neutrophilic and "lymphocytic," respectively) recently associated in a phenotypic spectrum. The "folliculitis decalvans and lichen planopilaris" phenotypic spectrum FDLPPPS is a combination of the clinical and histological features of FD and LPP. Our study aims to analyze three cases of a specific disease to better understand its clinical characteristics, evolution, and treatment.

Materials & Methods: We reported 3 cases of FDLPPPS with clinical manifestations, trichoscopy, histopathological features, treatments, and follow-up findings as a new presentation of this spectrum.

Results: We reported 3 cases; two females, and one male, with an average age of 33 years (ranging from 20 to 42 years). The average duration of disease evolution before diagnosis was 6.3 years (ranging from 1 to 10 years). Clinically, they presented with one or multiple alopecic patches on the vertex with pustules and crusts and a receding frontal hairline in one patient. Dermoscopy revealed signs consistent with lichen planopilaris and folliculitis decalvans. A diagnosis of phenotypic spectrum was established through histology. Patients received treatments including corticosteroids, antibiotics, hydroxychloroquine, or isotretinoin, with good improvement noted in one patient, moderate improvement in another, and stabilization in the third.

Conclusion: This phenotypic spectrum is a newly recognized entity that combines clinical and histological signs of FD and LPP. Early treatment is crucial to halt disease progression. The emergence of new variants within FDLPPPS, such as FD-frontal fibrosing alopecia, underlines the need for further case series to better characterize this spectrum.

KEYWORDS: Phenotypic spectrum, lichen planopilaris, folliculitis decalvans, trichoscopy, frontal fibrosing alopecia, alopecia

INTRODUCTION:

Folliculitis decalvans (FD) and lichen planopilaris (LPP) are two primary cicatricial alopecias ("neutrophilic" and "lymphocytic" respectively) (1), recently associated in a phenotypic spectrum in which they occur simultaneously or in a bi-phasic presentation, in the same or in different areas of the scalp (2). The "Folliculitis decalvans and lichen planopilaris" phenotypic spectrum FDLPPPS is a combination of the clinical and histological features of FD and LPP.

We report 3 cases of FDLPPPS as a new presentation of this spectrum.

MATERIALS & METHODS:

We reported 3 cases of FDLPPPS with clinical manifestations, trichoscopy, histopathological features, treatments, and follow-up findings.

Case presentation

Case 1 [8]: A 42-year-old woman presented with a 10-year history of vertex scarring patches of alopecia. For one year, she presented pruritus in the frontal hairline. The physical examination found a phototype V patient with two vertex keloid patches of alopecia measuring 6 cm and 4 cm in diameter, respectively, with a negative pull test, trichoscopy found tufts, follicular pustules, hemorrhagic crusts, milky-red areas, and dilated vessels on trichoscopy (Figure 1, A and C). There was an associated 2.5 cm linear frontal hairline recession with trichoscopy showing peripilar hyperkeratosis and erythema, tubular hair casts, and yellow dots (Figure 1, B, and D). Additional eyebrow loss covered by micro-pigmentation, facial papules, and facial hyperpigmentation were noticed.

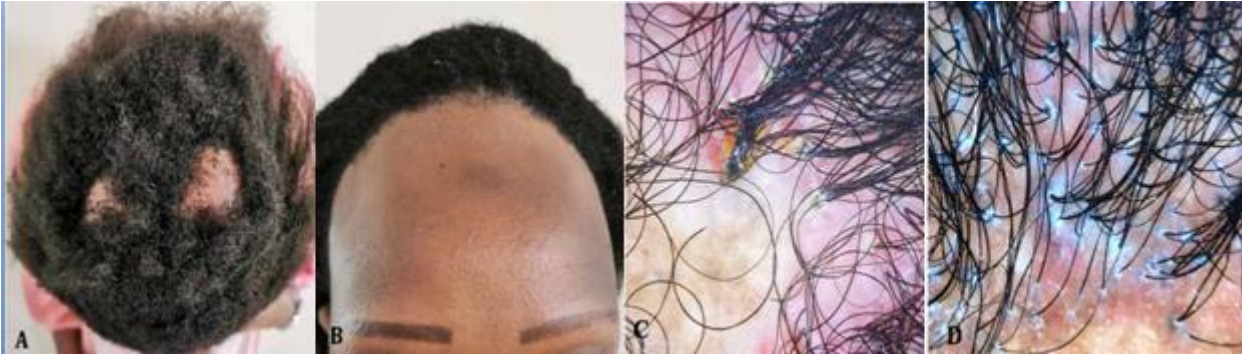

Fig 1: 2 vertex cheloid patches of alopecia(A) with trichoscopy(C) linear frontal hairline recession(B) with trichoscopy(D)

Histopathology view of vertex scalp biopsy showing a dense peripilar neutrophilic infiltrate, infundibular pustule, and plasma cell exocytosis and dermal fibrosis. (Fig 2 A, B)

Histopathology aspect of frontal hairline scalp biopsy showing perifollicular hyperkeratosis associated with a moderate dermic lymphocytic infiltrate and fibrosis. (Fig 2 C, D)

A diagnosis of FD associated with frontal fibrosing alopecia (FFA) and lichen pigmentosus was confirmed by histopathology.

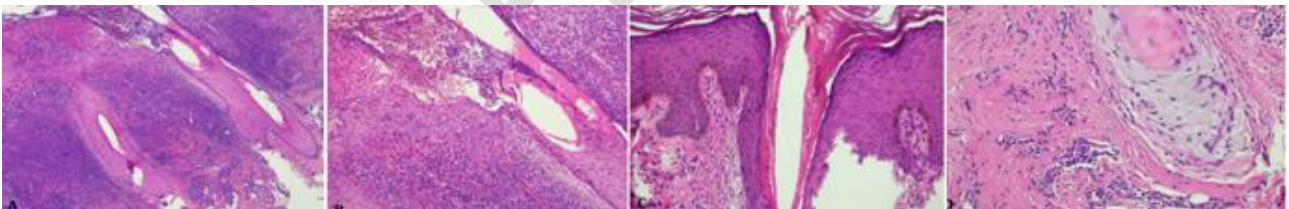


Figure 2. Histopathology view (A, C) low magnification, (B, D) high magnification) of vertex scalp biopsy (A, B) showing features consistent with folliculitis decalvans . and of frontal hairline scalp biopsy (C, D): showing features consistent with frontal fibrosing alopecia

A metabolic analysis as well as investigation of associated pathologies with lichen were mad and were without abnormality.

No bacterial sample was taken from vertex patches of alopecia.

the patient was treated with oral low-dose isotretinoin (0.2 mg/kg per day), intralesional injections of corticosteroids every 6 weeks for FFA and FD, topical fusidic acid twice a week for FD, and tacrolimus 0.1% for eyebrow.

Within one year of treatment, FFA stabilization was achieved, and then some pustules appeared, which needed the adjunction of oral azithromycin (500 mg per day, 3 days per week for 3 weeks) for remission [8].

Case 2: A 37-year-old female patient presented with intermittent pustules and scales on her scalp for 3 years, preceding an extensive hair loss. Following systemic antibiotic therapy, she made a **gradual improvement with new hair growth**.

However, 1 year ago Lesions of cicatricial alopecia appeared on the scalp with follicular papules, pustules, hemorrhagic crusts, perifollicular erythema, and scale build-up.

She was diagnosed with folliculitis decalvans and received different courses of topical/oral antibiotics along with corticosteroids

Nevertheless, her symptoms continued to progress slowly

Dermatological examination showed a wide patch of cicatricial alopecia on the scalp, measuring 15 x20 cm; pull test hair was negative. Trichoscopy revealed loss of partial follicular opening, follicles surrounded by milky red areas, dilated blood vessels, pustules, and follicular tufts. Fig 3

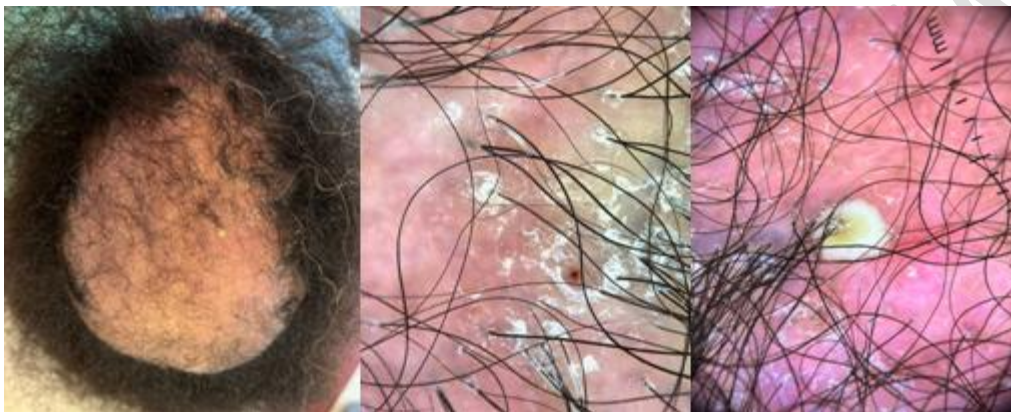

Fig 3: patch of cicatricial alopecia on the scalp with trichoscopy images

Otherwise, grouped, skin-colored, keratotic follicular papules were found on her neck and chest without any other lesions on the face, extremities, mouth, or nails,

Scalp biopsies from the center and the edge of the alopecia patch, with horizontal and vertical sections, showed different findings:

Histopathological examination of the edge showed hyperkeratosis, mild epidermal hyperplasia, and a neutrophilic infiltration along the follicle (fig 4 A, B)

Histopathological examination of the **center** showed epithelial basal layer destruction in the hair follicle, dense lymphocytic infiltration, and partial destruction of hair follicles surrounding it (Fig 4 C,D).

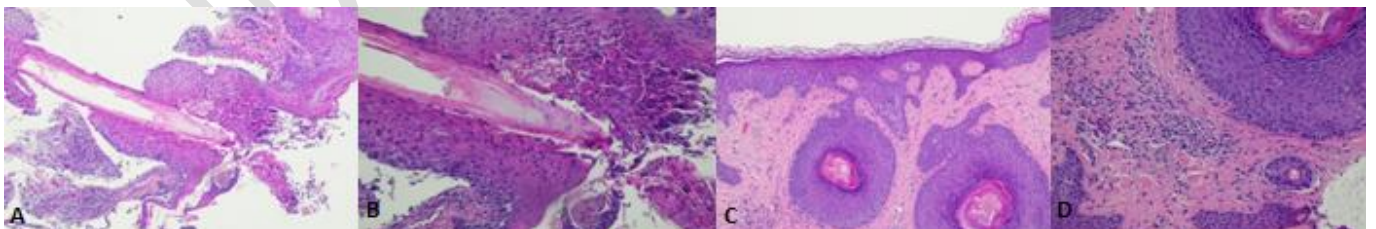


Figure 4. Histopathology view (A, C) low magnification, (B, D) high magnification) of scalp biopsy at the edge (A, B) showing features consistent with folliculitis decalvans. and of scalp biopsy at the center (C, D): showing features consistent with lichen planopilaris

These clinical, trichoscopic, and histopathological findings were consistent with the diagnosis of FDLPPPS.

A metabolic analysis as well as investigation of associated pathologies with lichen were mad and were without **abnormality**.

The patient was treated with oral doxycycline 100 mg/day, hydroxychloroquine 400 mg/day topical fusidic acid, and Propionate of clobetasol 0.05% twice/week

Case 3: A 20-year-old male was treated for 8 years for pilar lichen with corticosteroids, he presented with scarring patches of alopecia, pustules, and crusts on her scalp, and the hair pull test was negative. Trichoscopy showed hyperkeratosis and erythema, tubular hair casts, milky red areas, and tufts (fig5).

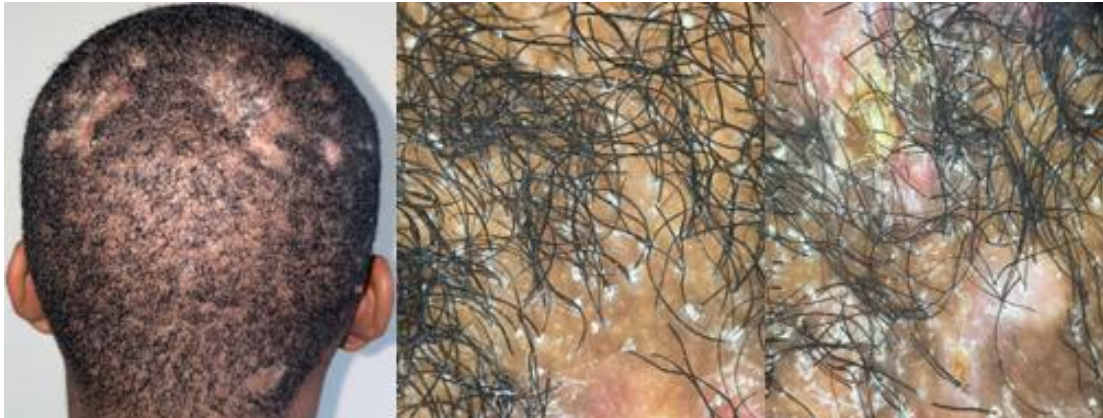

Fig 5: scarring patches of alopecia on the scalp with trichoscopy images

A diagnosis of FD LPPPS was confirmed by histopathology

A metabolic analysis as well as investigation of associated pathologies with lichen were mad and were without abnormality the patient was treated with Diprostene IM injection 1injection /month, Doxycycline 100mg/day and topical Fusidic acid, with hair growth after 8 months.

Table 1: Summary of the various clinical, trichoscopic, therapeutic, and evolutionary characteristics of 3 patients.

	Case 1	Case 2	Case 3
Gender/Age	42-year- old woman	37-year-old woman	20-year-old man
Physical examination	two vertex keloid patches of alopecia linear frontal hairline recession and eyebrow depilation	Alopecic plaque of vertex with pustules, hemorrhagic crusts, and scales.	Several alopecic plaques on the vertex with crusts and pustules
Trichoscopy	Vertex: tufts, follicular pustules, hemorrhagic crusts, milky-red areas, and dilated vessels - Linear frontal hairline: peripilar hyperkeratosis and erythema, tubular hair casts, and yellow dots	peripilar hyperkeratosis and erythema, tubular hair casts tufts, follicular pustules, hemorrhagic crusts, milky-red areas, and dilated vessels	peripilar hyperkeratosis tubular hair casts milky-red areas, crusts, and tufts
Histology	FD + Frontal Fibrosing Alopecia (FFA)	FD+LPP	FD+LPP
Metabolic analysis	No anomalies	No anomalies	No anomalies

Treatment	Isotretinoin Intralesional corticosteroid injection Tacrolimus 0.1% Fusidic acid the day before showering	Hydroxychloroquine Doxycycline Propionate of clobetasol 0.05% Fusidic acid the day before showering	Diprostene IM injection 1injection /month Doxycycline Fusidic acid the day before showering
Evolution	Stable for 1 year	Evolutionary	Growth in 8 months

DISCUSSION

FD and LPP were classified into two distinct categories: "neutrophilic" primary scarring alopecia and "lymphocytic," respectively (1). Morais et al (3) reported on "13 cases of lichen planopilaris with pustules, crusts, follicular tufts, and histopathological findings of lymphocytic infiltration. They suggested the difficulty in differentiating lichen planopilaris and folliculitis decalvans and the need for further study to elucidate whether lichen planopilaris with pustules constitutes a new subtype of LPP or even a different disease".

Yip et al. (2) reported "13 other cases in which the lesions developed biphasic clinical and histologic features of folliculitis decalvans and lichen planopilaris. Folliculitis decalvans presentations generally preceded those of lichen planopilaris". "They were the first to introduce the term folliculitis decalvans lichen planopilaris phenotypic spectrum. Then, 7 additional cases" were reported by Egger et al. (4). Ramos et al. **have** previously reported on two cases of FDLPPS diagnosed in pediatric patients (5).

"Only 39 cases of this spectrum, including only 3 cases of FFA+, were reported in the literature between 2018 and 2023. Hypothesize about the likely pathogenic mechanisms that underlie this spectrum of phenotypic and henotypic appearances, in particular, abnormal hair follicle inflammatory responses and collapse of hair follicle immune privilege in response to microbiome dysbiosis" (2).

"FDLPPS is a combination of the clinical and histological features of FD and LPP" (9-12).

"Tufting, pustules, and yellow crusts are clinically characteristic of FD, whereas perifollicular cast and erythema suggest LPP" (3,4,5).

Trichoscopy can reveal notable inflammation, hyperkeratosis, and lack of follicular ostia in both LPP and FD. According to Kang et al. [6], "LPP displays peripilar white/silver scales, peripilar erythema, casts, concentric blood vessels, and violaceous coloration of interfollicular epidermis". "On the other hand, FD is characterized by peripilar white yellowish scales, peripilar hyperplasia, white and milky-red areas, and numerous hair tufts. In terms of histopathology, the identification of multicomponent follicular structures, atrophy of the follicular epithelium, and prominent plasma cell component instead of predominance of neutrophils should be considered for the diagnosis of FDLPPS" (3).

"Early diagnosis is essential for appropriate management based on anti-inflammatory agents combined with antibiotics. However, there is no consensus **on** FDLPPS treatment, and the therapy duration remains to be established. Oral doxycycline or association of rifampicin/**clindamycin** in combination with oral or intralesional steroids is commonly used as **first-line** treatment. Hydroxychloroquine, cyclosporine, retinoids, and dapsone were all reported as possible treatments" (2-5).

Long-term **follow-up** is also needed to manage the frequent disease flares occurring after treatment completion.

CONCLUSION:

FDLPPS is a combination of the clinical and histological features of FD and LPP.

The emergence of new variants within FDLPPS, such as FD-FFA, underlines the need for further case series to better characterize this spectrum.

Ethical Approval:

As per international standards or university standards written ethical approval has been collected and preserved by the author(s).

Consent

As per international standards or university standards, patient(s) written consent has been collected and preserved by the author(s).

REFERENCES:

- 1- Olsen EA, Bergfeld WF, Cotsarelis G, et al. Summary of North American Hair Research Society (NAHRS)-sponsored Workshop on Cicatricial Alopecia, Duke University Medical Center, February 10 and 11, 2001. *J Am Acad Dermatol.* 2003;48: 103-10.
- 2- Folliculitis decalvans and lichen planopilaris phenotypic spectrum: a case series of biphasic clinical presentation and theories on pathogenesis. Yip L, Barrett TH, Harries MJ. *Clin Exp Dermatol.* 2020;45(1):63-72. DOI: 10.1111/ced.13989. PMID: 31017678.
- 3- Morais KL, Martins CF, Anzai A, Valente NYS, Romiti R. Lichen Planopilaris with Pustules: A Diagnostic Challenge. *Skin Appendage Disord* 2018;4:61-6.
- 4- Egger A, Stojadinovic O, Miteva M. Folliculitis Decalvans and Lichen Planopilaris Phenotypic Spectrum-A Series of 7 New Cases With Focus on Histopathology. *Am J Dermatopathol* 2020;42:173-7.
- 5- Ramos PM, Miot HA. Exuberant tufted folliculitis. *An Bras Dermatol* 2019;94:115-6.
- 6- Kang H, Alzolibani AA, Otberg N, Shapiro J: Lichen planopilaris. *Dermatol Ther* 2008; 21: 249–256.
- 7- Lobato-Berezo A, González-Farré M, Pujol RM. Pustular frontal fibrosing alopecia: a new variant within the folliculitis decalvans and lichen planopilaris phenotypic spectrum? *Br J Dermatol.* 2022;186(5):905-907. DOI: 10.1111/bjd.20962. PMID: 34939665.
- 8- Karrakchou B, Fliti A, El Fiboumi A, Kettani F, Senouci K, Meziane M. Folliculitis Decalvans with Frontal Fibrosing Alopecia in a Dark Phototype: Presentation of Folliculitis Decalvans and Lichen Planopilaris Phenotypic Spectrum. *Dermatol Pract Concept.* 2023;13(4):e2023229. DOI: <https://doi.org/10.5826/dpc.1304a229>
- 9- Zhang X, Zhu M, Zhou J, Wu S, Liu J, Qin Q. Folliculitis Decalvans and Lichen Planopilaris Phenotypic Spectrum: A Case Report. *Clin Cosmet Investig Dermatol.* 2022 May 31;15:993-996. doi: 10.2147/CCID.S365566. PMID: 35677221; PMCID: PMC9167836.
- 10- Bolduc C, Sperling LC, Shapiro J. Primary cicatricial alopecia: Lymphocytic primary cicatricial alopecias, including chronic cutaneous lupus erythematosus, lichen planopilaris, frontal fibrosing alopecia, and Graham-Little syndrome. *J Am Acad Dermatol.* 2016;75:1081-99. doi: 10.1016/j.jaad.2014.09.058.
- 11- Bolduc C, Sperling LC, Shapiro J. Primary cicatricial alopecia: Other lymphocytic primary cicatricial alopecias and neutrophilic and mixed primary cicatricial alopecias. *J Am Acad Dermatol.* 2016;75:1101-7. doi: 10.1016/j.jaad.2015.01.056.

12-Bernárdez C, Molina-Ruiz AM, Requena L. Histologic features of alopecias: part II: scarring alopecias. *Actas Dermosifiliogr.* 2015;106:260-70. doi: 10.1016/j.ad.2014.06.016.

UNDER PEER REVIEW