

Surgical treatment of macrostomia in Tessier slit no. 7: A case report

Abstract

Summary :

Macrostomia also called maxillomandibular cleft or lateral cleft or commissural cleft or transverse cleft is one of the so-called rare facial clefts as opposed to the labioalveolopalatine clefts. They are unilateral in 80% of cases without significant predominance of the affected side and often in a polymalformative setting.

We report the case of a patient with otomandibular syndrome with macrostomia and therefore part of Tessier no. 7 clefts.

There are several surgical techniques to treat macrostomia, but for this patient we opted for the Préau method to restore the normal anatomy of a labial corner while respecting the 3 planes: mucosal, muscular and cutaneous. The advantage of this technique is to minimize scarring.

Key words: craniofacial malformations, congenital macrostomia, Tessier cleft 7, linear commissuroplasty.

Introduction :

Cleft 7 of Tessier, or commissural cleft or macrostomia is also called lateral or transverse or maxillomandibular or temporo-zygomatic cleft, because it passes between these 2 bones (figure 1). They are rarer than classic cleft lips and palates and can also occur in a polymalformative context. Their reported incidence ranges from 1 in 60,000 to 1 in 300,000 live births.

This is the most common Tessier cleft. They are in 80% of cases unilateral, without significant side predominance, and therefore bilateral in 20% of cases. It is the only Tessier slit that is unrelated to the orbit. This is a lateral slit starting from the corner and heading towards the tragus. There is a clear boundary between the skin and the mucosa along the entire path of the cleft. The form may be moderate, barely visible at rest, and become evident during mimicry.

It can be found in 1st and 2nd arch syndromes, and particularly in otomandibular dysplasia. There are often associated auricular anomalies (microtia, agenesis, etc.) and malformations such as pretragial enchondromas.[1].

The principle of treating cleft 7 is to recreate the lip corner; by properly repairing the orbicularis oculi muscle, create a new commissure and ensure good skin and mucosal closure.

The bilateral forms must be operated in one step, for reasons of ease of equilibration[2].

In unilateral forms, the commissural point is found by comparison and measurement in relation to the healthy side [3].

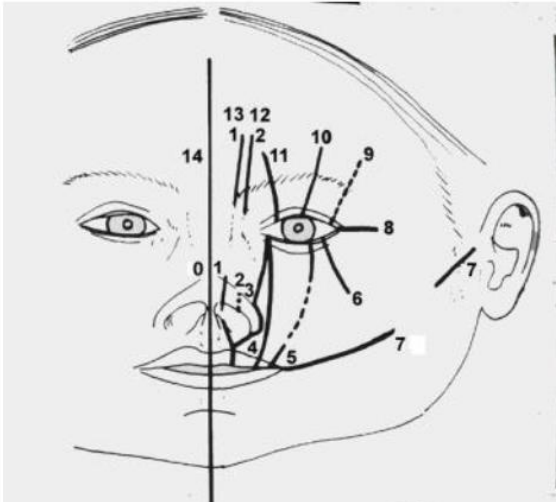


Figure 1: Tessier classification[4]

Case presentation:

This is a 21-month-old infant, from a non-consanguineous marriage, with no notion of a similar history in the family, he was brought for consultation by his mother for difficulty with lip incontinence and for his facial asymmetry. .

On physical examination we note facial asymmetry made up of several facial malformations such as wide unilateral transverse cleft lip, sagging left cheekbone, microtia and absence of the external ear canal, shortening of the lower level of the left face, nodular lesion of the left cheek enchondroma type. (figure 2)

Facial CT revealed multiple malformations ipsilateral to the cleft consisting of hypoplasia of the mandibular ramus, absence of the coroneum and a reduced zygomatic arch. (figure 3)

So in total our patient presents an otomandibular syndrome.

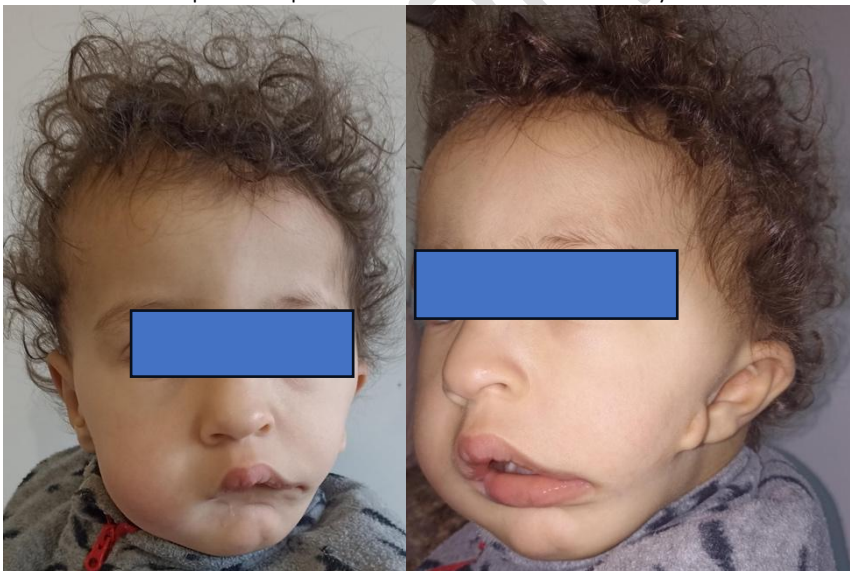

Figure 2: photos of the patient showing the malformations of cleft 7

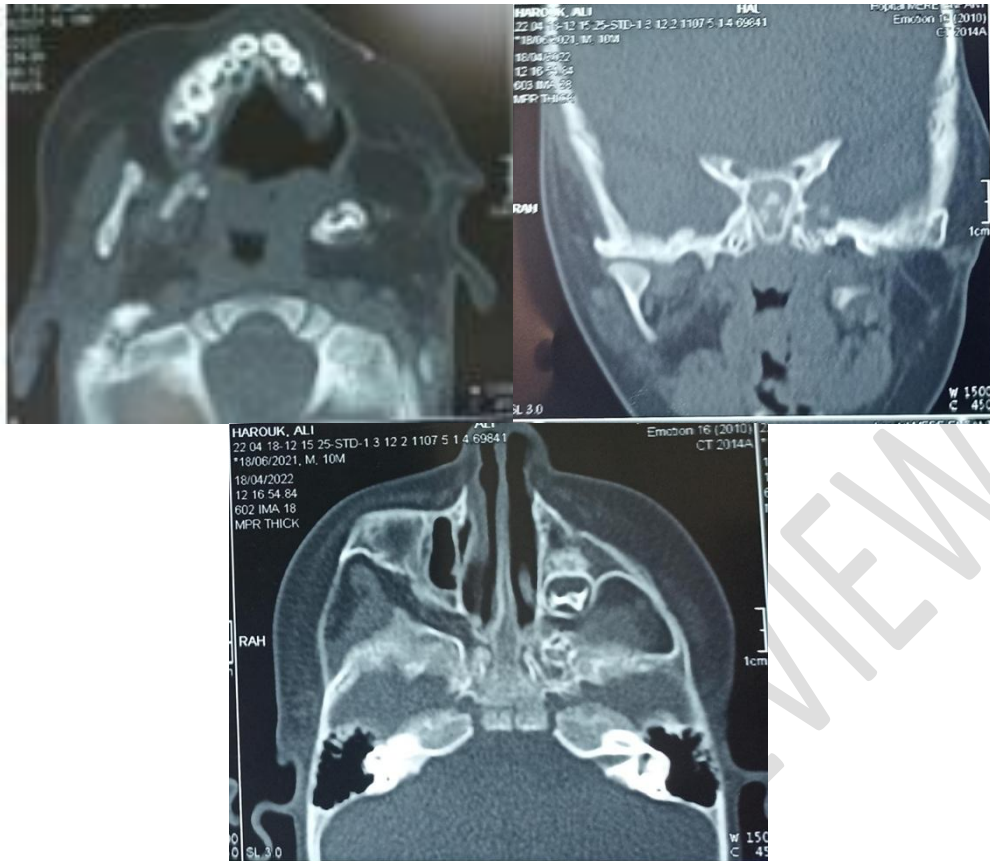

Figure 3: Facial CT imaging results.

We classified the patient's macrostomia as type 1 or minor commissural cleft (Figure 4) where the lips of the cleft side end anterior to the anterior edge of the masseter.[2].

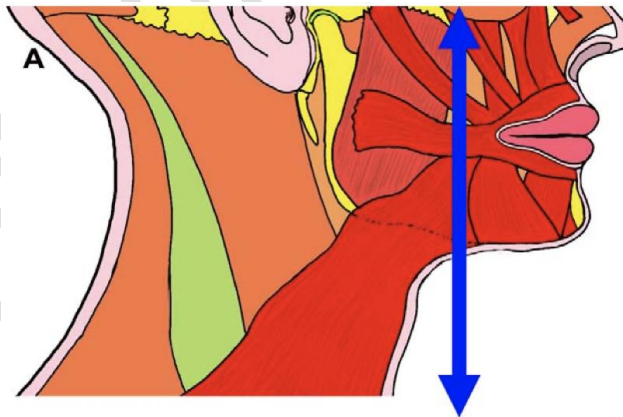


Figure 4: type I commissural slot stopping in front of the anterior edge of the masseter.

Our team opted for a linear commissuroplasty with restoration of muscular continuity according to the Préau process: (figure 5)

- Identification of the neo-commissure
- Incision and dissection of the 3 planes: skin, muscle and mucosa, referring to the landmarks
- Identification of the two heads of the orbicularis muscle and suture after a plastic surgery using the preaux procedure.
- Redocking of the two heads of the orbicularis muscle and the modiolus.
- Excision of two mucosal triangles of the vermilion and direct cutaneous and mucosal suture ensuring a discreet linear scar in the extension of the axis of the two lips.

Note that in this patient, we took advantage of the fact that he was under general anesthesia for the excision of the left pre-auricular fibrocartilaginous lesion process. The postoperative course was simple without local signs of infection or discharge.

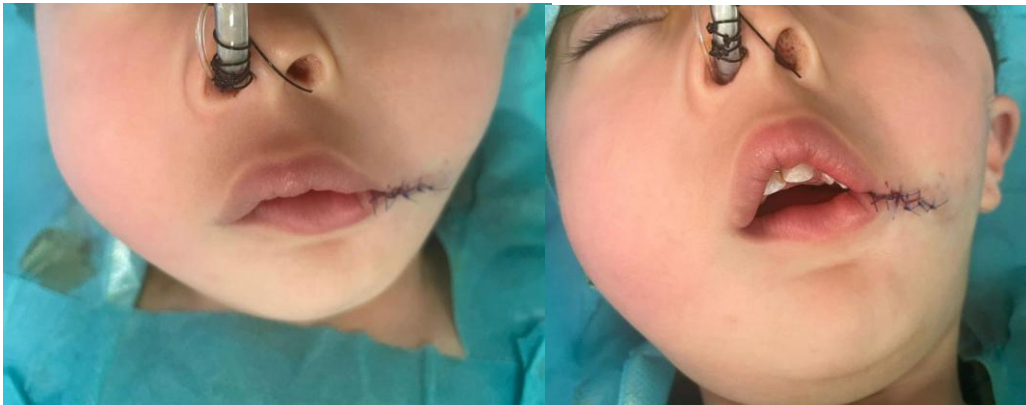

Figure 5: photo of the patient immediately post-operatively on the operating table.

The clinical results at 6 months postoperatively were satisfactory, the patient has an oral cleft of normal size, good lip continence and the surgical scar is linear and barely visible.

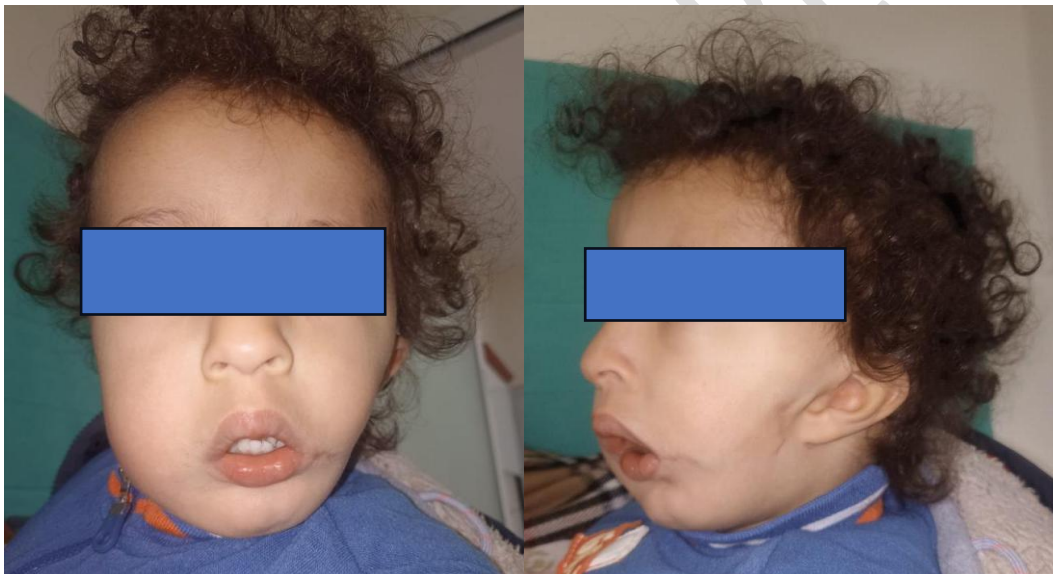

Figure 6: appearance of the patient 6 months postoperatively.

Discussion :

Unilateral commissural clefts are rare, especially Tessier's No. 7 clefts, compared to cleft lip and palate which are quite common. In our context they are extremely rare.

According to literature data and a comparative study of 10 cases carried out by Gleizal et al[5], there is no sexual predominance unlike cleft lip and palate which are more common in males. Clinically, congenital macrostomies are unilateral in 80% of cases, and they are minor in 93% and this is consistent with our data.

In 89% of cases, unilateral forms will be associated with other facial malformations such as fibrochondromas (found in our patient), most often pre-auricular and sometimes jugal following the path of fusion of the maxillo-mandibular buds. In addition to auricular shape anomalies such as microtia, agenesis or supernumerary ear. Bone anomalies are also

frequently associated: 58% of cases in the mandible (otomandibular syndrome) and 13% of cases in the maxilla.

The management of macrostomies is always surgical, which will include mucosal repair, orbicular myoplasty and a linear or Z-shaped skin suture. Wide Z-plasties are described by Mansfield and give poor aesthetic results requiring large undercuts.[6].

Conclusion :

Congenital macrostomia is a rare pathology and deserves early treatment in order to restore the functional, aesthetic and psychological problems that it promotes.

Unilateral forms are often associated with other facial malformations and also require early treatment and close monitoring.

Reference :

¹Tessier P. Anatomical classification of facial, cranio-facial and laterofacial clefts. J Maxillofac Surg 1976; 4:69-92

²Ryu JY, Eo PS, Tian L, Lee JS, Lee JW, Choi KY, Yang JD, Chung HY, Cho BC. Surgical correction for Tessier number 7 craniofacial cleft using a medially overcorrected design. Arch Plast Surg 2019; 46, 1:16-22.

³Ryu JY, Eo PS, Tian L, Lee JS, Lee JW, Choi KY, Yang JD, Chung HY, Cho BC. Surgical correction for Tessier number 7 craniofacial cleft using a medially overcorrected design. Arch Plast Surg 2019; 46, 1:16-22.

⁴Kahn.J, Wilk.A Clefts and facial malformations. Specialty module Stomatology, Maxillofacial Surgery and Reconstructive Plastic Surgery 2007-2008.

⁵A. Gleizal, S. Comiti, L. Caquant, J.-L. Beziat Epidemiological and clinical study of macrostomies. About a series of ten observations

⁶Mansfield OT, Herbert DC, Mulliken JB, Unilateral transverse facial cleft, a method of surgical closure