

Anal melanoma: An atypical case.

## ABSTRACT.

When talking about "Melanoma" it is easy to think that it is a malignant tumor produced by the alteration of melanocytes, but we leave aside that there can also be melanomas in the mucous membrane, it is certainly an atypical presentation but not impossible. Now, a melanoma in the anal mucosa is still an atypical and unusual presentation, adding that its symptoms are variable, and can be confused with any other pathology, which makes its diagnosis difficult and impoverishes its prognosis as there is no early treatment.

We present the case of a woman in her sixth decade of life, with non-specific symptoms in the anal region. Being a rare case, it is right to emphasize its clinicopathological importance.

KEY WORDS: MELANOMA; ANAL; PEDICULATED; PROLAPSE; RECTAL; MUCOUS MEMBRANE.

## INTRODUCTION

A melanoma is a tumor arising from produced by the malignant transformation of melanocytes. Melanocytes may arise in other places where neural crest cells migrate, such as the gastrointestinal tract and the brain.<sup>1</sup>

Melanomas of the mucosa are neoplasms that arise from melanocytes of the epithelium of oral and nasal cavities, conjunctiva, genitourinary tract and anorectal area, these are the common types of mucosal melanomas.<sup>2-4</sup>

Some DNA viruses are they investigated in few studies, herpesviruses, Epstein Barr Virus, polioma virus, parvoviruses, papillomavirus and B19 virus, finding in all studied cases, results statistically negatives, in patients with mucosal melanoma.<sup>5-6</sup>

There are many types of genetic aberrations that affect the landscape of these pathologies, alterations of SF3B1, KIT and NF1 are the more common and studied, although BRAF, NRAS and other mutations investigated. Recently PI3K/mTOR and MEK pathways are being studied in diverse clinical trials as treatment options.<sup>7-8</sup>

Newell, et al, described a case in which a genomic alteration, structural DNA variants, mutated genes, cancer driver gene mutations, telomere length had a severe clinical implications.<sup>9</sup>

Anorectal melanoma is a very rare and highly malignant tumor with a poor survival with a less than 5 years of survival in 10% of patients. Typical symptoms such as anal itching or rectal pain can mimic hemorrhoids or rectal polyps. It is the limited knowledge about the etiology, pathogenesis and genetics makes correct and timely diagnosis difficult. It represents only 1.3% of all melanomas and 16.5% of mucosal melanomas. The prevalence is 1.6 to 2.3 times higher in women than in men. Lesions can

affect anal canal, rectum, or both, but the majority of tumors are located within 6 cm proximal to the anal verge. 20 to 30% are amelanotic, and resemble polypoid lesions endoscopically, nonspecific symptoms may contribute to misdiagnosis.<sup>2</sup>.

The diagnosis is always made by biopsy and immunohistochemistry. Colonoscopy combined with biopsy and pathological examination allow precision in the diagnosis. Histology and immunohistochemistry are the gold standard diagnostic method. Histological examination characterizes the lesions according to their cell type, degree of melanin pigmentation, and mitotic index. Mucosal melanomas show a high degree of nuclear pleomorphism, and may be epithelioid or fusiform and frequently present melanin granules. Immunohistochemical diagnosis is possible thanks to the antibodies protein S-100, HMB-45, Melan A/Mart-1<sup>2</sup>.

#### CASE PRESENTATION.

A female farmer with 51-year-old, who presented to consultation due for rectal prolapse of 1 month of evolution and progressive increase of pain. The patient only reported a sensation of a foreign body in the anal region. Physical examination revealed indurated neoplasia in the posterior anal margin; and a significant weight loss of more than 10 kilograms in 4 months and bad general condition, due to the clinical findings, it was decided surgical resection with wide surgical margins.

After the surgical resection of the lesion, the patient no longer went to the hospital for unknown causes

In the pathology department, was received a polypoid specimen, that measured 6x4x3 centimeters, with a pedicle 1.5 centimeters of long, semi-firm consistency, surface gray-brown (Figure 1A), at cut surface is solid, homogeneous brown with hemorrhagic areas (Figure 1B).

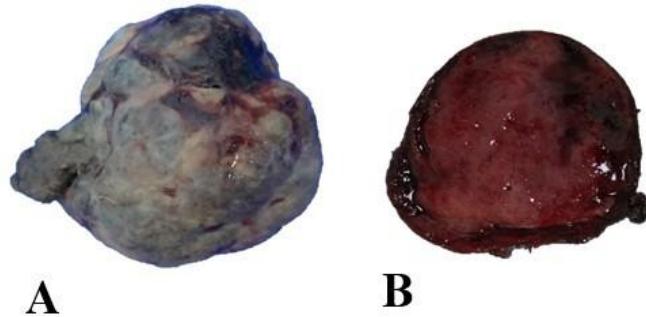


Figure 1: A) Hemispherical tissue with an irregular surface, gray-brown in color, slightly lobed, measuring 6x4x3 centimeters and a pedicle of 1.5 centimeters. B) At cut, homogeneous, solid, reddish-brown surface..

Histology reported cells with ovoid to polyhedral cytoplasm, ovoid nuclei, with prominent and reddish nucleoli, accompanied by brown pigment with diffusely infiltrating of the submucosa and form nodules divided by connective tissue septa (Figure 2A-2C).

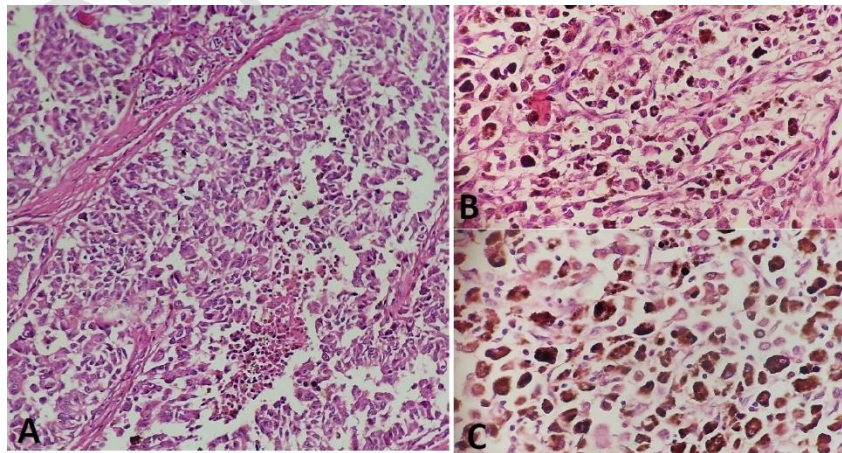


Figure 2: A) (4x): Cells in the papillary and deep dermis, which diffuse infiltrating and form nodules and it is divided by connective tissue septa. B-C) (40x) Cells with ovoid to polyhedral cytoplasm with ovoid nuclei, with a prominent and reddish nucleolus, accompanied by brown pigment.

Immunolabeling is done to confirm the diagnosis (Figure 3A-3C)..

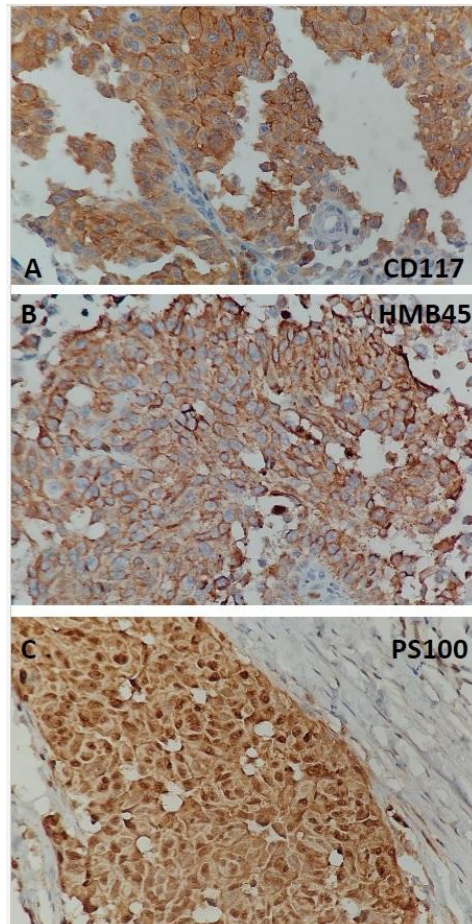


Figure 3: Photomicrographs of histological sections of immunohistochemistry. A) (40x) CD117 staining pattern in cytoplasm of intensely positive melanoma cells. B) (40x) HMB45 positive staining pattern in cytoplasm of neoplastic cells. C) (40x) PS100 cytoplasmic staining pattern in positive melanoma cells.

## DISCUSSION

Melanoma is defined as a malignant tumor originating from melanocytes, consequently its extension can be wide, throughout the entire neural crest, therefore it can be found not only on the skin and also in the mucous membranes. In the case of cutaneous melanoma, it is a well-recognized neoplasm. However, its location in the anal mucosa is uncommon and difficult to diagnose. Regarding this case, a mucosal melanoma covers 1% of all melanomas, which considers this case rare. Mucosal locations make early diagnosis

difficult, mainly for their ambiguous clinical manifestations, for both the patient and the doctor. Knowledge regarding mucosal melanoma is scarce; Strictly placing ourselves in the anorectal region, this pathology accounts for 0.1-4.6% of anal tumors and between 16.5% of mucosal melanomas.<sup>3</sup>

It usually presents with an age range between the fourth and seventh decade of life, so its age range is quite wide. It shows a higher incidence in women than in men, however, specific risk factors have not yet been identified. Unlike skin melanoma, which has been directly linked to exposure to ultraviolet rays, tobacco use, or human papillomavirus infection; For its part, in the case of melanoma of the anal mucosa, there are no well-established causal factors; however, related cases have been described in patients with infection by the human immunodeficiency virus, where intensity and duration of immunodeficiency in the immune system play an important role<sup>4</sup>.

As it is so rare and has a poor prognosis, it is important to generate literature to develop adequate clinical management in these patients and in the future to carry out adequate therapeutic management. To date, there is no established therapeutic guideline.<sup>5</sup>

It is worth emphasizing the multidisciplinary treatment that should be imperative in the management of these patients, since aggressive treatment will lead to a decline in quality of life, due to complications that may arise after treatment<sup>6</sup>.

## **CONCLUSION**

Melanoma in the anorectal mucosa is a rare tumor with quite aggressive behavior and a poor prognosis for life. The clinical, biological and molecular characteristics make mucosal melanoma discordant with its cutaneous counterpart. Surgical treatment with wide margins in localized cases continues to be the method of choice, however there is no optimal treatment. Target therapy in cases of metastasis is still in the research process so it can offer an important influence on the prognosis in the long term.

#### ETHICAL CONSIDERATIONS.

The authors declare that no experiments have been carried out on human beings for this research. We use protocols to obtain patient databases from our workplace, preserving the anonymity of the patient (so we do not request informed consent). This study complies with current bioethical research regulations.

#### REFERENCES.

1. Spencer KR, Mehnert JM. Springer et al. Mucosal Melanoma: Epidemiology, Biology and Treatment, Cancer Research and Treatment, 2016, volume 167, pages 295-320. [https://doi.org/10.1007/978-3-319-22539-5\\_13](https://doi.org/10.1007/978-3-319-22539-5_13)
2. Wang, H.-Y., Liu, Y., Deng, L., Jiang, K., Yang, X.-H., Wu, X.-Y., Guo, K.-H., & Wang, F. (2023). Clinical significance of genetic profiling based on different anatomic sites in patients with mucosal

- melanoma who received or did not receive immune checkpoint inhibitors. *Cancer Cell International*, 23(1). <https://doi.org/10.1186/s12935-023-03032-3>
3. Carbó-Bagué, A., Rubió-Casadevall, J., Puigdemont, M., Sanvisens, A., Oliveras, G., Coll, M., del Olmo, B., Perez-Bueno, F., & Marcos-Gragera, R. (2022). Epidemiology and molecular profile of mucosal melanoma: A population-based study in southern Europe. *Cancers*, 14(3), 780. <https://doi.org/10.3390/cancers14030780>
  4. Mikkelsen, L. H., Maag, E., Andersen, M. K., Kruhøffer, M., Larsen, A.-C., Melchior, L. C., Toft, P. B., von Buchwald, C., Wadt, K., & Heegaard, S. (2020). The molecular profile of mucosal melanoma. *Melanoma Research*, 30(6), 533–542. <https://doi.org/10.1097/cmr.0000000000000686>
  5. Arvia, R., Tanturli, M., Ugolini, F., Vannucchi, M., Massi, D., & Zakrzewska, K. (2023). Molecular investigation of some DNA viruses in mucosal melanoma: Case–control study. *Journal of Medical Virology*, 95(11). <https://doi.org/10.1002/jmv.29269>
  6. Ciccamese, G., Drago, F., Broccolo, F., Pastorino, A., Pizzatti, L., Atzori, L., Pilloni, L., Santinelli, D., Urbani, A., Parodi, A., Tomasini, C., & Rongioletti, F. (2023). Oncoviruses and melanomas: A retrospective study and literature review. *Journal of Medical Virology*, 95(1). <https://doi.org/10.1002/jmv.27924>
  7. Broit, N., Johansson, P. A., Rodgers, C. B., Walpole, S. T., Newell, F., Hayward, N. K., & Pritchard, A. L. (2021). Meta-analysis and systematic review of the genomics of mucosal melanoma. *Molecular Cancer Research: MCR*, 19(6), 991–1004. <https://doi.org/10.1158/1541-7786.mcr-20-0839>

8. Si, L., Wang, X., & Guo, J. (2014). Genotyping of mucosal melanoma. *Chinese Clinical Oncology*, 3(3), 34.  
<https://doi.org/10.3978/j.issn.2304-3865.2014.07.03>
9. Newell, F., Kong, Y., Wilmott, J. S., Johansson, P. A., Ferguson, P. M., Cui, C., Li, Z., Kazakoff, S. H., Burke, H., Dodds, T. J., Patch, A.-M., Nones, K., Tembe, V., Shang, P., van der Weyden, L., Wong, K., Holmes, O., Lo, S., Leonard, C., ... Scolyer, R. A. (2019). Whole-genomelandscape of mucosal melanoma reveals diverse drivers and therapeutic targets. *Nature Communications*, 10(1). <https://doi.org/10.1038/s41467-019-11107-x>
10. Malaguarnera G, Madeddu R, Catania VE, et al. Anorectal mucosal melanoma. *Oncotarget*, 2018, volume 9, pages 8785-800.  
<https://doi.org/10.18632/oncotarget.23835>
11. Montes-Osorio ZE, Moreno-Berber JM. Anorectal melanoma, case report and literature review et al. *Cir Gen*, 2017, volume 39, pages 232-236.  
<https://doi.org/10.35366/77694>
12. Venanzi Rullo E, Maimone MG, Fiorica F et al. Non-Melanoma Skin Cancer in People Living With HIV: From Epidemiology to Clinical Management, *Front Oncol*, 2021, volume 11. <https://doi.org/10.3389/fonc.2021.689789>
13. Elsamna ST, Ahsanuddin S, Mir GS et al. Surgical Margin Status and Survival Following Resection of Sinonasal Mucosal Melanoma. *Laryngoscope*, 2021, volume 131, pages 2429-2435. <https://doi.org/10.1002/lary.29574>
14. Ottaviano M, Giunta EF, Marandino L et al. Anorectal and Genital Mucosal Melanoma: Diagnostic Challenges, Current Knowledge and

Therapeutic Opportunities of Rare Melanomas. *Biomedicines*, 2022, volume 10,  
page 150. <https://doi.org/10.3390/biomedicines10010150>

UNDER PEER REVIEW