

## Case report

# Management of a bilateral ectopia lentis in a patient with Marfan syndrome: a case report

### ABSTRACT

**AIMS:** to highlight the management procedure of a bilateral subluxated lens in a patient with marfan syndrome.

**Case report:** We report a case of a 51-year-old woman, with a family history of Marfan syndrome; who presented for a bilateral subluxated lens, iridodonesis and bilateral macular degeneration. Given the family history, the general physical features and the ocular findings, diagnostic of Marfan syndrome was established. The management of the ectopic lentis was very challenging. An intracapsular lens extraction with posterior chamber intraocular lens fixed to the sclera was performed and the patient regained 2/10 visual acuity on the right eye and remained at counting fingers in the left.

**Conclusion:** Marfan syndrome is a rare condition, with various ocular manifestations and complications.

**Comment [u1]:** Summarize your finding with objectives dont generalise the statement

### 1. INTRODUCTION

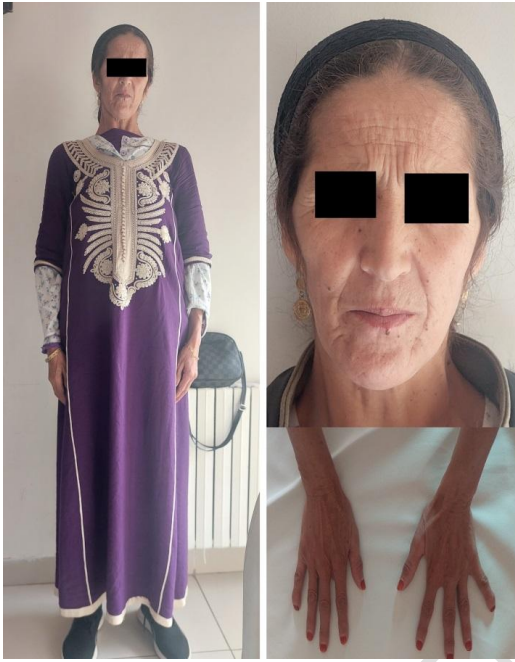Marfan syndrome is an autosomal dominant genetic connective tissue disorder resulting from FBN1 (15q21.1) gene mutation. It typically affects the cardiovascular, skeletal and ocular systems but can also involve other systems such as the central nervous system, skin and the respiratory system. [1]

Ocular manifestations of Marfan syndrome are numerous, crystalline lens dislocation or ectopia lentis constitutes the most frequent one, and has been reported to happen in up the 70% cases. It can cause symptoms like blurred vision, or monocular diplopia. Its management is still, to this day very challenging and depends on the severity of the symptoms, patients' age and the degree of dislocation, among other parameters.

### 2. CASE REPORT

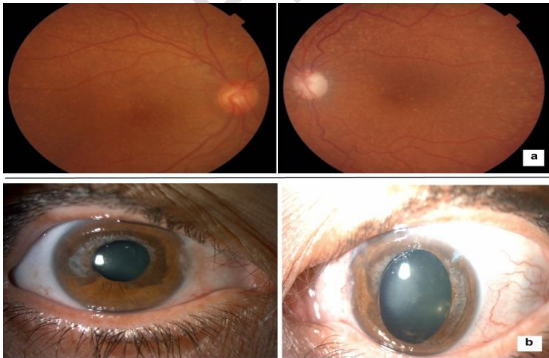
We describe the case of a 51-year-old female patient, with a family history of Marfan syndrome; who presented to our department with progressive decreased visual acuity. General examination revealed a patient of tall stature (177 cm), tall narrow face shaped, and long slender fingers (fig.1).

**Comment [u2]:** Diagnosed since how many years , birth..  
Mention the diagnostic criteria



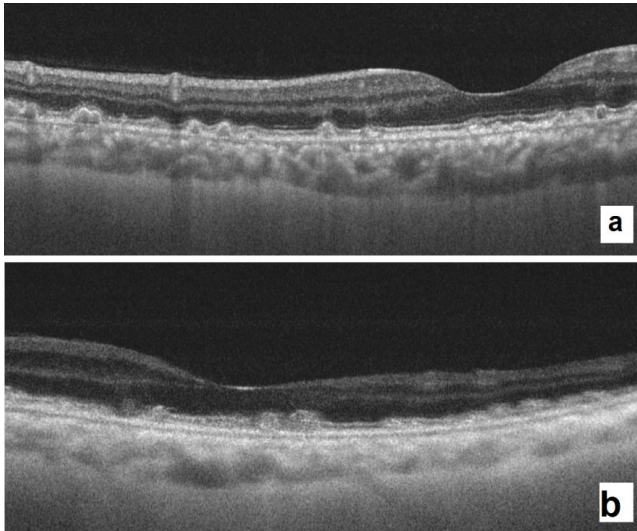
**Fig. 1. Image showing the The main clinical signs that may point to Marfan syndrome : a suggestive morphotype (large size with a lanky morphotype) and arachnodactyly.**

Ophthalmological examination revealed a distance visual acuity limited to counting fingers in both eyes, the automated refraction was not obtainable. Ocular pressure was within normal range. Examination of the anterior segment showed clear corneas, iridodonesis, and ectopic opaque crystalline lenses bilaterally. Fundus revealed multiple drusens scattered throughout the retina, reduced macular reflex, and chorio-retinal atrophy (fig.2).



**Fig. 2. Image resuming the biomicroscopique exam. 2a/ image showing fundus : multiple diffuse drusens scattered throughout the retina. 2b/ image showing bilateral iris atrophy and subluxated ectopic lens.**

Optical coherence tomography (OCT) showed bilateral diffuse drusens and remodeling of the pigment epithelial layer associated to choroidal thickening ( fig.3).



**Figure 3. OCT image showing remodeling of the pigment epithelial layer and choroidal thickening. 3a/ right eye. 3b/ left eye.**

Given the family history, the general physical features of the patient and ocular findings, diagnostic of Marfan syndrome was established. The patient was referred to the internal medicine department for further assessment of other possible systemic abnormalities.

On the other hand, the management of the ectopic lentis was very challenging due to the zonular weakness, the lens instability, and the possibility of a mediocre visual acuity recovery because of undiagnosed amblyopia. After considering the different treatment options, we opted for an intracapsular lens extraction with posterior chamber intraocular lens fixed to the iris. Post-operative visual acuity at 3 months improved to 2/10 on the right eye and remained at counting fingers in the left. We followed up closely the patient, after 1 year no complication has occurred.

### **3. DISCUSSION**

Ectopia lentis is observed in 50% to 80% of Marfan syndrome cases, frequently presenting as the primary clinical manifestation. [2]

The primary approach in managing lens subluxation involves correcting refractive errors with eyeglasses. However, if the subluxation is significant, characterized by the lens intersecting the pupil, posterior dislocation into the vitreous cavity, or anterior dislocation of the lens with or without secondary glaucoma, solely relying on eyeglasses is unlikely to restore visual function. In such cases, extraction of the crystalline lens becomes necessary.[3]

Historically, due to the elevated occurrence of intra- and postoperative complications and unsatisfactory visual results, surgery was not widely favored. However, with advancements

in microsurgical instruments and surgical techniques, there has been a resurgence of interest in surgical intervention. Several surgical strategies for managing ectopia lentis in Marfan syndrome have been described including standard lensectomy with or without anterior vitrectomy, or lens extraction using capsular tension rings when mild zonular desinsertion is present. Post-operative refractive rehabilitation may consist of the utilization of aphakic glasses, contact lenses, or intra-ocular lenses scleral-fixated, iris-fixated in the anterior or posterior chamber. [4]

Following surgery, patients should undergo regular monitoring for IOL alignment, retinal degeneration and detachment that are reported to be present in 18% of eyes in Marfan syndrome; this incidence is higher up to 70% in patients with a subluxated lens. Moreover, patients should be encouraged to promptly seek ophthalmological assessment if they notice flashes, floaters, or encounter any partial or complete vision loss.

**Comment [u3]:** Give your opinion or experience about treating this case.

#### 4. CONCLUSION

Marfan syndrome is a rare condition, with various ocular manifestations and complications. Therefore, Ophthalmologists play a substantial role in making a prompt clinical diagnosis and a well thought out therapeutic approach, sole guarantee of a better visual outcome and a significantly improved life quality.

#### CONSENT

As per international standards or university standards, patient(s) written consent has been collected and preserved by the author(s).

#### ETHICAL APPROVAL

It is not applicable.

#### REFERENCES

- [1] H. Akram, J. A. Aragon-Martin, and A. Chandra, "Marfan syndrome and the eye clinic: from diagnosis to management," *Ther Adv Rare Dis*, vol. 2, p. 26330040211055738, Nov. 2021, doi: 10.1177/26330040211055738.
- [2] S. Shah, M. Shah, P. Chandane, S. Makhloga, D. Thorat, and M. Sanghani, "Clinical profile and outcome of ocular manifestation in Marfans syndrome in India," *Indian J Ophthalmol*, vol. 70, no. 2, pp. 626–629, Feb. 2022, doi: 10.4103/ijo.IJO\_1651\_21.
- [3] H. Esfandiari, S. Ansari, H. Mohammad-Rabei, and M. B. Mets, "Management Strategies of Ocular Abnormalities in Patients with Marfan Syndrome: Current Perspective," *J Ophthalmic Vis Res*, vol. 14, no. 1, pp. 71–77, 2019, doi: 10.4103/jovr.jovr\_29\_18.
- [4] V. Miraldi Utz, R. G. Coussa, and E. I. Traboulsi, "Surgical management of lens subluxation in Marfan syndrome," *Journal of American Association for Pediatric Ophthalmology and Strabismus*, vol. 18, no. 2, pp. 140–146, Apr. 2014, doi: 10.1016/j.jaapos.2013.12.007.

UNDER PEER REVIEW

