

## Case report

# Lipoblastoma of the thigh in children: a case report

### ABSTRACT

**Aims:** Lipoblastoma is a rare, benign tumor originating from embryonal fat, affecting primarily children under 3 years. The aim of our paper is to evaluate the clinical presentation, diagnostic challenges, management strategies, and outcomes of thigh lipoblastoma.

**Case presentation:** A 16-month-old boy with no significant medical history was brought to our hospital due to a four-month-growing mass on the back of his left thigh. Examination revealed a large, solid, painful mass without systemic symptoms. Imaging (X-ray, ultrasound, MRI) identified a large, hyperechoic mass with specific characteristics suggesting lipoblastoma, confirmed by the pathological study after excision. The tumor was successfully removed under general anesthesia, with no postoperative complications or recurrence after one year follow-up.

**Discussion:** First described in 1973, lipoblastoma is a benign tumor from embryonal white fat, varying in presentation from localized, superficial masses to diffuse forms. It primarily affects male infants under the age of 3 years old. The tumor's clinical presentation can range from asymptomatic to invasive, potentially affecting vital structures. Diagnosis primarily relies on the MRI for its distinct imaging features. Ensuring complete surgical removal with free margins is vital to prevent recurrence.

**Conclusion:** Lipoblastoma should be a key consideration in the differential diagnosis of fatty masses in young children under the age of 3 years. Despite its benign character, the follow-up is crucial to confirm there's no recurrence, even after complete resection.

*Keywords: Lipoblastoma, children, thigh, lipoblastomasis.*

### 1. INTRODUCTION

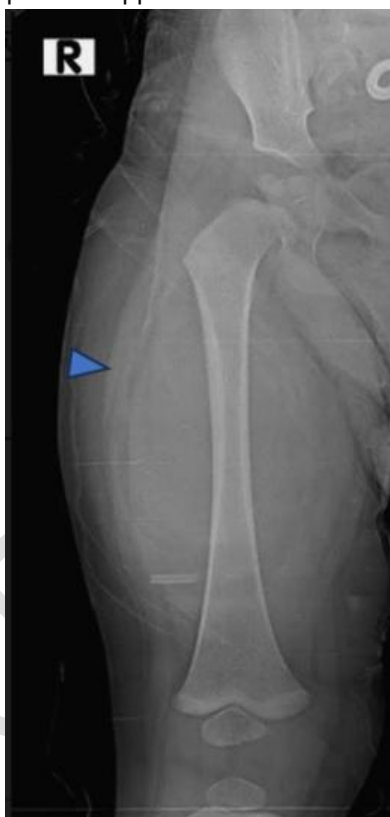Lipoblastoma is a rare and benign mesenchymal tumor arising from embryonal fat tissue [1], with less than 250 cases reported in the literature. It usually affects children younger than 3 years of age and occurs mostly in the extremities. It can present with a rapid growth rate and can reach a large size in short time [2]. Lipoblastomas are categorized into two distinct subtypes: encapsulated well-circumscribed "lipoblastomas" and diffuse non-capsulated forms known as

“lipoblastomatosis” [3]. These neoplasms have no malignant potential, they can be locally invasive and may recur in case of incomplete resection. [4].

## 2. CASE PRESENTATION

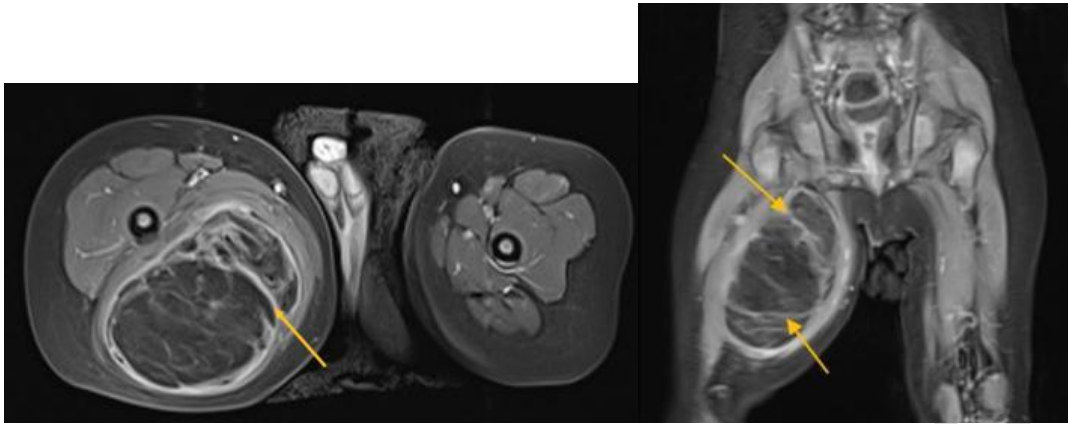
A 16-month-old male infant -with no medical history of trauma, infection or tuberculosis- was brought to our hospital for a tumefaction located high up on the back of the left thigh, that had been developing over a period of four months, gradually increasing in size, without functional impairment, bone pain, fever, deteriorating of general condition or any other associated symptoms.

A physical examination revealed a well-developed infant with a large solid, fixed and painful mass on the posterior left thigh, with collateral venous circulation. The Femur X-ray (Fig. 1) showed a large oval opacity with clear and regular contours, occupying almost the entire posterior compartment of the soft tissues of the left thigh without calcifications or bone lesions. The ultra-sound revealed a well-demarcated, oval, hyperechoic formation measuring approximately 6.4x6 cm, traversed by thick hyper-vascularized septa on Doppler.



**Fig. 1. Femur X-ray showing a large oval opacity with clear and regular contours (blue arrow).**

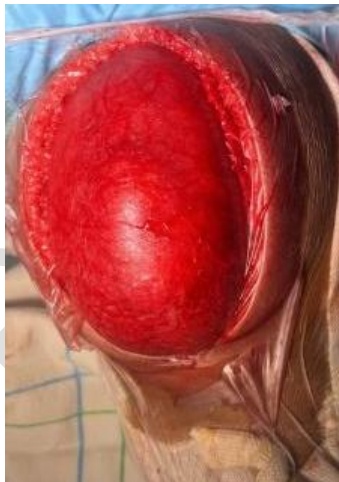The MRI revealed a subaponeurotic intermuscular tumoral process (Fig. 2) with heterogeneous signal characteristics, including a fatty component that appears hyperintense in T1 and T2, which disappears after fat saturation, and septa that are hypointense in T1 and T2 but enhance after Gadolinium injection, without any bone signal abnormalities. Lipoblastoma was the primary diagnosis considered.



**Fig. 2. Thigh's MRI revealing a subaponeurotic intermuscular tumoral process with heterogeneous signal characteristics, and septa (yellow arrows).**

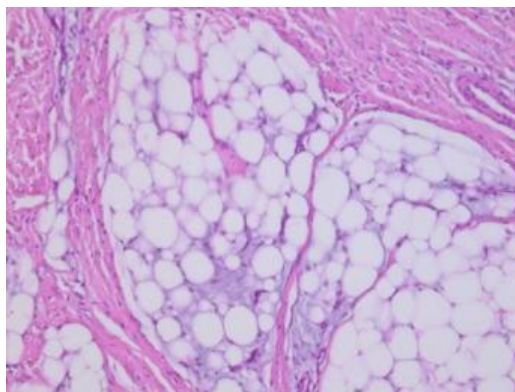
The blood work showed a high level of LDH (520 U/L), normal C-reactive protein (1.3mg/L), a normal white cell count ( $5 \times 10^9$  /L) and a microcytic hypochromic anemia (10.5g/dL).

Immediate excision of the tumor was indicated. The patient underwent general anesthesia; a posterior approach to the thigh with longitudinal incision was done (Fig. 3). The mass was encapsulated and adherent at its superior and inferior poles. The sciatic nerve was distant from the mass. Meticulous dissection was performed, and the mass was removed without any incident.



**Fig. 3. Intraoperative view showing the longitudinal incision along the thigh.**

The pathological study of the mass showed an adipose tumoral proliferation arranged in lobulated leaflets separated by fibrous septa with myxoid areas. The tumor cells corresponded sometimes to stellate cells and sometimes to lipoblasts, confirming the diagnosis of lipoblastoma (Fig. 4). The postoperative course was uneventful. There was no evidence of recurrence on the 6 and the 12 months follow-up, and the child is doing well.



**Fig. 4. The pathological study of the mass showed an adipose tumoral proliferation arranged in lobulated leaflets separated by fibrous septa with myxoid areas.**

### **3. DISCUSSION**

Lipoblastoma and lipoblastomatosis, described by Chung and Enzinger in 1973, are rare and benign tumors arising from embryonal white fat. Lipoblastoma presents as a localized, superficial, lobulated, encapsulated or circumscribed form. In contrast, lipoblastomatosis is the diffuse infiltrative one [1,5]. Lipoblastoma occurs predominantly in male children younger than 3 years of age, 40% before the age of 1 year [2]. They are mostly located in the extremities (70%) and the trunk (20%), but can be located anywhere in the body (neck, scrotum, axilla, mediastinum and intraperitoneal) [5,6,7]. Clinically the lipoblastoma varies in size; it can be infiltrative and affect vital structures in the thorax, neck or abdomen, causing morbidity [8], or it can be asymptomatic and non-tender when smaller [5]. No metastasis has been reported in the literature, [9,10]. The Ultrasound shows either a homogeneous hyper-echoic multinodular mass or a heterogeneous mass containing hyper-echoic areas and others weakly echoic at the level of myxoid tissues. The CT scan confirms the presence of a fatty component with no enhancement after contrast injection [11]. The MRI is the most useful tool in term of the preoperative evaluation and diagnosis. the lipoblastoma presents as a T1 hyperintensity that disappears after fat suppression, an intermediate or T2 hyperintensity, and signal cancellation on fat suppression sequences [12,13]. The Main differential diagnoses for lipoblastoma are lipoma and myxoid liposarcoma, each requiring distinct treatments, and confirmed only through anatomopathological study. It typically shows lobulated adipose tissue with fibrous septa separating the individual lobules, and myxoid stroma with varying degree of immature adipocytes [11,9]. Spontaneous regression has not been described. Complete surgical resection remains the treatment of choice with free margins to prevent recurrence, that can reach 25% of the cases requiring re-excisions [9,10]. Recently, a more conservative approach has been described for large invasive lesions, such as those with neurovascular invasions, or lesions in locations that would lead to mutilating surgical excisions [14]. Regardless of whether margins are free or not, all patients must be followed up for at least 5 years on a 6-month basis to monitor recurrence. For those with incomplete excision, the MRI remain a useful tool for monitoring tumor progression.

### **4. CONCLUSION**

Lipoblastoma, a rare tumor, should be considered when diagnosing fatty masses in children under the age of three. MRI plays an essential role in the diagnosis, surgical planning, and ongoing surveillance of the tumor. Complete removal through surgery is crucial to prevent recurrence. Long-term follow-up is required for monitoring of any subsequent developments.

## CONSENT

All authors declare that written informed consent was obtained from the parents of the patient for publication of this case report and accompanying images. A copy of the written consent is available for review by the Editorial office/Chief Editor/Editorial Board members of this journal.

## ETHICAL APPROVAL

As this is a case report involving routine clinical care and no experimental interventions, ethical approval was not required.

## REFERENCES

1. Rajput S, Alsubaie SA, Singh K, Huang TC, Moran SL. Lipoblastoma of the extremities. *J Plast Reconstr Aesthet Surg*. 2022 Oct;75(10):3761-3767. doi: 10.1016/j.bjps.2022.06.077
2. Steckman, D., Zide, B., Greco, M. A., Rivera, R., & Blei, F. (2005). Lipoblastoma of Infancy Mimicking Hemangioma of Infancy. *Archives of Facial Plastic Surgery*, 7(5), 326. doi:10.1001/archfaci.7.5.326
3. Chung EB, Enzinger FM. Benign lipoblastomatosis: An analysis of 35 cases. *Cancer* 1973; 32: 482\_92
4. Bourelle S, Viehweger E, Launay F, Quilichini B, Bouvier C, Hagemeijer A, Jouve JL, Bollini G. Lipoblastoma and lipoblastomatosis. *J Pediatr Orthop B*. 2006 Sep;15(5):356-61
5. Chung EB, Enzinger FM (1973) Benign lipoblastomatosis. An analysis of 35 cases. *Cancer* 32:482–492
6. Sakaida M, Shimizu T, Kishioka C, et al. Lipoblastoma of the neck: a case report and literature review. *Am J Otolaryngol* 2004;25:266Y269
7. Stringel G, Shandling B, Mancer K, Ein SH. Lipoblastoma in infants and children. *J Pediatr Surg*. 1982 Jun;17(3):277-80
8. Hicks J, Dilley A, Patel D, Barrish J, Zhu SH, Brandt M (2001) Lipoblastoma and lipoblastomatosis in infancy and childhood: histopathologic, ultrastructural, and cytogenetic features. *Ultrastruct Path* 25(4):321–333
9. Jimenez JF (1986) Lipoblastoma in infancy and childhood. *J Surg Oncol* 32(4):238–244.
10. Stringel G, Shandling B, Mancer K, Ein SH (1982) Lipoblastoma in infants and children. *J Ped Surg* 17(3):277–280.
11. Pham NS, Poirier B, Fuller SC, et al. Pediatric lipoblastoma in the head and neck: a systematic review of 48 reported cases. *Int J Pediatr Otorhinolaryngol* 2010;74:723Y728
12. Brodsky JR, Kim DY, Jiang Z. Cervical lipoblastoma: case report, review of literature, and genetic analysis. *Head Neck* 2007;29:1055Y1060
13. Lehlimi M, Amenzouin, Adnane F, Najib N, Yousri B. A propos d'une Tumeur axillaire. *Journal Marocain des Sciences Médicales* 2014, Tome XIX; N°2.
14. McVay MR, Keller JE, Wagner CW, Jackson RJ, Smith SD (2006) Surgical management of lipoblastoma. *J Ped Surg* 41(6):1067– 1071