

Case report

BONE-FORMING ANGIOMYOLIPOMA OF THE KIDNEY

ABSTRACT

Angiomyolipomas (AML) are the most common benign renal tumors, occurring sporadically or as a part of tuberous sclerosis syndrome. Even though there are several histological subtypes for renal AML with rare occurrences of calcification, gross ossification has not been identified so far. We present the case report of a sporadic renal AML with radiological, intra operative, pathological, and histological features suggestive of massive bone formation within the tumour.

KEY WORDS

angiomyolipoma, kidney, ossification, osseous metaplasia, benign tumor

INTRODUCTION

Angiomyolipomas (AML) are the most common benign renal tumors with estimated prevalence of 0.13% in the general population. The incidence of AML is about 50% to 90% among patients with tuberous sclerosis. AMLs are most often detected incidentally in abdominal ultrasound examinations. Histologically, classic AML is composed of mature adipocytes, dysmorphic blood vessels, smooth muscle elements and varying proportion of epithelioid cells. In contrary to other renal tumors, an imagological diagnosis of AML is often possible due to gross fat inside

the tumor. Fat is hyperechoic in ultrasound and shows negative Hounsfield unit (HU) density (-15 to -20 HU) in non-enhanced computed tomography (CT) (1). Though there are different subtypes of AML described along with rare reports of calcification inside AMLs, bone formation by osseous metaplasia in AML has not been reported so far in literature. We report the case of an ossifying AML, treated in our centre.

CASE REPORT

A 63-year-old man with vague abdominal pain of nearly one year and having no co-morbid diseases was found to have a right renal hyperechoic mass measuring 9 cm x 5 cm x 6 cm in abdominal ultrasound and was referred to the Urology department. The patient gave history of having detected an incidental renal mass on the right side more than 20 years back with no follow up ever since. A contrast enhanced CT revealed an extensively calcified mass measuring 8.8 cm x 4.9 cm x 6.7 cm occupying mid and lower part of right kidney abutting the hilar structures. The CT density of the mass ranged from 1325 HU at calcified areas to -14 HU at low density areas suggestive of macroscopic fat. Most of the tumor space was calcified leaving strips of soft tissue areas with fat attenuation and very little post contrast enhancement (Fig.1).

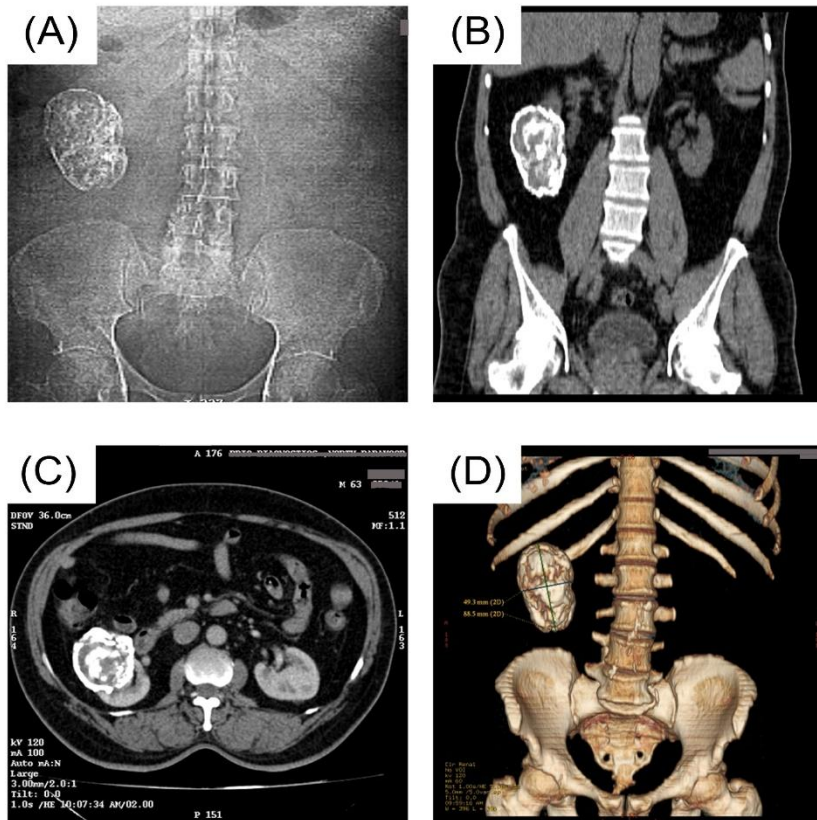


Figure 1: Panel A-CT topogram showing radio opaque right renal mass, Panel B,C-CT sections showing right renal mass with extensive calcification, Panel D-reconstructed CT image of the tumor

The CT features were suggestive of a large renal mass with extensive intra tumoral calcification and fat containing areas, suggestive of renal cell carcinoma or a variant of renal AML. Due to the proximity of tumor to the renal hilar structures, open right radical nephrectomy was performed. On intraoperative examination, the large, heavy mass replaced the mid and upper portions of the kidney which was bony hard on palpation, reaching upto the renal hilum, abutting renal artery, vein, and renal pelvis. There was no hilar, caval or para-aortic lymphadenopathy. The post-operative recovery of the patient was uneventful. At the pathology lab, three continuous days of hydrochloric acid-decalcification was required for sectioning the specimen due to the abnormal high content of calcium in the tumor. Upon bisection, the mass revealed hard

cortical bone constituting most of the areas, leaving islands of yellow-brown soft areas (Fig.2).




Figure 2: Gross section of the renal mass showing bony tissue occupying most of the tumor with islands of soft areas

Histology showed bone tissue with lamellar bone formation and trabeculae at the hard areas and triphasic histology composed of mature adipocytes, dysmorphic blood vessels, and smooth muscle elements at the soft areas, suggesting the tumor to be a variant of AML with osseous metaplasia (Fig.3).

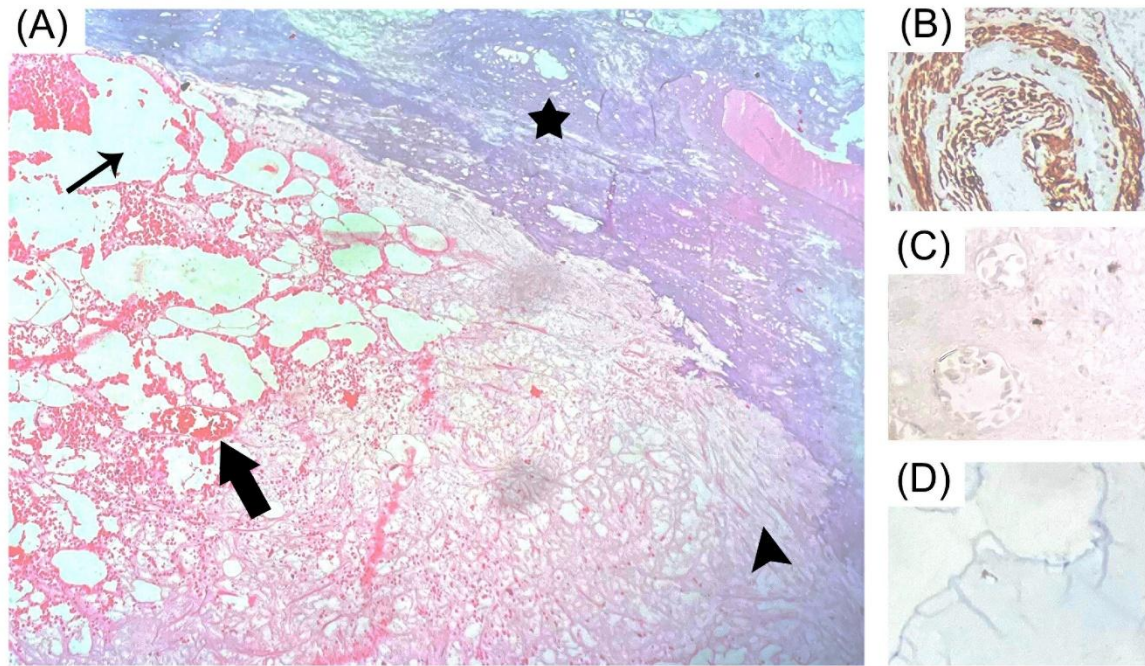


Figure 3: Panel A- H&E staining shows blood vessels (thick arrow), smooth muscle elements (arrowhead) and adipocytes (thin arrow). Marked area (star) shows osseous metaplasia. IHC staining in: Panel B- positive SMA, Panel C- negative CK, Panel D- negative S-100.

Immunohistochemistry showed SMA positivity for smooth muscle elements, negative Cytokeratin ruling out fat containing renal cell carcinoma (RCC) and negative and S-100, to exclude intra tumoral nerve sheath tumor such as schwannoma. Therefore, it was confirmed that the tumour was ossifying AML, which has not been reported in literature so far. The patient has been doing well during a follow up of one year.

DISCUSSION

AML is radiologically identified as a well circumscribed fat containing renal tumor without significant enhancement. The radiological subtypes of AML have been described as: 1, Classic AML; 2, Fat poor AML; 3, AML with epithelial cysts; 4, Epithelioid AML; 5, AML in tuberous

sclerosis; 6, AML in Lymphangio leiomyomatosis (2). Apart from these types, there are rare reports of AML with calcification. Many of the calcified sporadic AMLs have given diagnostic confusion because of resemblance to a calyceal stone(3) or a calcified RCC (4) during initial imaging. A renal tumor with co-existing calcification and fat has variable diagnoses depending on the proportion of each of these components and other tumor characteristics. Contrast-enhancing renal masses with extensive calcification and relatively smaller areas of fat are often RCCs with osseous metaplasia and the fat is derived from marrow elements of osseous metaplasia (5) (6) (7) (8). Retroperitoneal tumors arising from perirenal areas such as liposarcomas and Schwannomas attain huge sizes, show characteristic CT hypodense areas, and can show calcification due to osseous metaplasia (9) (10). However, extensive tumor ossification has never been reported in AMLs. Ossification in a tumor is diagnosed based on CT density exceeding 700 HU (11), bone-like hardness upon palpation, the need for prolonged decalcification (7), and histology showing bony lamellae and trabeculae.

Pathologically, AML is regarded as a member of the Perivascular Epithelioid Cell tumors (PEComa) (12) based on the cell of origin. Histologically, AMLs are composed of predominantly spindle shaped epithelioid cells around thick-walled blood vessels with varying amounts of smooth muscle and mature adipocytes without atypia. The classic AML is also called triphasic tumor. Spindle cells have melanocytic features and therefore stains positively with HMB-45 and Melan-A. Smooth muscle cells shows SMA positivity. SMA positivity also rules out liposarcoma and oncocytoma. Important negative markers include Cytokeratin to rule out RCC and S-100 to rule out intrarenal schwannomas (13).

CONCLUSION

Osseous metaplasia is extremely rare among renal tumors, posing challenges for imagological diagnosis and performing surgery. A long history of the tumor in this patient is indicative of indolent nature of the AML, however we are unaware of the length of metaplastic transformation. A benign renal tumor with bone formation is further evaluated with immunohistochemistry for confirmation of histology and to rule out other renal malignancies capable of osseous metaplasia. This is the first report of ossification occurring in renal AML. Even though many subtypes of AML exist, we suggest that ossified AML may also be considered a rarer variant of the entity.

CONSENT

A written informed consent has been obtained from the patient for collection of data and publication of the case report

ETHICAL APPROVAL

Ethical approval for case reporting has been obtained from the Institutional ethical committee.

References

1. Parker W P, Gettman M T. Benign Renal Tumors. A.W.Partin (Ed.). Campbell-Walsh-Wein Urology. Philadelphia: Elsevier; 2021.
2. Masahiro Jinzaki, Stuart G. Silverman, Hirotaka Akita, Yoji Nagashima, Shuji Mikami, Mototsugu Oya. Renal angiomyolipoma: a radiological classification and update on recent developments in diagnosis and management. *Abdominal Imaging*. 2014; 39: 588–604.
3. Low E, Tan CH, Ho B, Chong S. Minimal fat renal angiomyolipoma with central scar and stellate calcification mimicking a calyceal calculus. *Singapore Med J*. 2013 Nov;54(11):e221-3. doi: 10.11622/smedj.2013231. PMID: 24276108. .
4. Merran S, Vieillefond A, Peyromaure M, Dupuy C. Renal angiomyolipoma with calcification: CT-pathology correlation. *Br J Radiol*. 2004 Sep;77(921):782-3. doi:

- 10.1259/bjr/33776173. PMID: 15447968. .
5. Cribbs RK, Ishaq M, Arnold M, O'Brien J, Lamb J, Frankel WL. Renal cell carcinoma with massive osseous metaplasia and bone marrow elements. *Ann Diagn Pathol.* 1999 Oct;3(5):294-9. doi: 10.1016/s1092-9134(99)80025-2. PMID: 10556476. .
 6. Pan H, Wu D, Wang H, Pan Y, Zhang T, Zhou J. Clear Cell Renal Cell Carcinoma With Extensive Osseous Metaplasia: Report of a Rare Case. *Urology.* 2017 Jul;105:e3-e5. doi: 10.1016/j.urology.2017.02.048. Epub 2017 Mar 22. PMID: 28342931. .
 7. Sostre G, Johnson JF 3rd, Cho M. Ossifying renal cell carcinoma. *Pediatr Radiol.* 1998 Jun;28(6):458-60. doi: 10.1007/s002470050382. PMID: 9634462. .
 8. Agarwal S, Bohara S, Jha R, Khurana N, Agarwal PN. Clear cell renal cell carcinoma with osseous metaplasia: Rare case report. *Journal of Cancer Research and Therapeutics.* 2015 Oct–Dec ; 11((4)): p 1039.
 9. Okuda I, Ubara Y, Okuda C, Fujii T, Suwabe T, Kokubo T, Nakajima Y, Hashimoto M. A large calcified retroperitoneal mass in a patient with chronic renal failure: liposarcoma with ossification. *Clin Exp Nephrol.* 2010 Apr; 14(2): 185-9.
 10. Xu SY, Sun K, Xie HY, Zhou L, Zheng SS, Wang WL. Hemorrhagic, calcified, and ossified benign retroperitoneal schwannoma: First case report. *Medicine (Baltimore).* 2016 Jul; 95(30): e4318.
 11. Freire V, Moser TP, Lepage-Saucier M. Radiological identification and analysis of soft tissue musculoskeletal calcifications. *Insights Imaging.* 2018 Aug;9(4):477-492. doi: 10.1007/s13244-018-0619-0. Epub 2018 Jun 7. PMID: 29882050; PMCID: PMC6108965. .
 12. Folpe AL. Neoplasms with perivascular epithelioid(PEComas). In Fletcher C, Unni KK, Mertens F. *Pathology and genetics of tumours of soft tissue and bone.* Lyon: ARC Press, pp 221–222; 2002. p. 221–2.
 13. Antic T. PathologyOutlines.com. [Online].; 2023 [cited 2023 Dec 01. Available from: <https://www.pathologyoutlines.com/topic/kidneytumorangiomyolipoma.html>.