

1
2
3
4
5
6

AGENESIS OF GALL BLADDER : A CASE REPORT

7
8

ABSTRACT

Background: Agenesis of the gall bladder is a rare condition, majority of which are usually diagnosed during intraoperative procedure because of low incidence of suspicion and high rate of false positive results for cholecystitis on ultrasound imaging.

Methodology: A 25 years old female patient presented with right upper quadrant pain, whose clinical features and abdominal ultrasound suggested chronic calculous cholecystitis. After pre-operative evaluation and preparation, she was planned for laparoscopic cholecystectomy.

Results: The patient underwent elective operative intervention on 17th June 2023. Intra-operatively, the liver and the extra-hepatic biliary tree were thoroughly inspected, but no gall bladder was detected anywhere in the undersurface of the liver. Decision was made to stop the procedure avoiding any further exploration thereof. Post-operatively the patient was subjected to magnetic resonance cholangiopancreatography (MRCP), which confirmed agenesis of gall bladder.

Conclusion: The accuracy of abdominal ultra-sonography (USG) in the diagnosis of gall bladder disease is only 95% and a second USG screening or MRCP has got a definite role to play in doubtful cases.

9
10
11
12
13

Keywords: Agenesis, Gall bladder, MRCP

14
15

1. INTRODUCTION

16
17
18
19
20
21
22
23
24
25
26
27
28
29
30

“Developmental abnormalities of the gall bladder are relatively rare. Agenesis of gall bladder is three times more common in females than males”^(1,2). “Patients typically present with symptoms akin to biliary colic or cholecystitis with symptoms such as dyspepsia, abdominal pain, nausea, vomiting, intolerance to fatty food and so on”^(1,3). “Most cases are sporadic (around 70%) and there is very little literature on familial links”⁽⁴⁾. “Since its first description by Lemery and Bergman in 1701 and 1702 respectively, a number of cases have been published, with a reported incidence of 0.01 to 0.06%”⁽⁵⁾. “Combined with the rarity of the condition, the diagnosis of cholecystitis is infrequently made. Upper abdominal ultrasonography is a first line imaging for the diagnosis of cholelithiasis with a sensitivity of 97%, but in gall bladder agenesis, the sensitivity decreases to 61%, and erroneous report of cholelithiasis or shrunken gall bladder suggestive of chronic cholecystitis is often made”^(2,7) “Due to these misinterpreted reports patients undergo unnecessary surgery and may encounter iatrogenic biliary tract injuries and portal injuries, due to excessive dissection to find out the absent gall bladder”⁽⁸⁾. “Sometimes conversion to open exploration is made. Preoperative magnetic resonance cholangiopancreatography (MRCP) and endoscopic ultrasound (EUS) should be considered. And when such condition is encountered intraoperatively, intraoperative cholangiography and intraoperative ultrasound can be done to rule out agenesis and ectopic gall bladder”⁽⁹⁾.

31
32

2. CASE REPORT

33
34
35
36
37

A 25-year-old female presented to the hospital with history of right upper abdominal pain and vomiting which was on and off since 2 years. She was otherwise fit and healthy. In the out patient department (OPD), she presented with right upper abdominal pain associated with on and off episodes of vomiting. Her blood tests showed normal liver function tests (LFTs). She had undergone an ultrasonography (USG) of the whole abdomen which gave an impression of a contracted gallbladder. There was no definite wall hyperaemia and probe tenderness was present. She was diagnosed

with acute on chronic cholecystitis and antibiotics were commenced. Symptoms improved so she was subsequently discharged with plan for an elective laparoscopic cholecystectomy after 4 weeks of discharge.

After 4 weeks a repeat USG was done which confirmed chronic calculous cholecystitis with a 1 cm stone. An elective laparoscopic cholecystectomy was planned. Intraoperatively, the gallbladder was not seen. The examination of right and left subhepatic space, and portal region was done. The anatomy looked unremarkable other than the absence of a gallbladder. A second opinion was taken from another senior surgeon who agreed with the findings and the procedure was converted to open cholecystectomy to exclude any ectopic position of the gall bladder. Even after opening the abdomen, the gall bladder was neither seen nor any stone was felt and hence the intended operation was abandoned.

The patient was discharged home on recovery and was planned for an outpatient MRCP and repeat LFT. On MRCP no gallbladder or cystic duct was identified and was consistent with a diagnosis of a congenital agenesis. Common bile duct (CBD) was normal with no evidence of biliary stricture or choledocholithiasis. The repeat LFT was normal. She was reviewed in outpatients following these investigations. She remained well postoperatively with no further symptoms. She was discharged with surgical follow-up.

3. DISCUSSION

“The liver and gall bladder develop in the fourth week of intrauterine life”⁽¹⁰⁾. “The gall bladder originates from the cystic bud as a ventral outgrowth from the caudal region of the foregut. The vacuolation of hyperplastic epithelium starts at about the seventh week during which the gall bladder and cystic duct develop a lumen”⁽¹¹⁾. “Though the exact pathogenesis is unknown, gall bladder agenesis is thought to be due to the failure of the cystic bud to develop further or to the failure of vacuolation”⁽¹⁰⁾.

Kabiri H et al in their study suggested that “gall bladder agenesis is a rare congenital anomaly characterized by the absence of the gall bladder in conjunction with a normal bile duct system”. “The prevalence range is 0.007 to 0.13 % with an incidence of 0.007 to 0.027% in surgical cases and 0.04 to 0.13% in autopsy reports”⁽¹²⁾.

Bennion RS et al and Gilbert Scott F explained the agenesis of gall bladder by two developmental theories^(11,13):

1. Failure of hepatic diverticula to develop into gall bladder
2. Failure of recanalization of cystic duct and gall bladder.

According to Winter RB et al agenesis of gall bladder may present as⁽¹⁴⁾:

1. Neonates with multiple fetal anomalies (15 – 16%): in these patients, agenesis usually diagnosed on autopsy because of death in perinatal period due to associated GIT, GUT, CVS anomalies.
2. Asymptomatic (35%): in these patients, agenesis recognized at autopsy and during laparotomy for other cause.
3. Symptomatic (40 – 60%): In these patients agenesis is discovered on USG abdomen, MRCP, EUS, and during laparoscopy for evaluation of (colicky) pain in right hypochondrium (90%), dyspepsia, vomiting.

“Agenesis of gall bladder is associated with congenital syndromes such as cerebrotendinous xanthomatosis, G-syndrome, Klippel-Feil syndrome, trisomy 18 and some cases reported after thalidomide therapy”^(5,15,16,17).

“When a patient presents with symptoms of biliary colic or upper abdominal pain, the first investigation of choice would be an abdominal ultrasonography. In order to allow the gall bladder to distend and to reduce the amount of gas present in the bowel and assist in distinguishing bowel loops from an absent gallbladder, the ultrasonography should be performed after fasting. The “WES” triad (wall-echo-shadow sign - demonstration of gallbladder Wall, Echo of stone, and acoustic Shadow) has been proposed to differentiate between a contracted gallbladder with gallstones and bowel loops”^(11,18).

Latimer EO et al said that “MRCP and Endoscopic Retrograde Cholangiopancreatography (ERCP) provide excellent alternatives to open exploration and intra-operative cholangiography”⁽¹⁹⁾. “Though ERCP contributes little in diagnosis of agenesis because non-visualization of gall bladder is interpreted as cystic duct obstruction”⁽²⁰⁾. “If the diagnosis is made pre-operatively or the symptoms continue postoperatively, a possible conservative treatment for this symptomatic group includes smooth muscle relaxants, and if this fails, sphincterotomy”⁽¹⁹⁾.

“Preoperative MRCP should be considered in cases of USG diagnosis of non-visualization of gallbladder”⁽⁷⁾. “Other diagnostic modality includes EUS, intra-op ultrasound and selective arteriography can be used for agenesis. But their availability is less”⁽²⁰⁾. “There were some cases reported in which the agenesis of gall bladder was diagnosed preoperatively and the operation was avoided”⁽²¹⁾. Malde S et al suggested “a decisional tree for the investigation of suspected gallbladder agenesis in an attempt to identify this rare condition pre-operatively, thereby preventing the unnecessary operative intervention as was seen in this case”⁽²⁰⁾.

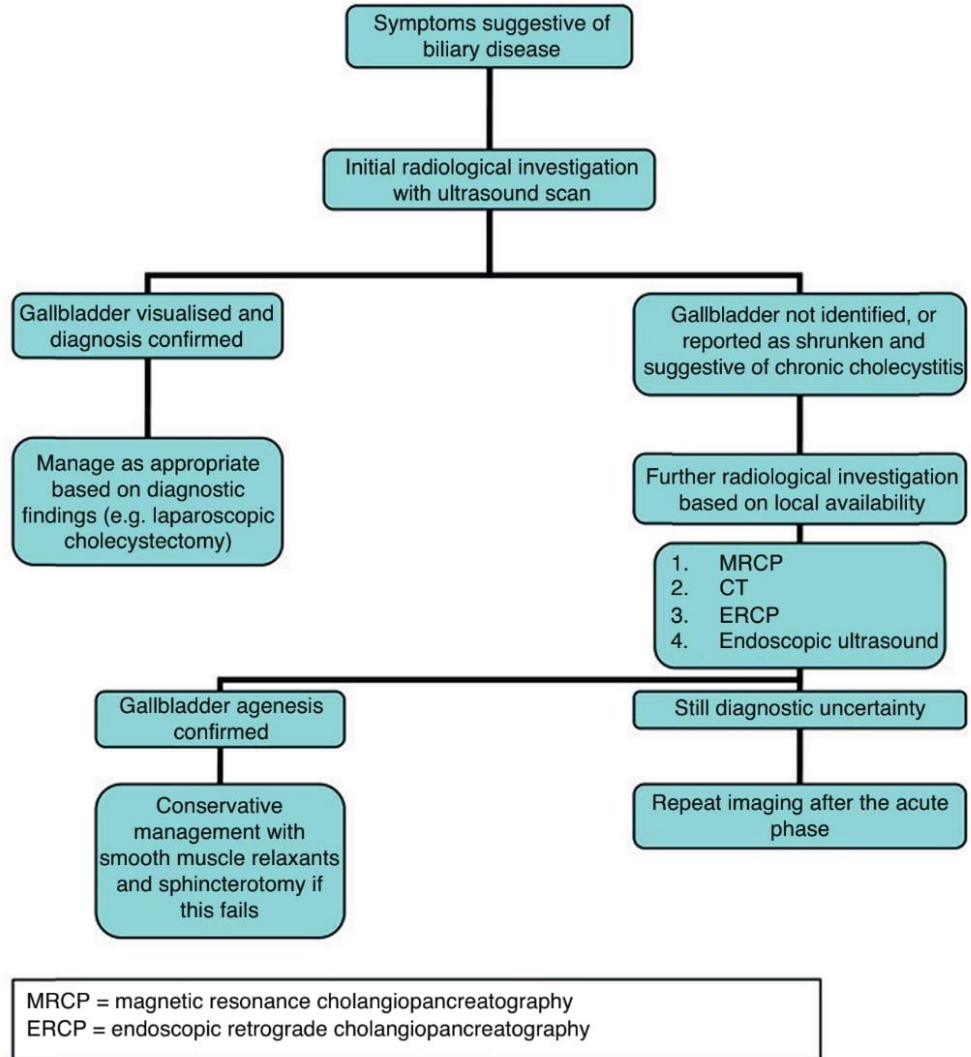


FIG 1: Symptoms suggestive of biliary disease

4. CONCLUSION

When non-visualization of gallbladder is present during laparoscopy or open exploration intra-operative cholangiogram, intraoperative ultrasound and postoperative MRCP or endoscopic ultrasonography (EUS) can help in the confirmation of agenesis or ectopic gallbladder.

CONSENT

As per university standard patient written consent has been collected and preserved by the author(s).

ETHICAL APPROVAL

As per international standards or university standards written ethical approval has been collected and preserved by the author(s).

REFERENCES

1. Cinalli M, Di Russo S, Panaccio P, Casolino V, D’Arcangelo M, Mucilli F, et al. A case report on gallbladder agenesis: not a novelty but still a laparoscopic surprise. Cureus 2021;13: e20401

- 118 2. Pipia I, Kenchadze G, Demetrashvili Z, Nemsadze G, Jamburia L, Zamtaradze T, et al. Gallbladder agenesis: a case
119 report and review of the literature. *Int J Surg Case Rep* 2018;53:235–7.
- 120 3. Tsalikidis C, Gaitanidis A, Kavazis C, et al.: A case of symptomatic gallbladder agenesis with chronic abdominal
121 symptoms. *Folia Med (Plovdiv)*. 2020, 62:615-8. 10.3897/folmed.62.e48291
- 122 4. Kasi PM, Ramirez R, Rogal SS, Littleton K, Fasanella KE. Gallbladder agenesis. *Case Rep Gastroenterol* 2011;5:654–
123 62
- 124 5. Cabajo CM, Martin del Olmo JC, Blanco AJ, Atienza SR. Gallbladder and cystic duct absence: an infrequent
125 malformation in laparoscopic surgery. *SurgEndosc*. 1997;11:483---4, <http://dx.doi.org/10.1007/s004649900397>
- 126 6. Kwon AH, Yanagimoto H, Matsui Y, Imamura A. Aggenesis of the gallbladder with hypoplastic cystic duct diagnosed
127 at laparoscopy. *SurgLaparoscEndoscPercutan Tech*. 2006;16:251---4.
- 128 7. Piltcher-da-Silva R, Sasaki VL, Felisberto DEG, Bodanese BCS, Piltcher-Recuero M, Bodanese BVS, et al.
129 Gallbladder agenesis a rare and underdiagnosed congenital anomaly: a case report and literature review. *J Surg*
130 *Case Rep* 2022;2022:rjac505
- 131 8. Wilson JE, Deitrick JE. Aggenesis of the gallbladder: case report and familial investigation. *Surgery* 1986
132 Jan;99(1):106–9
- 133 9. Gotohda N, Itano S, Horiki S, et al. Gallbladder agenesis with no other biliary tract abnormality: Report of a case
134 and review of the literature. *J Hepatobiliary PancreatSurg* 2000;7(3):327–30.
- 135 10. Bianco G, Frongillo F, Agnes S, Nure E, Silvestrini N: Gallbladder agenesis: a case report and brief review. *Ann*
136 *Hepatobiliary Pancreat Surg*. 2018, 22:292-5. 10.14701/ahbps.2018.22.3.292
- 137 11. Bennion RS, Thompson JE, Tompkin RK. Aggenesis of the gallbladder without extrahepatic biliary atresia. *Arch*
138 *Surg*. 1988;123:1257---60.
- 139 12. Kabiri H, Domingo OH, Tzarnas CD. Aggenesis of the gallbladder. *Curr Surg*. 2006;63:104---6, [http://dx.doi.org/](http://dx.doi.org/10.1016/j.cursur.2005.04.018)
140 [10.1016/j.cursur.2005.04.018](http://dx.doi.org/10.1016/j.cursur.2005.04.018).
- 141 13. Gilbert Scott F. *Developmental Biology*. 5th Ed. Sunderland (MA): Sinauer Associates Inc 1997;9:382– 3.
- 142 14. Winter RB, Baraitser M. *Multiple congenital anomalies. A diagnostic compendium*. First Ed Cambridge: Chapman
143 and Hall Medical 1991;109.
- 144 15. Turkel SB, Swanson V, Chandrasoma P. Manifestations associated with congenital absence of the gallbladder. *J*
145 *Med Genet* 1983 Dec;20(6):445–9.
- 146 16. Sterchi JM, Baine RW, Myers RT. Aggenesis of the gallbladder - an inherited defect? *South Med J* 1977
147 Apr;70(4):498–9.
- 148 17. Kreipe U. Abnormalities of internal organs in thalidomide embryopathy. A contribution to the determination of
149 the sen-sitivity phase in thalidomide administration during early pregnancy. *Arch Kinderheilkd* 1967
150 Aug;176(1):33–61. [Article in German].
- 151 18. Fiaschetti V, Calabrese G, Viarani S, Bazzocchi G, Simonetti G: Gallbladder agenesis and cystic duct absence in
152 an adult patient diagnosed by magnetic resonance cholangiography: report of a case and review of the literature.
153 *Case Rep Med*. 2009, 2009:674768. 10.1155/2009/674768
- 154 19. Latimer EO, Mendez FL Jr, Hage WJ. Congenital absence of gallbladder: Report of three cases. *Ann Surg* 1947
155 Aug;126(2):229–42.
- 156 20. Malde S. Gallbladder agenesis diagnosed intraoperatively: A case report. *J Medical Case Reports* 2010;4:285
- 157 21. Peloponissios N, Gillet M, Cavin R, Halkic N. Aggenesis of the gallbladder: A dangerously misdiagnosed
158 malformation. *World J Gastroenterol* 2005 Oct 21;11(39):6228–31.