

# **BILATERAL PRERETINAL HEMORRHAGE AFTER BLOOD TRANSFUSION FROM A GIRL MANAGED WITH RHABDOMYOSARCOMA: CASE REPORT AND REVIEW OF THE LITERATURE**

## **ABSTRACT**

**Objective:** To describe a case of bilateral preretinal hemorrhage after a medina blood transfusion followed by rhabdomyosarcoma

**Results:** This is a female patient, 21 years old, of rural origin, with a pathological history of rhabdomyosarcoma 8 years ago, she was seen in the emergency department of the aforementioned hospital with anemia of 4 hemoglobin and a bag of whole blood, a The day after a blood transfusion she developed a subconjunctival hemorrhage in her right eye. She was accompanied by her family to our ophthalmology emergency department, where she was seen at our service. According to the girl's ophthalmological examination, the girl's visual acuity without optical correction was 09/10 in the right eye and 10/10 in the left eye, annexes: eyelids without ptosis but with eyelid retraction, there was subconjunctival hemorrhage, preserved ocular motility, unilateral exophthalmia, without pain, non-reducible in the right eye, anterior segment without particularity, fundus of the eye presents spots of pre-retinal hemorrhage in multiple, very limited form with good macular reflex, and left eye: adnexa and anterior segment without particularity, fundus of the eye presents multiple stains Well-limited round preretinal hemorrhages located in the posterior pole and periphery. The pre-retinal hemorrhage of the girl with anemia after blood transfusion resolved without medical treatment, we advised the girl to drink more water than before and we monitored it every month and after three months it resolved with a favorable evolution.

**KEYWORDS:** hemorrhage, subconjunctival, retinal, rhabdomyosarcoma, blood transfusion

## **INTRODUCTION**

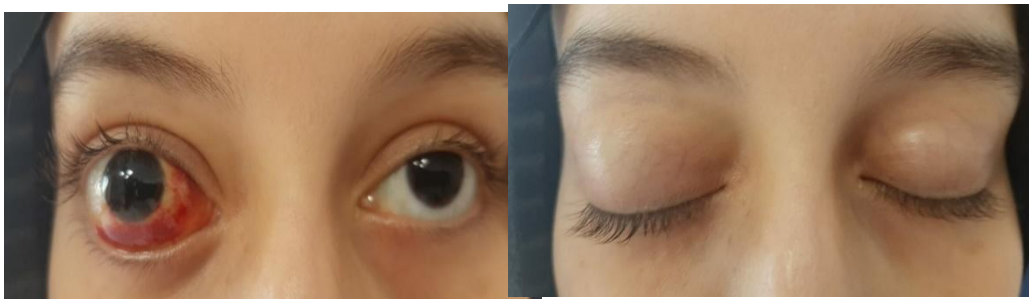Preretinal hemorrhages may be located below the internal limiting membrane, or between it and the posterior hyaloid. They generally have a circumscribed and elevated appearance, rounded in shape or sometimes delimiting a level, and the accumulated blood is bright red. When they occupy the foveal area, they cause significant visual loss due to a screen effect on the retina. Although they can resolve spontaneously, they sometimes require some type of treatment. Rhabdomyosarcoma (RMS) is a highly malignant tumor whose tissue of origin is the pluripotent mesenchyme. Orbital RMS is

one of the few life-threatening diseases that first present to the ophthalmologist; therefore, prompt diagnosis and treatment is a life-saving issue. In this case, the pre-retinal hemorrhage resolved without medical treatment with our guidance and follow-up after three months.

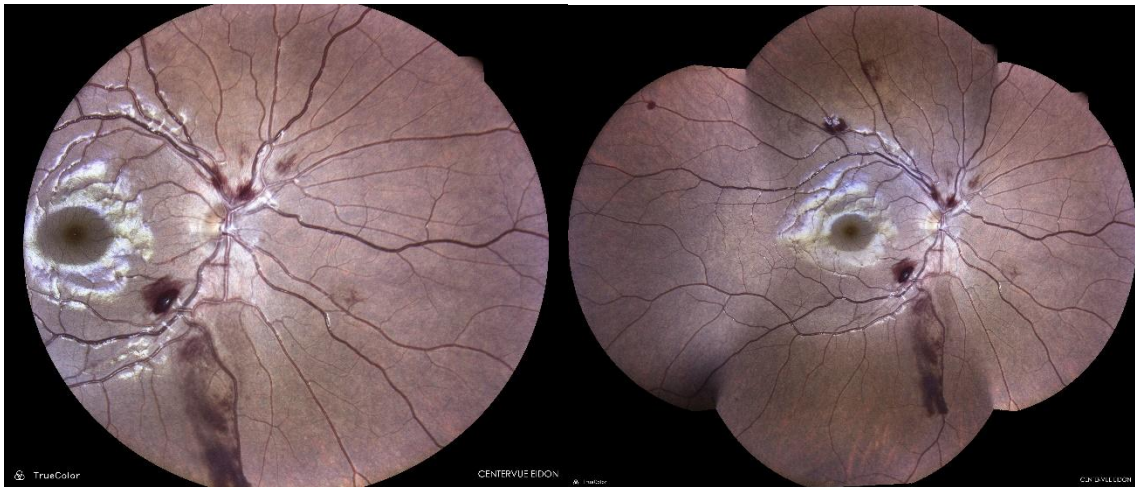#### CASE PRESENTATION

This is a female patient, 21 years old, of rural origin, with a pathological history of rhabdomyosarcoma 8 years ago. anemia of 4 hemoglobin and a bag of whole blood was transfused, one day after the blood transfusion she presented sub-conjunctival hemorrhage in the right eye, she was accompanied with her family to our ophthalmology emergency where she was seen in our service. According to the girl's ophthalmological examination, the girl's visual acuity without optical correction was 09/10 in the right eye and 10/10 in the left eye, annexes: eyelids without ptosis but with eyelid retraction, there was subconjunctival hemorrhage, preserved ocular motility, unilateral exophthamia, without pain, non-reducible in the right eye, anterior segment without particularity, fundus of the eye presents spots of pre-retinal hemorrhage in multiple, very limited form with good macular reflex, and left eye: adnexa and anterior segment without particularity, fundus of the eye presents multiple stains very limited round pre-retinal hemorrhages located in the posterior pole and periphery, complementary exams requested are: face photo shows exophthamia in the left eye and subconjunctival hemorrhage and photo of normal left eye (figure 1), ethnography shows spots of subretinal hemorrhage (figure 2 and 3 ) and fluorescent angiography shows hypofluorescence in areas of hemorrhage spots (figure 4 ) and normal macular OCT (figure 5)

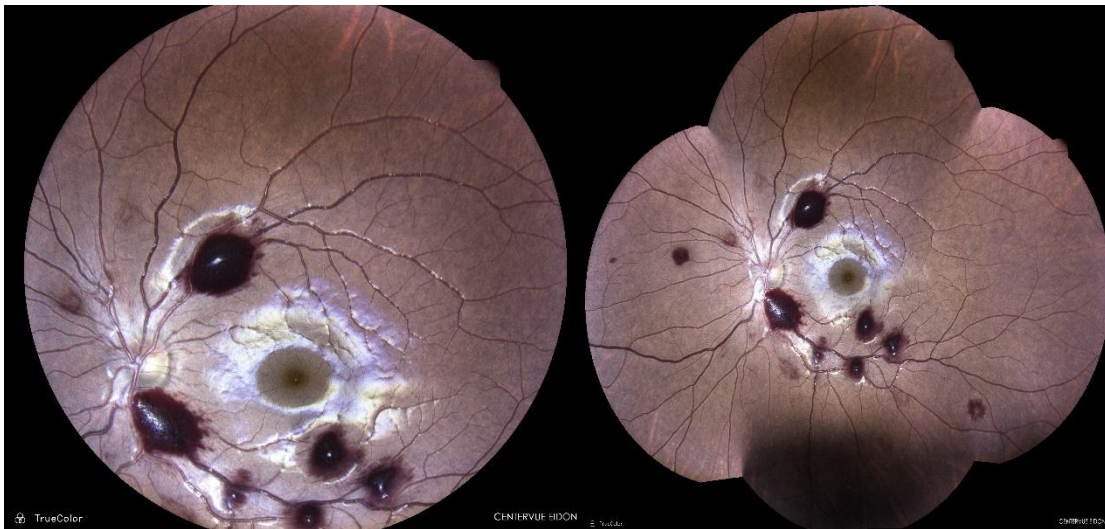**Figure 1** . image shows exophthalmos in the left eye and subconjunctival hemorrhage



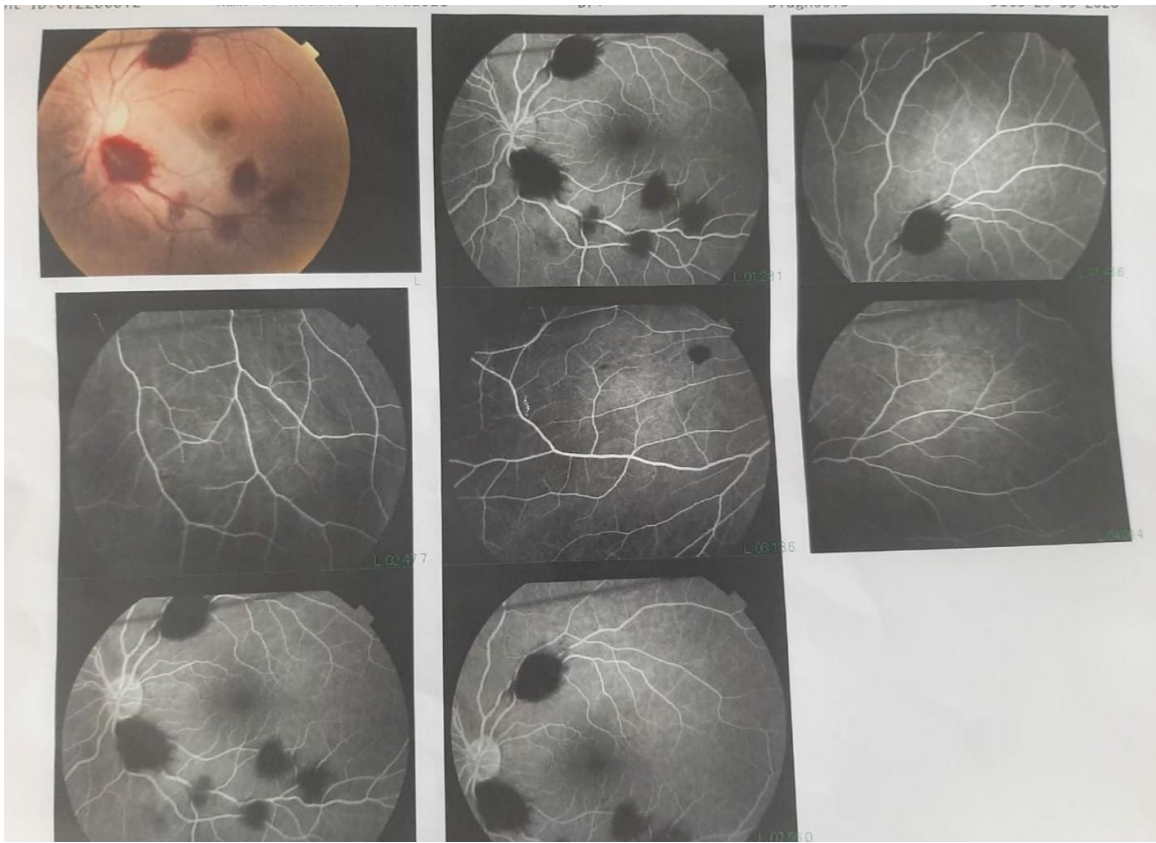
**Figure 2.** retinography shows preretinal hemorrhage spots in the right eye



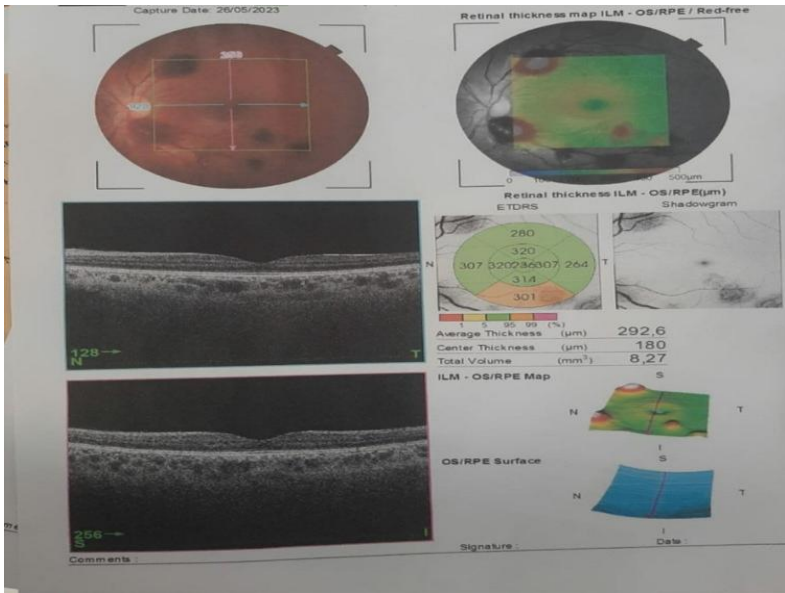
**Figure 3.** retinography shows multiple well-limited round preretinal hemorrhagic spots located in the posterior pole and periphery of the left eye



**Figure 4.** Fluorescent angiography shows hypofluorescence in areas of hemorrhage spots



**Figure 5. Normal macular OCT**



## DISCUSSION

Preretinal hemorrhage occurs in the context of a variety of ocular and systemic conditions. The presence of preretinal blood causes damage to the retina through: direct iron toxicity, and retinal disruption due to clot retraction. Likewise, the final visual prognosis is determined by other variables, such as: the size of the hemorrhage, the length of time the blood remains and the etiology, the most important prognostic factor, with hemorrhages caused by coagulation disorder following blood transfusion with good prognosis.

Metastatic spread of orbital RMS is uncommon, however, if left untreated, RMS has a propensity to metastasize to the lung, bone, and bone marrow, primarily through hematogenous spread. The mass is usually close to the extraocular muscles, but there is no enlargement of the muscle belly. In the early stages the tumor is well circumscribed, but in the later stages, where there is pseudocapsular invasion, the edges are irregular. There may be some bone deformity, but frank bone destruction with bone involvement is rare, and the diagnosis is .

The treatment of the most diverse types of retinal hemorrhages must be carried out based on the severity and extent of each clinical case, as they often have the ability to resolve themselves without the need for medical intervention. However, in more serious clinical cases, the patient must undergo surgery with a trained and experienced ophthalmologist surgeon, in order to avoid any possibility of future complications, in addition to ensuring a better quality of life and comfort for the patient in question. . In our clinical case, the pre-retinal hemorrhage of a girl with anemia after a blood transfusion, but it resolved without medical treatment, just the guidance we advised the girl to drink more water than before and we monitored it every month and after three months it resolved with good favorable evolution.

## CONCLUSION

In most cases, pre-retinal hemorrhages resolve spontaneously; this improvement process can take weeks or months and may result in permanent visual impairment due to the toxicity produced by blood contact with the retina.

Orbital RMS is one of the few life-threatening diseases that first presents to an ophthalmologist; therefore, prompt diagnosis and treatment is a life-saving issue.

Always remember the importance of consulting and using a good ophthalmologist. From the first sign of discomfort and changes in your usual vision, consult your doctor in order to avoid future complications and ensure good eyehealth.

## Consent

As per international standards or university standards, patient(s) written consent has been collected and preserved by the author(s).

## REFERÊNCIAS

1. De Maeyer K, Van Ginderdeuren R, Postelmans L, Stalmans P, Van Calster J. Sub-inner limiting membrane haemorrhage: causes and treatment with vitrectomy. *Br J Ophthalmol.* 2007;91(7):869-72.
2. Lavezzo MM, Zacharias LC, Takahashi WY. Internal limiting submembrane hemorrhage in a patient after Valsalva: case report. *Arq Bras Oftalmol.* 2012;75(6):436-8.
3. Moreira Jr CA, Vianello SMP, Cardillo JA. Valsalva retinopathy: to intervene or not? Case report with OCT evaluation. *e-Oftalmo.CBO: Rev Dig Oftalmol.* 2015;1(1):1-2.
4. BARTHELMES, Daniel; BOSCH, Martina; MERZ, Tobias, et. al. Delayed appearance of high altitude retinal hemorrhages. *PLoS One, Zurich*, v. 6, n. 2, e11532. Fev. 2011.
5. CHEN, Feng; CHENG, Dan; PAN, Jiandong, et. al. The efficacy and safety of Retcam in detecting neonatal retinal hemorrhages. *BMC ophthalmology, Zhejiang*, v. 18, n. 1, p. 202. Ago. 2018.
6. CHLEBICKI, Maciej; ANG, Brenda; BARKHAM, Timothy, et. al. Retinal Hemorrhages in 4 Pacientes with Dengue Fever. *Emerg Infect Dis, Singapore*, v. 11, n. 5, p. 770-772. Maio 2005.
7. KAUR, B.; TAYLOR, D. Retinal haemorrhages. *Archives of disease in childhood, Londres*, v. 65, n. 12, p. 1369-1372. Dez. 1990.
8. Rootman J., editor. *Neoplasia*. Vol. 54. Lippincott Williams and Wilkins; Philadelphia: 2003. pp. 262–268. (Diseases of the orbit: a multidisciplinary approach).
9. Shields J.A., Shields C.L. Rhabdomyosarcoma: review for the ophthalmologist. *Surv Ophthalmol.* 2003;48:39–57.
10. Turner J.H., Richmon J.D. Head and neck rhabdomyosarcoma: a critical analysis of population-based incidence and survival data. *Otolaryngol Head Neck Surg.* 2011; 145:967–973.

