

Moving Forward in Low Resource Setting, Southern Nigeria: The Benefit of Otoscopy

ABSTRACT

Introduction: Otological conditions abound in the society. Many individuals both in rural and urban communities are unreached while some are unreachable. Most of these individuals are not aware of specialist care. Those aware do not know what to do and how to go about their problems, justifying this study.

Aim: The aim of this study was to identify common otological conditions and asymptomatic otological conditions; and to proffer solutions to identified conditions in rural and urban settings in Edo and Ondo states respectively.

Methodology: This study is a 3- year prospective comparative study done in Edo State and Ondo State, from December 2019 to March 2022. It commenced after due ethical considerations, informed consent and permissions. Study centres were St. Matthias Catholic Church, Ologbo and Egbaen Community in Edo State; Oba Osemawe Palace and Kaftan TV in Ondo state, both in southern Nigeria. Total population study technique was used. Sample size was determined using Cochran formula. One hundred and forty- two individuals participated. Health education was given, a brief history was taken, thereafter, otoscopy was done. Each ear was considered a separate entity, giving a total of two hundred and eighty- four (284) ears examined. Data realized were statistically analyzed using SPSS Version 23. P value < 0.05 was considered statistically significant. Pathologies identified were treated accordingly.

Result: Age ranged from 1 to 95 years. 84 females and 58 males participated. F:M = 1.4:1. Commonest otological condition was otitis media with effusion (17.96%) in both settings.

Among the least were Complicated Chronic Suppurative Otitis Media, Otomycosis and Tympanic Membrane Perforation.

Predominant asymptomatic condition was Cerumen Auris (7.39%), least was foreign bodies (1.06%). Correlation between rural and urban findings were statistically significant ($p < 0.05$).

Conclusion: Otologic conditions are common in both rural and urban settings including asymptomatic presentations.

Much can be achieved with simple instrument (otoscope). Hence, a call for researchers to begin with simple tools available. Don't wait for sophisticated instruments.

Key words: *Moving Forward, Low Resource Setting, Benefit, Otoscopy*

INTRODUCTION

Majority of the previous studies were on either children, Adults or Specific groups such as sickle cell patients and cerebral palsy.¹ These studies were mostly hospital based.¹ But Otological conditions abound in the society in all age groups.² Many individuals both in rural and urban communities are **unreached** while some are **unreachable**.² Most of these individuals are not aware of specialist **health**care. Those aware do not know what to do and how to go about their problems, **justifying this study**.³ An earlier experience in which a 4-year old girl died from complications of Chronic suppurative otitis media exposed the ignorance of some members of the communities on ear hygiene. This child's mother, who is a petit trader, habitually cleans her ears with cotton buds and may have inadvertently ruptured the child's ear drums. The ear is naturally self-cleansing and does not need assisted cleaning. This paediatric patient **was** presented

with history of seizures and loss of consciousness following ear discharge. Further evaluation revealed cerebellar abscess of otogenic origin. This could have been averted if her parents were aware that they should not clean the ears. Furthermore it would have been prevented if there was an awareness outreach focused on Otoscopic examinations in that community.

In addition to the fore mentioned, a 3year old girl who was deaf mute and was seen as a social stigma to her family, gained speech after participating in an Otoscopic screening research study in Nigeria. This strengthens the benefit of otoscopy in low resource settings and calls for a forward movement in otological screening studies.⁴

AIM:

The aim of this study was to identify common otological conditions and asymptomatic otological conditions; and to profer solutions to the identified conditions in rural and urban setting in Edo and Ondo states respectively.

METHODOLOGY:

This study was a 3-year prospective comparative study in Edo State and Ondo State from December 2019 to March 2022. It commenced after obtaining due ethical considerations from Hope hospital, Costain road Benin City, informed consent from the participants and relatives of the participants who have not attained age of self-reasoning; and permission from the administrators of the study centres. Total population study technique was used. The Study centres were St Matthias Catholic Church, Ologbo and Egbaen Community in Edo State; Oba Osemawe Palace and Kaftan TV in Ondo state, both in southern Nigeria.

One hundred and forty- two (142) individuals participated. Health education was given on the aim and scope of the study and ear hygiene. There was a brief history-taking from each of the participants. Thereafter, Otoscopy was done. Each ear was considered as a separate entity, giving a total of two hundred and eighty- four (284) ears examined.

Data realized from the study were statistically analyzed using SPSS Version 21. P value < 0.05 was considered statistically significant. All pathologies identified were treated accordingly and the participants were referred to proximal centres with otorhinolaryngological facilities for follow up visits and further management.

RESULTS:

TABLE 1: AGE DISTRIBUTION

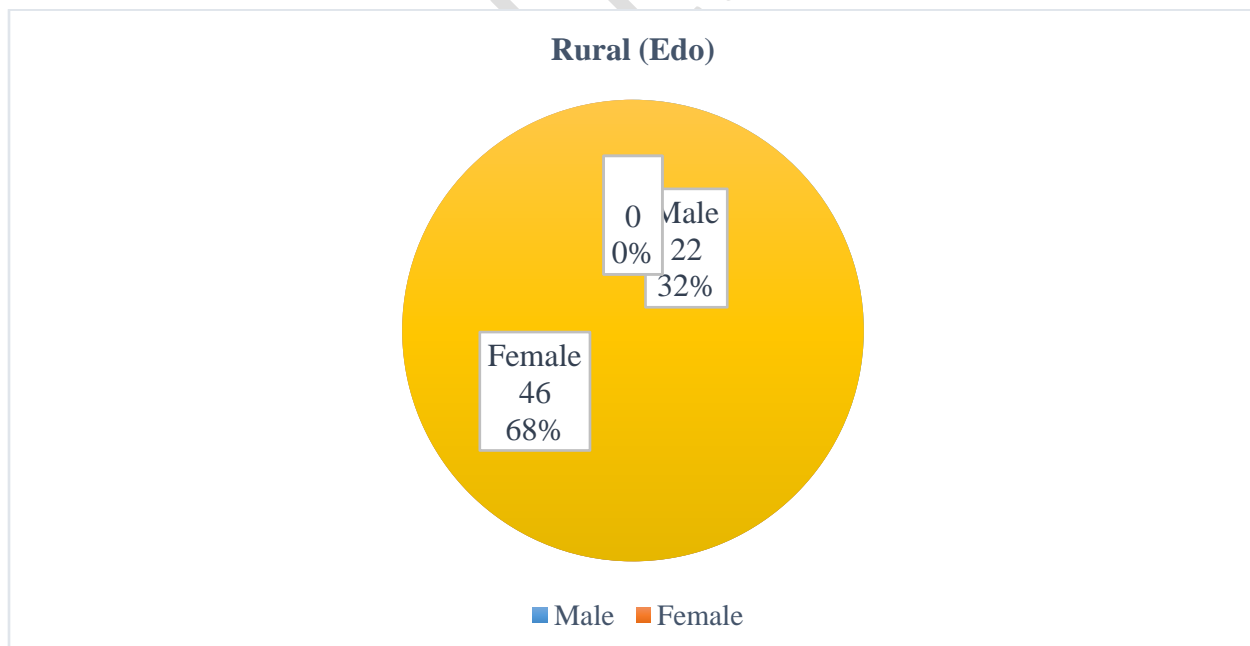
N = 142

AGE (Years)	Classification	RURAL	URBAN	Total
		(EDO)	(ONDO)	
		N (%)	N (%)	N (%)
0 – 10		6 (4.23)	0 (0.00)	6 (4.23)
11 – 20		5 (3.52)	14 (9.86)	19 (13.38)
21 – 30		2 (1.41)	33 (23.24)	35 (24.65)
31 – 40		8 (5.63)	20 (14.08)	28 (19.72)
41 – 50		22 (15.49)	1 (0.70)	23 (16.20)

51 – 60	16 (11.27)	1 (0.70)	17 (11.97)
61 – 70	7 (4.93)	2 (1.41)	9 (6.34)
71 – 80	1 (0.70)	2 (1.41)	3 (2.11)
81 – 90	0 (0.00)	1 (0.70)	1 (0.70)
91 – 100	1 (0.70)	0 (0.00)	1 (0.70)
Total	68 (47.89)	74 (52.11)	142 (100.00)

Mean age = 53.6 ± 14.49 yrs.

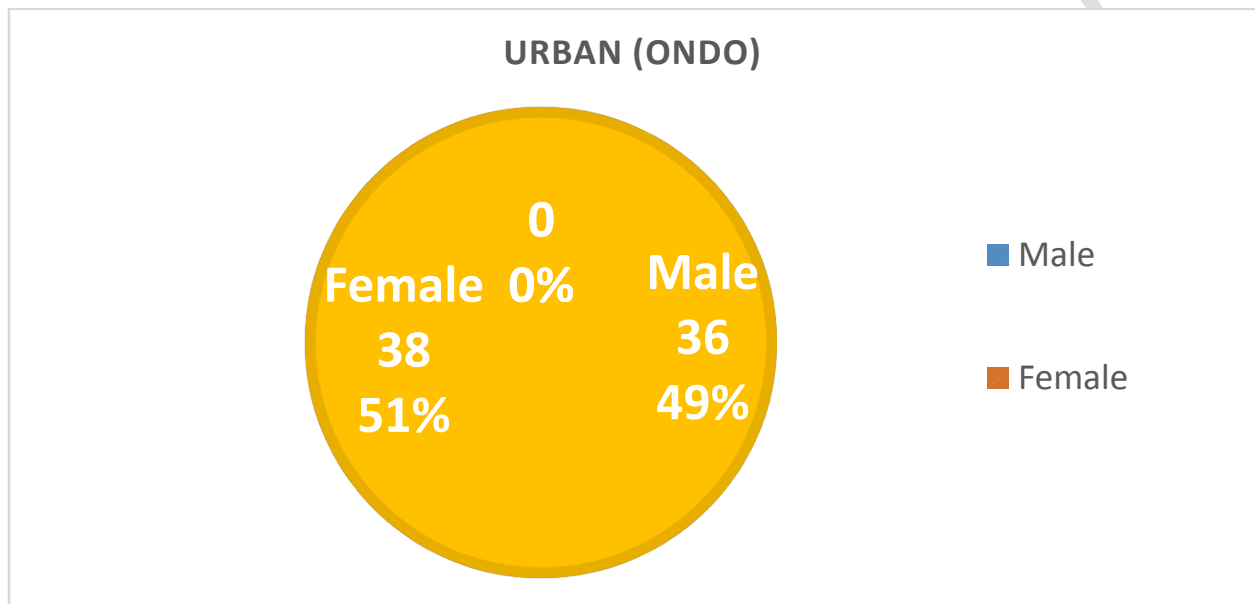
FIGURE 1: SEX DISTRIBUTION (N = 142) IN EDO STATE



M: F = 1: 2.1

FIGURE 2: SEX DISTRIBUTION IN ONDO STATE

N = 74



M: F = 1:1.1

UNDER P...

TABLE 2: OCCUPATION

OCCUPATION	Rural (Edo)	Urban (Ondo)	N (%)
Teachers	6 (4.23)	10 (7.04)	16 (11.26)
Journalists	3 (2.11)	16 (11.27)	19 (13.38)
Farmers	15 (10.56)	3 (2.11)	18 (12.68)
Traders	12 (8.45)	9 (6.34)	21 (14.79)
Self employed	10 (7.04)	11 (7.75)	21 (14.79)
Petit Trader	8 (0.06)	3 (2.11)	11 (7.75)
Business	5 (3.52)	12 (8.45)	17 (11.97)
Public servant	9 (6.34)	10 (7.04)	19 (13.38)
Total	68 (47.90)	74 (52.10)	142 (100.00)

TABLE 3: OTOSCOPIC FINDINGS IN THE STUDY POPULATION

OTOSCOPYY (N=284)	RURAL (EDO) N (%)	URBAN (ONDO) N (%)	TOTAL N (%)	DIAGNOSIS
Dull	51 (17.96)	51 (17.96)	102 (35.92)	OME
Shiny	34 (11.97)	41 (14.44)	75 (26.40)	Normal TM
Wax	35 (12.32)	28 (9.86)	63 (22.18)	Cerumen Auris
Debris	1 (0.35)	8 (2.82)	9 (3.17)	Otitis externa
Hyperemic	5 (17.60)	5 (17.60)	10 (3.52)	Otitis media
Otomycotic debris	1 (0.35)	3 (1.06)	4 (1.41)	Otomycosis
Foreign body	1 (0.35)	2 (0.70)	3 (1.06)	Foreign body in the ears
Hyphae	0 (0.00)	2 (0.70)	2 (0.70)	Otomycosis
TM perforation	4 (1.41)	2 (0.70)	6 (2.11)	TM perforation
Ear discharge	2 (0.70)	2 (0.70)	4 (1.41)	CSOM
Retracted	3 (1.06)	2 (0.70)	5 (17.60)	ETD
Inflamed/Hyperemic EAC	1 (0.35)	0 (0.00)	1 (0.35)	Diffuse Otitis Externa
Caked Pus	1 (0.35)	0 (0.00)	1 (0.35)	CSOM
Blood clot in edematous middle ear	1 (0.35)	0 (0.00)	1 (0.35)	CSOM

Facial palsy	1 (0.35)	0 (0.00)	1 (0.35)	Complicated CSOM
--------------	----------	----------	----------	------------------

Multiple findings

- Correlation between rural and urban Otoscopic findings were statistically significant (p<0.05).

TABLE 4: DESCRIPTIVE STATISTICS

	Mean	Std. Deviation	N
Rural	8.73	15.397	15
Urban	8.93	15.267	15

TABLE 5: CORRELATIONS

		Rural	Urban
Rural	Pearson Correlation	1	.974**
	Sig. (2-tailed)		.000
	N	15	15
Urban	Pearson Correlation	.974**	1
	Sig. (2-tailed)	.000	

N	15	15
---	----	----

** . Correlation is significant at the 0.01 level (2-tailed).

- The Table shows that Urban has a higher mean (8.93) than the Rural (8.73). Pearson correlation reveals that there is a correlation between Otoscopy and the location of cases ($r = 0.974$, $p < 0.05$)

TABLE 6: OTOSCOPIC DIAGNOSIS

S/N	Otologic pathologies identified	Rural (Edo)	Urban (Ondo)	Total
1	OME	51	51	102
2	Cerumen Auris	35	28	63
3	Otitis media	5	5	10
4	Otitis externa	2	8	10
5	Otomycosis	2	5	7
6	TM perforation	4	2	6
7	CSOM	4	2	6
8	ETD	3	2	5
9	Foreign body in the ear	1	2	3

10	Facial palsy: Grade - 2 (Complicated CSOM)	0	1	1
	Total	108	105	213

OME – Otitis Media with Effusion

CSOM – Chronic Suppurative Otitis Media

ETD – Eustachian Tube Dysfunction

FIGURE 3: PREVALENCE OF OTOLOGICAL CONDITIONS

UNDER PEER REVIEW

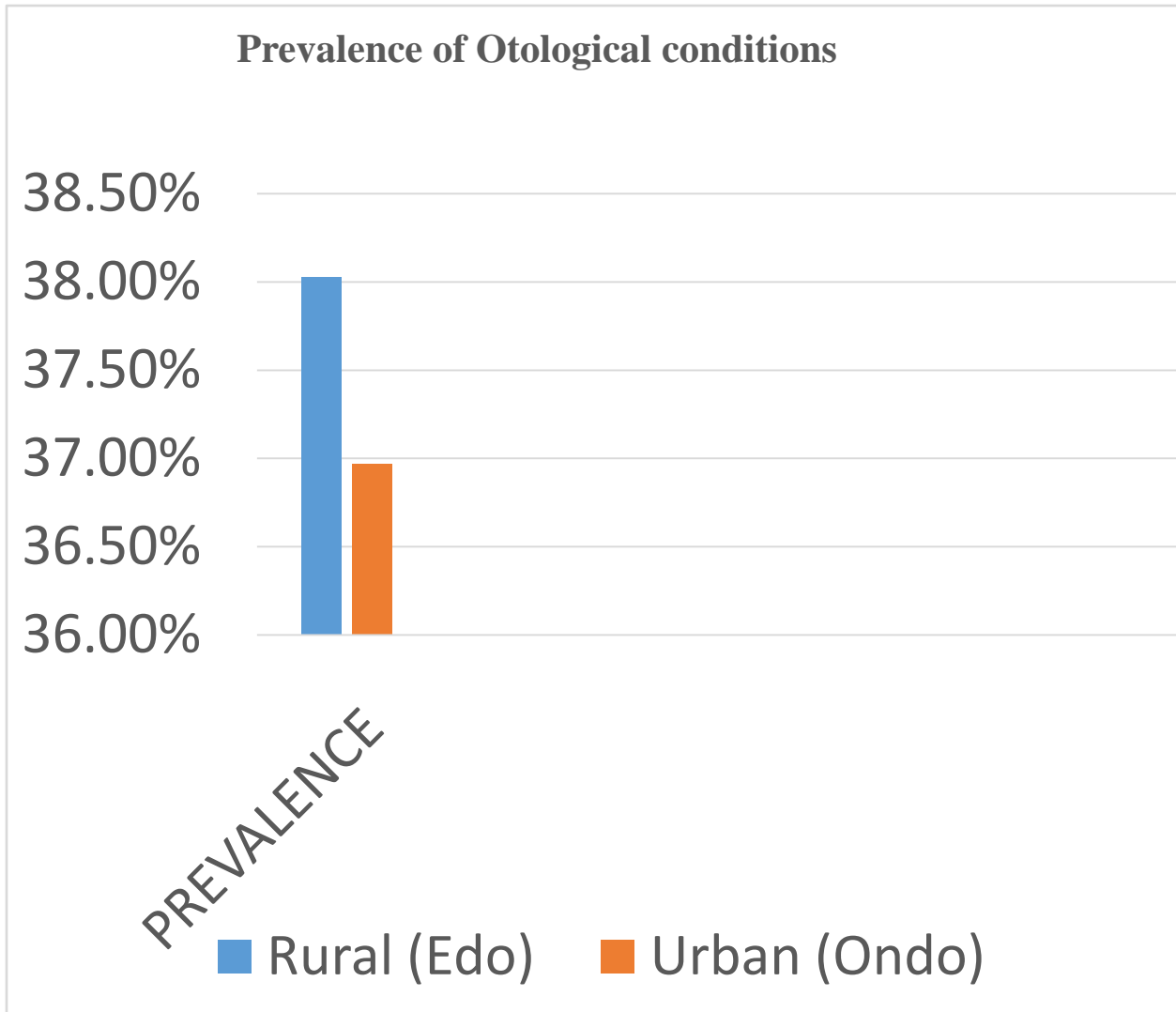


FIGURE 4: ASYMPTOMATIC OTOLOGICAL CONDITIONS

N = 21

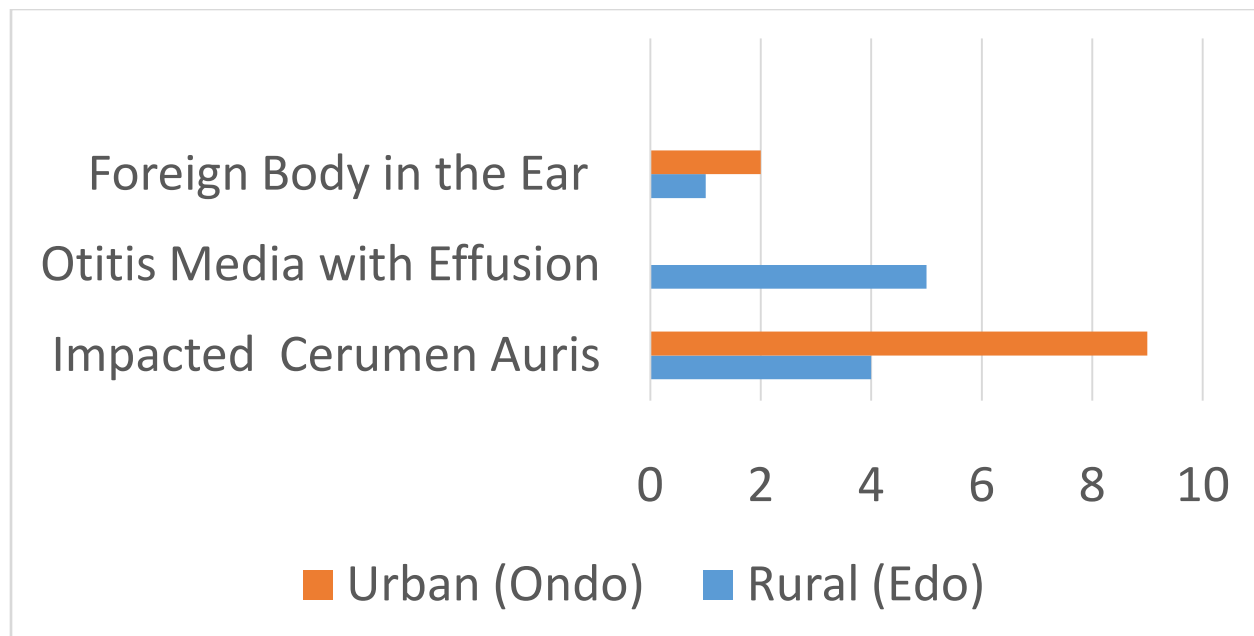


TABLE 7: LOCAL PRACTICES OF CONCERN

	Materials	Rural (Edo)	Urban (Ondo)	
Ear cleaning	Cotton bud	30	46	
	Broom stick	21	8	
	Match stick	19	12	P = 0.913
	Feather	12	2	r = 0.036
	Keys	11	18	
	Biro cover	5	7	
Self-ear care/ medication	Leaf juice	3	2	
	Gin	1	0	
	H ₂ O ₂	3	6	p = 0.508
	Ear drops	5	7	
	Cerumol	2	4	

TREATMENT / SOLUTION PROFERED

- Valsavamanoeuvre
- Ear syringing
- Ear toileting
- Ear dressing
- Antibiotics
- Ear swab mcs
- Keep ear dry
- Ear drop instillation
- Foreign body removal
- Physiotherapy
- Referral

DISCUSSION

Otological conditions

Ten different otological conditions were identified from this study and managed accordingly. These individuals may not have been reached, and may not have had the privilege and opportunity to seek for otological attention,¹ hence, the need for this study.

The commonest otological disorder in this study was Otitis Media with effusion (OME) as evidenced clinically by dull tympanic membrane. Although not within the scope of this study, most individuals that had dull tympanic membrane were further evaluated with Tympanometric assessment,² confirming evidence of fluid within the middle ear. Similar finding was recorded in a previous study by Akpalaba et al., in 2022.⁴

There is further agreement of this finding of abnormal tympanic membrane integrity with an earlier study by Chen et al in China in 2013.⁵

However, this finding is in contrast with the study by Ezeanolue et al., where Cerumen Auris was most predominant otological disorder.⁶

Furthermore, otological conditions were more prevalent in the urban setting than in the rural communities. Individuals living in urban region are expected to be more enlightened, yet there is a higher prevalence of otological pathologies in this setting.⁷ In addition, facial nerve palsy, a complication, arising from persistent purulent discharge from the ear, as well as other pathologies and trauma, affecting the brain, the face or the skull bone, were recorded in this study. Although this facial palsy was seen only in one individual in the entire study population, this individual resides in the urban community. This subject was noted to be a habitual ear cleaner with cotton buds and other pointed objects, which may have inadvertently ruptured the ear drum promoting ear suppuration. This could have been prevented just by leaving the ear alone without cleaning it.^{3,4} Hence buttressing the need for the general public to avoid cleaning the ears as the ears are self-cleansing.^{5,6}

Asymptomatic Otological findings

This study identified twenty – one different asymptomatic conditions with the most predominant being Cerumen Auris (wax in the ears) in urban community in Ondo state. This was followed by Otitis Media with Effusion in the rural setting of Edo state.

Although the least of the asymptomatic otological findings was foreign body recorded in three ears, one of the subjects nonchalantly submitted himself for otoscopy with the presumption that

he had no ear disorder. The removal of cotton bud tip from his ear marveled him. Alongside with most of the individuals who had ear syringing on account of Cerumen Auris, their testimonial was that everywhere was 'loud' meaning that they could hear better after the ear syringing. This therefore encourages all to submit themselves for health screening whenever opportunity arises.

Asymptomatic otological disorders abound. This finding of asymptomatic Otologic pathologies in this study agrees with asymptomatic otitis media with effusion found in patients with adenoid enlargement by Sogebiet al., in 2021.⁸

Identification of otological disorders of surgical importance

There was predominance of Otitis Media with Effusion in the general study population both in the urban (Ondo state) setting and in the rural community of Edo State.

Of note is the Otoscopic identification of dull tympanic membrane integrity bilaterally in a female 3 year old child, whose mother was sober as the child was considered by the society as deaf-mute. Further audiological evaluations on this young girl confirmed the clinical finding of Otitis Media with Effusion, (OME), moderately severe conductive hearing loss and the presence of good outer hair cells in her inner ears. Going extra mile in her management upon referral to the ear, nose and throat department, radiological evaluation revealed huge adenoidal tissue enlargement, narrowing the adjacent air way. The enlarged adenoids caused back flow and retention of fluid within the middle ear with resultant impaired hearing and delayed speech acquisition in this child. This was synergistically worsened by huge tonsils in this child's oropharynx. This young girl eventually had adenotonsillectomy and was placed on speech

therapy and intensive speech stimulation with purposeful and intentional family interactive engagements.

This then deaf-mute female child, rattles nursery rhymes today, what a testimony! The joy of an Otorhinolaryngological surgeon! The beauty of collaboration with rehabilitation unit, all from just **otoscopy**, which identified this otological condition of surgical importance.

One would have expected the insertion of grommets bilaterally to aid middle ear drainage and ventilation in this child. Though considered, but the morbidity and probable complications ranging from grommet migration into the middle ear and permanent tympanic membrane perforation with its antecedent suppuration were priorities.⁹ Drainage care, for the middle ear effusion, was therefore physiological and conservative.

This case therefore emphasizes the benefit of just otoscopy in identification of otological conditions of **surgical importance**.

Identified pathologies, benefit of otoscopy

In this study, 213 ear pathologies were recorded just with the use of simple instrument, ‘**the otoscope**.’ Thus showcasing the benefit of otoscope. Examination of the ear using the otoscope is called **otoscopy**. Through the identification of these pathologies, individuals of the concerned communities gained treatment and solutions to their problems, including ear syringing, ear dressing and referral to appropriate facilities for further evaluation and management.

This study therefore, is a call to all researchers, young and old, all specialties and all departments, to begin research work with whatever instrument that is available. One does not need to wait for sophisticated instrument before commencing a research study. Borrowing the

biblical statement' "What is in your hand?" A staff (Rod) with which the leader, Moses, was called to action to liberate the Israelites from The Egyptians. Therefore, begin with that simple instrument as a substrate and build on the study when more complex instruments are available. Thus, moving forward in low resource settings.¹⁰

Local practices of concern

Eleven different practices were noted among the study participants pertaining to ear cleaning, self-ear care and medications. Cotton bud usage in cleaning the ears was the commonest practice, this conforms to the result of previous studies by **Akpalaba and Onyeagwara**.³

Individuals should change their mindsets concerning ear cleaning to avoid untoward complications since the ear cleanses itself.

Everyone should avoid inserting any object, pointed and sharp objects into the ears to prevent perforation of the ear drum, thus preventing purulent discharge from the ear and its antecedent life – threatening complications.

Practice of self-medication should be discarded as some drugs are poisonous to the ears, a medical condition called ototoxicity, which can lead to complete hearing loss (deafness).^{11, 12, 13}

FUTURE STUDY

Of note is the use of leaf juice as a form of ear drop, a local practice noted from some participants **in this research work**, to treat ear infections.

This is a gray area for collaborative study. Further research on this leaf juice is needed for clinical trial to improve on already **existing and** available ear drops.

CONCLUSION

This study has shown that otological conditions are common in both rural and urban settings **including** asymptomatic presentations.

Most otological conditions are treatable and can be prevented.^{3, 14}

RECOMMENDATIONS

- Much can be achieved from otoscopy, with the simple instrument, the **otoscope**.
- Hence, this study is a call for researchers to begin research works with simple tools available. Don't wait for sophisticated instruments before commencing on a research.
- This study is a **Sensitization** for all specialties to look into areas of public health concerns and commence researches with simple tools available.
- All individuals, rich or poor, educated or non-educated, residing in urban or rural communities, should avail themselves opportunity of screening during research studies, as some otological disorders are asymptomatic.
- There is need for clinical trial in future study, using leaf juice as observed in this study, to improve on available ear drops and solve the problem of 'resistance' to some ear drops.

ETHICAL CONSIDERATION

The ethical clearance and guideline to conduct this study was gotten from Hope Hospital, a multispecialty hospital, at Costain Road, Benin City, Edo state, Nigeria.

DATA AVAILABILITY STATEMENT

Data of this study are available and accessible if reasonable request is made to the lead/Corresponding author and is granted by all authors.

REFERENCES

- 1). Adegbiyi W.A., Aina F.O., Otologic diseases presentation and management among elderly patients in a tertiary health institution, South West Nigeria. 2019:Vol. 65 No. 10-12
- 2). Akinpelu V., Amusa Y. Otological diseases in Nigerian children. Int J Otorhinolaryngol. 2007; 7.
- 3). Akpalaba I.O., Onyeagwara C. N., Community Otorhinolaryngological Service in a Group of Schools in South- South Nigeria, Nigerian Journal of Otorhinolaryngology, (NJORL). 2010 – 2015; Volume 8 To 12

- 4). Akpalaba, I. O., Blackie, F. F., Akpalaba, R. U. E. Community Health Services for Geriatrics and Widows South–South Nigeria: In *Emerging Trends in Disease and Health Research* , Vol. 2, Chap. 4, Bp international, 2022;pg 65–77.
- 5). Chen G, Fu S, Dong J, Zhang L. Otologic and audiological characteristics of children with skeletal dysplasia in central China. *Acta Otolaryngol.* 2013; Jul;133(7):728-732.
- 6). Eziyi JA, Amusa YB, Nwawolo CC, Ezeanolue BC. Wax Impaction in Nigerian School Children. *East and central African journal of surgery.* 2011;16(2):40-45.
- 7). Fufore MB, Mahmud A, Miya BS, Umar A, Suleiman A. Clinical Profile and Management of Cerumen Auris at Federal Medical Centre, Yola. *Annals Basic Clin Sci.* 2021; 4:14-21.
- 8). Sogebi OA, Oyewole EA, Ogunbanwo O. Asymptomatic otitis media with effusion in children with adenoid enlargement. *Journal of the National Medical Association.* 2021 Apr 1;113(2):158-164.
- 9). Vlastarakos PV, Nikolopoulos TP, Korres S, Tavoulari E, Tzagaroulakis A, Ferekidis E. Grommets in otitis media with effusion: the most frequent operation in children. But is it associated with significant complications?. *European journal of pediatrics.* 2007 May;166:385-391.
- 10). Clark M., Nakku D., Westerberg B. An endoscopic Ear Trainer for the low-resource setting. *The Journal of Laryngology & Otology*, 2019; 133(7), 571-574.
- 11). Ganesan P, Schmiedge J, Manchaiah V, Swapna S, Dhandayutham S, Kothandaraman PP. Ototoxicity: a challenge in diagnosis and treatment. *Journal of audiology & otology.* 2018 Apr; 22(2):59.

12). Cannizzaro E, Cannizzaro C, Plescia F, Martines F, Soleo L, Pira E, Lo Coco D. Exposure to ototoxic agents and hearing loss: A review of current knowledge. *Hearing, Balance and Communication*. 2014 Dec 1; 12(4):166-175.

13). Lovett B., Welschmeyer A., Johns J. D., Mowry S., Hoa M. Health Disparities in Otology: A PRISMA-Based Systematic Review. *Otolaryngology–Head and Neck Surgery*, 2022; 166(6), 1229–1237.

14). Adebola S. O., Ayodele S. O., Oyelakin O. A., Babarinde J. A., Adebola O. E., Pre-school hearing screening: profile of children from Ogbomoso, Nigeria. *Int J Pediatr Otorhinolaryngol*. 2013; 77(12):1987-1991.