

Full Dental Care under General Anesthesia for a Patient with Epilepsy and Cerebral Palsy: Case Report

Abstract

This report presents the case of a 5-year-old female patient with epilepsy and cerebral palsy who received dental treatment under general anesthesia due to her inability to cooperate with local anesthesia. The patient presented with multiple dental issues, including pulpitis and gingivitis, necessitating urgent intervention. Despite challenges such as motor dysfunction and cognitive impairment, successful dental treatment was achieved through careful preoperative evaluation, multidisciplinary collaboration, and meticulous perioperative management. Treatment involved extraction, pulpotomy, stainless-steel crowns, and composite restorations. Postoperative examination revealed satisfactory outcomes, although long-term oral hygiene maintenance remains crucial. The report underscores the importance of tailored approaches and comprehensive care in managing dental issues in patients with epilepsy and cerebral palsy, highlighting areas for future research to enhance treatment efficacy and mitigate associated risks.

Keywords: cerebral palsy, epilepsy, motor dysfunction, cognitive impairment, primary dentition, gingivitis, multiple caries, general anesthesia, multidisciplinary collaboration, risk assessment

1. INTRODUCTION

Cerebral palsy (CP) is the most common motor disability of childhood, resulting from brain damage during infancy, preterm birth, or birth asphyxia(1). Formerly known as "Little's disease," CP exhibits a range of symptoms, from moderate musculoskeletal impairment to significant limits in everyday activities, frequently with life-threatening complications. However, symptoms may improve over time as the nervous system matures. Brain damage around birth affects neurological and musculoskeletal systems, leading to issues such as muscle spasms, posture changes, movement limitations, sensory disturbances,

cognitive impairments, communication difficulties, behavioral issues, secondary musculoskeletal problems, and epilepsy(2,3).

Epilepsy stands as a prevalent neurological condition, impacting individuals regardless of age, race, socioeconomic status, or geographic location. It is a long-term brain condition characterized by a recurrent tendency to have seizures. Beyond the seizures themselves, epilepsy entails a range of neurobiological, cognitive, psychological, and social ramifications stemming from recurrent seizure activity(4). The differential diagnosis of epilepsy includes various clinical conditions marked by temporary changes in awareness or behavior. Typically, it can be diagnosed by a thorough medical history or by witnessing a seizure episode (5). Despite advancements, epilepsy remains complex, impacting various aspects of life for affected individuals (6).

CP and epilepsy often coexist, with epilepsy prevalence ranging from 33% to 39% in children with CP(7). Factors influencing epilepsy in this population include the cause and type of cerebral injury and the specific subtype of CP(8,9). Differences in definitions and cohorts contribute to prevalence variations. Many children with CP have relapsing and remitting epilepsy, while typically developing children with epilepsy tend to have well-controlled seizures that remit by adolescence, often due to genetic generalized epilepsies and self-limited focal epilepsies(10,11). Efforts to characterize epilepsy in children with CP highlight the need for nuanced diagnostic approaches(12).

This report presents the case of a 5-year-old epileptic female patient with CP who required urgent management of multiple pulpitis and gingivitis. This procedure was done under general anesthesia in order to assure the patient's safety and treatment efficacy.

2. CASE PRESENTATION

A 5-year-old female patient presented with a complaint of experiencing pain while eating, prompting her parents' desire to address their daughter's dental issues. The patient's medical history revealed diagnoses of epilepsy and CP, along with blindness. The patient is on medication with Levetiracetam, an antiepileptic drug utilized for the treatment of partial, myoclonic, and tonic-clonic seizures.

Due to the patient's inadequate oral hygiene and her inability to cooperate with dental procedures under local anesthesia, it was anticipated that caries would progress swiftly. Consequently, opting for general anesthesia was deemed necessary to facilitate behavior management during dental treatment involving multiple teeth.

Her parents were well informed about the method, process, and side effects of the dental procedure. Then, a consent form was signed prior to the inpatient general anesthesia procedure.

Before the procedure, a comprehensive blood examination was conducted, and consultation was sought from the patient's pediatrician. The results indicated no factors that would pose a risk during general anesthesia. Monitoring equipment, including an electrocardiogram (ECG) monitor, pulse oximeter, sphygmomanometer, thermometer, and end-tidal CO₂ monitor, were connected to the patient. As a prophylactic measure, the patient received an antibiotic one hour prior to the procedure. Throughout the procedure, the patient exhibited no movement or spontaneous respiration, and no additional muscle relaxants were administered.

Propofol is utilized as an anesthetic agent. The patient doesn't have any contraindications to the use of anesthetic agents like propofol. However, the patient is uncooperative and has physical impairments. Establishing venous access for anesthesia induction poses a significant challenge. Therefore, we opt for Sevoflurane, which can serve as a safe and efficient alternative for inducing anesthesia.

Extraoral clinical examination showed facial asymmetry (Figure 1a), no facial swelling, no palpable lymph nodes, and a normal facial profile (Class I profile) (Figure 1b).

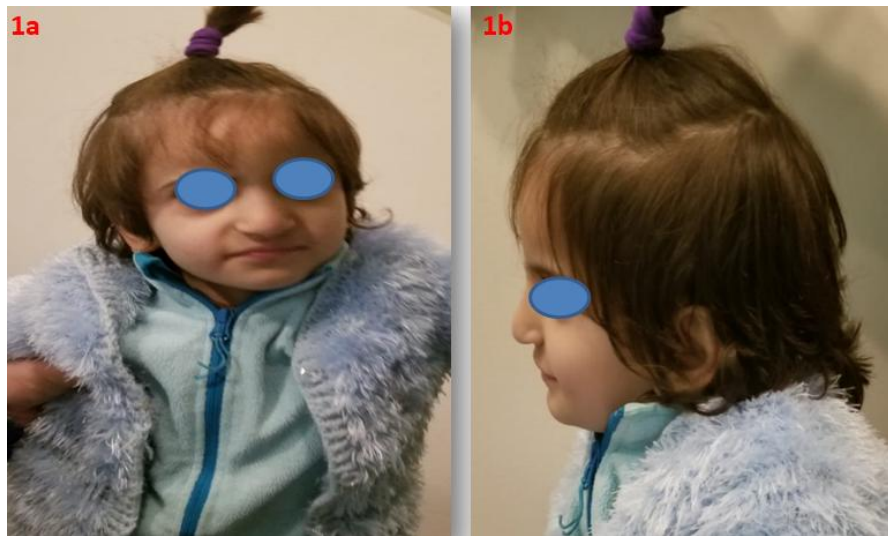

Figure 1: The patient's extraoral clinical examination highlighted facial features associated with epilepsy and CP. (a) Frontal showing facial asymmetry, and (b) lateral extraoral photographs showing no facial swelling, no palpable lymph nodes, and a normal facial profile (Class I profile).

The clinical and radiological intraoral examinations showed primary dentition status with multiple caries, generalized gingivitis, dental abrasion due to bruxism, and Class II malocclusion (Figures 2 and 3).

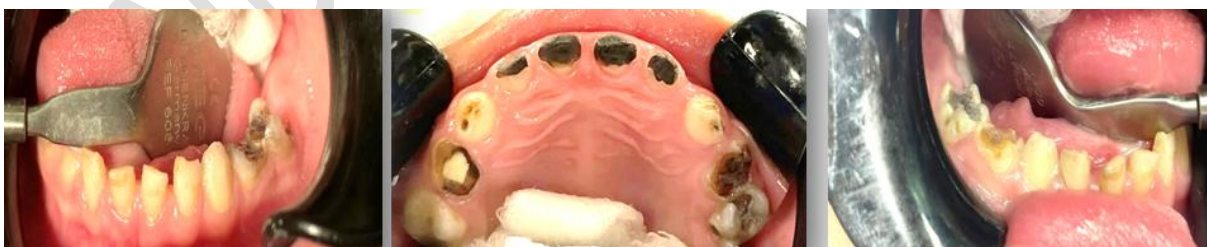

Figure 2: Intraoral examination showing generalized gingivitis with multiple caries.

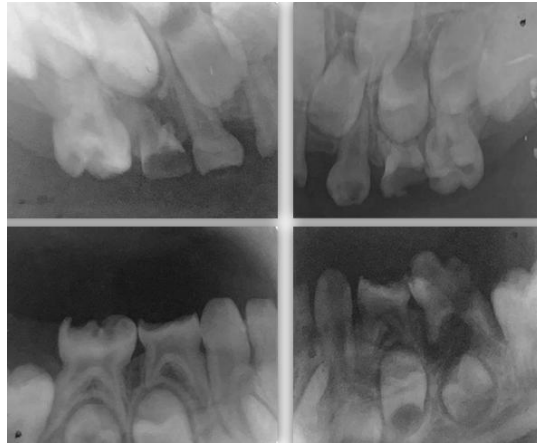


Figure 3: Intraoral radiographs

Based on the findings, the treatment plan included extraction of the upper right first molar, the four upper anterior teeth, and the lower left second molar due to extensive decay. Additionally, pulpotomy and stainless-steel crowns were planned for the upper right second molar, the upper left first and second molars, the lower left second molar, and the lower right first and second molars due to severe decay with pulp exposure. Composite restorations were performed on the upper left and right canines, as well as the lower anterior teeth, where caries were present. Figures 4 and 5 display postoperative intraoral photos and radiographs showcasing the outcome of the treatment process.

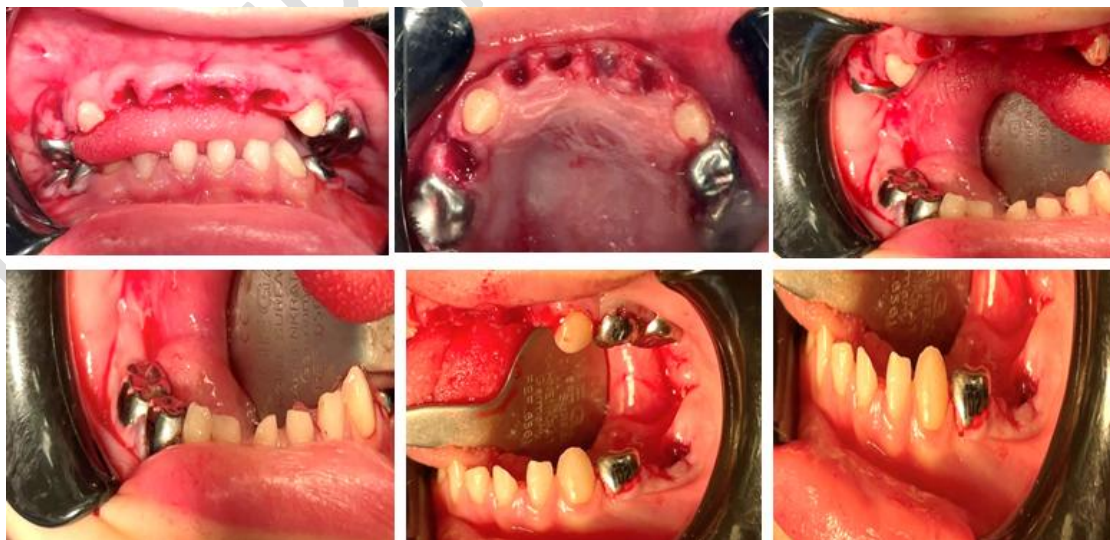

Figure 4: Postoperative intraoral photos showcasing the outcome of the treatment process.

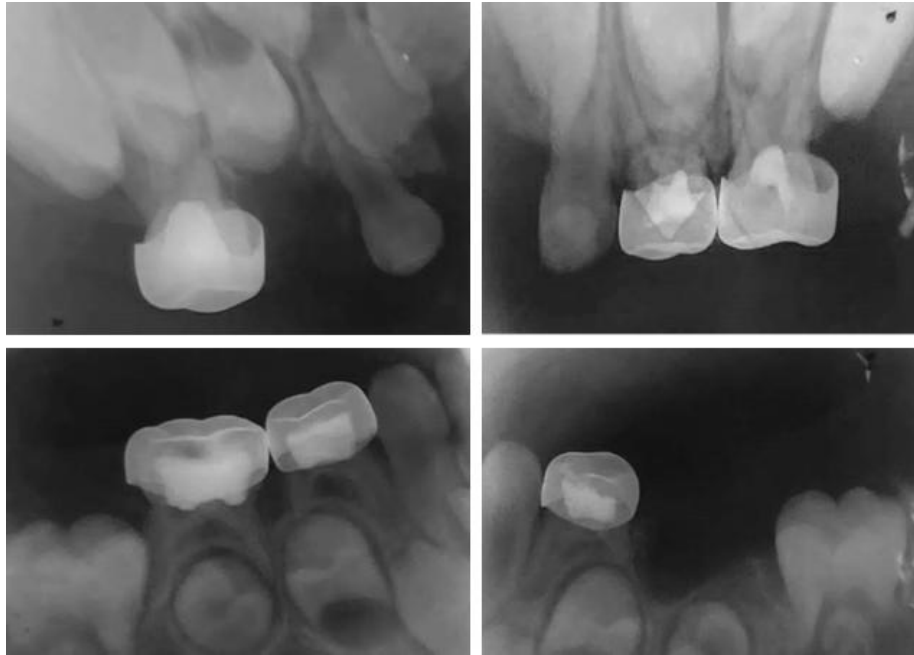


Figure 5: Postoperative intraoral radiographs showcasing the outcome of the treatment.

The treatment took 3 hours, and the anesthetic procedure lasted for 3.5 hours. The patient exhibited no complications following the treatment and was discharged to return home the day after the dental treatment.

During the one-week follow-up, an intraoral examination revealed a lack of adequate oral hygiene. The patient's parents were given instructions on how to perform daily dental hygiene procedures, including cleaning the teeth with sterile gauze. A follow-up appointment was scheduled for the patient in three months.

3. DISCUSSION

This report outlines the case of a pediatric patient diagnosed with epilepsy and CP undergoing dental treatment under general anesthesia.

Several studies have shown that children with CP are more likely to experience gingival and dental issues (13-15). Challenges in maintaining daily oral hygiene, intraoral sensitivity, orofacial motor dysfunction, and the use of antiepileptic drugs, notably phenytoin, are significant contributing factors (14,15). Gingival hyperplasia serves as a predictor for periodontal diseases. Bruxism is prevalent among CP patients, with estimates ranging from

40 to 70%, predominantly affecting the upper jaw's teeth along with lower molars and premolars. Drooling is attributed to coordination difficulties during the voluntary swallowing phase. Additionally, the most common malocclusion observed in CP patients is Class II with open bite and overjet, stemming from muscular hyperextension of the head. This hyperextension stretches the oral soft tissues, contributing to mandibular retrognathia and vertical growth, consequently causing molars to over-erupt and promoting a low tongue position (16).

Dental caries development is influenced by various factors encompassing biological, economic, cultural, environmental, and social aspects (17). The extent of cognitive and motor deficits correlates directly with the probability of developing dental caries (18). Severe motor coordination issues impede the ability to maintain proper oral hygiene, while cognitive deficits pose challenges in cooperating for effective oral care (19).

General anesthesia can greatly facilitate dental treatment for patients who are unable to cooperate during dental visits, particularly those with motor dysfunction such as Parkinson's disease, CP, and other conditions leading to uncontrolled tremors. Individuals with CP often present complex dental issues, including difficulties with lip closure, a higher prevalence of malocclusion, temporomandibular disorders, swallowing difficulties, and associated challenges like malnutrition and aspiration pneumonia. Moreover, patients with CP commonly experience additional disabilities related to central nervous system damage, including cognitive impairment, visual or hearing impairments, seizures, and communication and behavioral disturbances, along with chronic systemic problems stemming from their condition(20). For those patients, any treatment process that requires them to sit still and keep their mouths open without any sudden movements is challenging. Clinicians prefer to

perform treatment under general anesthesia for both safety and effectiveness, despite acknowledging the inherent risks associated with anesthesia (21).

It is recognized that intellectually disabled children often find it challenging to engage in voluntary oral care. Consequently, addressing dental issues in intellectually disabled pediatric patients and educating parents about oral hygiene in a straightforward manner are crucial. By fostering communication not only with patients but also with their parents, we can establish an environment conducive to providing consistent and positive long-term oral care for these patients (20).

Developing a safe and effective anesthetic strategy for patients with CP necessitates the anesthesiologist's comprehensive grasp of how this range of disorders impacts the physiology of various organ systems (22).

Neurologically, severe intellectual disability may complicate pre-operative anxiety assessment, often presenting as irritability. Epilepsy affects around 30% of patients, with concerns about seizures under general anesthesia, although evidence is lacking (23). These patients exhibit lower minimum alveolar concentrations for volatile anesthetic agents and delayed emergence, possibly due to various factors including medication use and hypothermia (24). Additionally, children with CP are at an increased risk of developing perioperative hypothermia. Factors such as decreased circulatory volume and increased blood loss during surgery can precipitate this condition (25). In patients with CP, managing the airway can pose challenges due to increased secretions and the risk of aspiration from gastroesophageal reflux, which is common among them (24). In addition, these patients are at a heightened risk of experiencing hypoxia while unconscious (26). Airway evaluation should prioritize assessing potential challenges with laryngoscopy, which may arise from abnormal dentition, temporomandibular joint dysfunction, and positioning issues. Previous anesthetic records can offer valuable insights to aid in airway management (25). On the other hand, the

prevalence of latex allergies appears to be increasing in patients diagnosed with CP. This trend could be attributed, at least in part, to repeated and prolonged interactions with healthcare settings. It is imperative to thoroughly document any allergies by consulting the patient's medical records or engaging with their caregiver during the preoperative assessment (22).

All these medical issues limit the duration of working under general anesthesia. In severe cases as ours, we are restricted by time constraints. Therefore, we have decided to extract the upper anterior teeth instead of proceeding with the zirconia crown, which requires a significant amount of time to complete.

4. CONCLUSION

In order to successfully treat patients with epilepsy and cerebral palsy and to enable behavior management when numerous teeth need to be treated, general anesthesia is a must. It is also essential to use a multidisciplinary strategy that includes comprehensive patient evaluation, perioperative treatment, and oral health promotion.

Ethical Approval:

As per international standards or university standards written ethical approval has been collected and preserved by the author(s).

Consent

As per international standards, parental written consent has been collected and preserved by the author(s).

References

1. Vitrikas K, Dalton H, Breish D. Cerebral palsy: an overview. *Am Fam Physician*. 2020;101(4):213-220.
2. Sadowska M, Sarecka-Hujar B, Kopyta I. Cerebral palsy: current opinions on definition, epidemiology, risk factors, classification and treatment options. *Neuropsychiatr Dis Treat*. 2020;16:1505-1518.

3. Ruiz Brunner MM, Cuestas E. La construcción de la definición parálisis cerebral: un recorrido histórico hasta la actualidad. [The construction of cerebral palsy definition: a historical journey to the present]. *Rev Fac Cien Med Univ Nac Cordoba*. 2019;76(2):113-117.
4. Fisher RS, van Emde Boas W, Blume W, Elger C, Genton P, Lee P, Engel J Jr. Epileptic seizures and epilepsy: definitions proposed by the international league against epilepsy (ILAE) and the international bureau for epilepsy (IBE). *Epilepsia*. 2005;46(4):470-472.
5. Neligan A, Hauser WA, Sander JW. The epidemiology of the epilepsies. *Handb Clin Neurol*. 2012;107:113-133.
6. Beghi E. The epidemiology of epilepsy. *Neuroepidemiology*. 2020;54(2):185-191.
7. Sorge G, Sorge A. Epilepsy and chromosomal abnormalities. *Ital J Pediatr*. 2010;36:36.
8. Tsubouchi Y, Tanabe A, Saito Y, Noma H, Maegaki Y. Long-term prognosis of epilepsy in patients with cerebral palsy. *Dev Med Child Neurol*. 2019;61(9):1067-1073.
9. Delacy MJ, Reid SM. Australian cerebral palsy register group. Profile of associated impairments at age 5 years in Australia by cerebral palsy subtype and gross motor function classification system level for birth years 1996 to 2005. *Dev Med Child Neurol*. 2016;58 Suppl 2:50-56.
10. El Tantawi NT, Abd Elmegid DS, Atef E. Seizure outcome and epilepsy patterns in patients with cerebral palsy. *Seizure*. 2019;65:166-171.
11. Ferrie C, Caraballo R, Covanis A, Demirbilek V, Dervent A, Kivity S, et al. Panayiotopoulos syndrome: a consensus view. *Dev Med Child Neurol*. 2006;48(3):236-240.
12. Cooper MS, Mackay MT, Dagia C, Fahey MC, Howell KB, Reddihough D, et al. Epilepsy syndromes in cerebral palsy: varied, evolving and mostly self-limited. *Brain*. 2023;146(2):587-599.
13. Graham HK, Harvey A, Rodda J, Natrass GR, Pirpiris M. The functional mobility scale (FMS). *J Pediatr Orthop*. 2004;24(5):514-520.
14. Gunel MK, Mutlu A, Tarsuslu T, Livanelioglu A. Relationship among the manual ability classification system (MACS), the gross motor function classification system (GMFCS), and the functional status (WeeFIM) in children with spastic cerebral palsy. *Eur J Pediatr*. 2009;168(4):477-485.
15. Jan MM. Clinical review of pediatric epilepsy. *Neurosciences (Riyadh)*. 2005;10(4):255-264.
16. Escanilla-Casal A, Aznar-Gómez M, Viaño JM, López-Giménez A, Rivera-Baró A. Dental treatment under general anesthesia in a group of patients with cerebral palsy and a group of healthy pediatric patients. *Med Oral Patol Oral Cir Bucal*. 2014;19(5):e490-494.

17. Beck JD, Youngblood M Jr, Atkinson JC, Mauriello S, Kaste LM, Badner VM, et al. The prevalence of caries and tooth loss among participants in the Hispanic community health study/study of Latinos. *J Am Dent Assoc.* 2014;145(6):531-540. Erratum in: *J Am Dent Assoc.* 2014;145(7):703.
18. Dourado MR, Andrade PM, Ramos-Jorge ML, Moreira RN, Oliveira-Ferreira F. Association between executive/attentional functions and caries in children with cerebral palsy. *Res Dev Disabil.* 2013;34(9):2493-2499.
19. Subasi F, Mumcu G, Koksall L, Cimilli H, Bitlis D. Factors affecting oral health habits among children with cerebral palsy: pilot study. *Pediatr Int.* 2007;49(6):853-857.
20. Pradopo S, Cahaya Khairani F, Sudarsono W. General anaesthesia in the dental management of a child with cerebral palsy and autism: A Case Report. *Indonesian Journal of Dental Medicine.* 2018;1(1):1-4.
21. Choi J, Doh RM. Dental treatment under general anesthesia for patients with severe disabilities. *J Dent Anesth Pain Med.* 2021;21(2):87-98.
22. Miller B, Rondeau B. Anesthetic considerations in patients with cerebral palsy. 2023. In: *StatPearls [Internet]. Treasure Island (FL): StatPearls Publishing; 2024.*
23. Benish SM, Cascino GD, Warner ME, Worrell GA, Wass CT. Effect of general anesthesia in patients with epilepsy: a population-based study. *Epilepsy Behav.* 2010;17(1):87-89.
24. Wass CT, Warner ME, Worrell GA, Castagno JA, Howe M, Kerber KA, et al. Effect of general anesthesia in patients with cerebral palsy at the turn of the new millennium: a population-based study evaluating perioperative outcome and brief overview of anesthetic implications of this coexisting disease. *J Child Neurol.* 2012;27(7):859-866.
25. Shaikh SI, Hegade G. Role of anesthesiologist in the management of a child with cerebral palsy. *Anesth Essays Res.* 2017;11(3):544-549.
26. Frost EA. Differential diagnosis of delayed awakening from general anesthesia: a review. *Middle East J Anaesthesiol.* 2014;22(6):537-548.