

Vocal Cord Paralysis Unveiling a Dilated Cardiomyopathy: A Rare Case of Ortner's Syndrome and Literature Review

Abstract: Ortner Syndrome (OS) is a disorder characterized by dysphonia due to vascular compression of the Left Recurrent Laryngeal Nerve (LRLN), mainly by heart or vessel abnormalities. We discuss the case of a 56-year-old patient with no medical past history, who entered our department due to four months of growing hoarseness. The left vocal cord was paralyzed, according to videostroboscopic testing. A CT scan of the neck and chest was ordered, and it indicated enlarged heart cavities. The patient was addressed to the cardiology department, and was later scheduled for heart surgery. The follow-up was marked by an improvement of his hoarseness. The most prevalent cause of OS is mitral valve disease, which results in left atrial dilatation and nerve compression. This sickness may be associated with other symptoms caused by the compression of organs such as the esophagus. Treatment is based on the treatment of the underlying heart condition.

Keywords: Nerve, Paralysis, Vocal Cord, Hoarseness

1. Introduction

“Ortner Syndrome (OS) is a condition that produces dysphonia due to vascular compression of the Left Recurrent Laryngeal Nerve (LRLN), such as atrial enlargement” [4]. “Along its long path, the LRLN can be compressed by cardiac and vascular elements. Furthermore, this nerve crosses the aortic arch posteriorly before ascending into the tracheoesophageal groove, causing it to be more susceptible to compression by other structures” [1]. “OS has been defined as a hypertrophy of the left atrium caused by mitral stenosis, resulting in paralysis of the LRLN. However, other aetiologies may be responsible for that, including aortic aneurysms, pulmonary artery aneurysms, and atrial fibrillation. Although uncommon, dysphonia can develop as the sole symptom of vascular diseases such as those mentioned above” [5]. “Nobert Ortner, an Austrian clinician, first documented this illness in a patient with mitral valve stenosis and left atrial dilatation in context in 1897” [1]. “Various cardiovascular disorders related with LRLN palsy have been described over the last century. Because of these factors, the syndrome is sometimes known as cardiovascular syndrome. Giant cell arteritis, patent ductus arteriosus,

and pericardial effusion are all unusual causes of OS. It is more frequent in older men, but it can also arise in children with congenital heart failure in rare situations. It is difficult to locate data on the occurrence of this syndrome in the literature, although it is currently an uncommon phenomenon with a low prevalence” [6].

2. Case Report

A 56-year-old male presented to our department with a four-month history of progressive hoarseness and dysphonia and dyspnea on exertion. He denied any respiratory symptoms, chest pain or dysphagia. He did not suffer any weight loss or fever. The patient was a 40-pack-year tobacco smoker with no evidence of pre-existing structural heart abnormalities or other medical conditions identified. Physical examination revealed left vocal cord paralysis in the paramedian position on flexible laryngoscopy (Figure 1), prompting further investigation. The macroscopic aspect of the vocal cords was normal. No cervical lymph nodes were palpable and the thyroid gland was not enlarged. The rest of the otolaryngologic exam was normal.

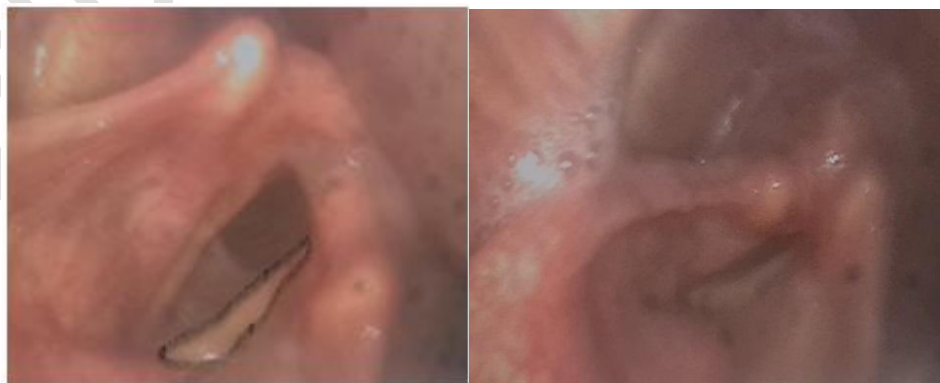

Figure 1. Videostroboscopic images showing left vocal cord paralysis

A cervicothoracic computed tomography scan revealed a dilatation of the cardiac cavities, particularly in the left atrium, resulting in a significant cardiomegaly with a cardiothoracic index of 0.75 and compressing the left recurrent laryngeal nerve. The vocal cords were asymmetrical with an enlarged left pyriform sinus and laryngeal

entricle. Echocardiography confirmed the presence of a severe degenerative mitral and tricuspid regurgitation with dilation and dysfunction of the left cardiac chambers. The right cavities were normal and the ejection fraction was 45%.

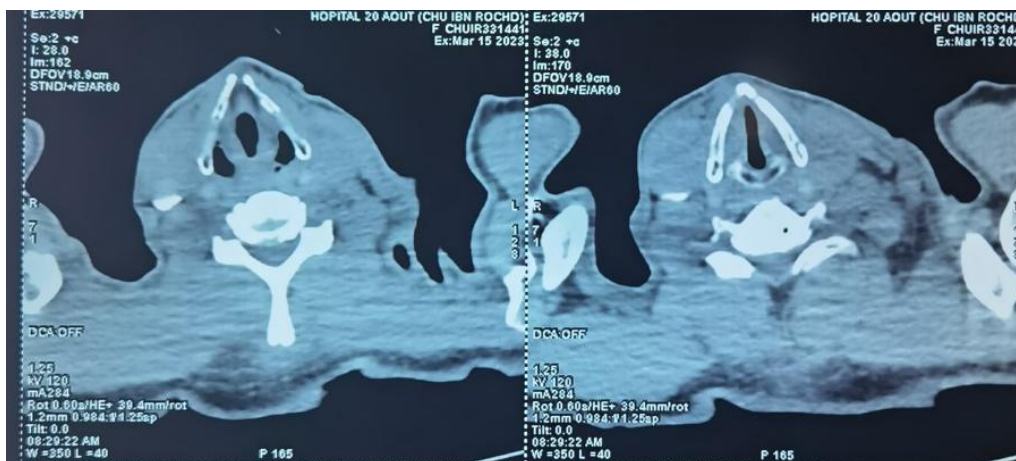


Figure 2. CT scan of the larynx showing left vocal cord paralysis.

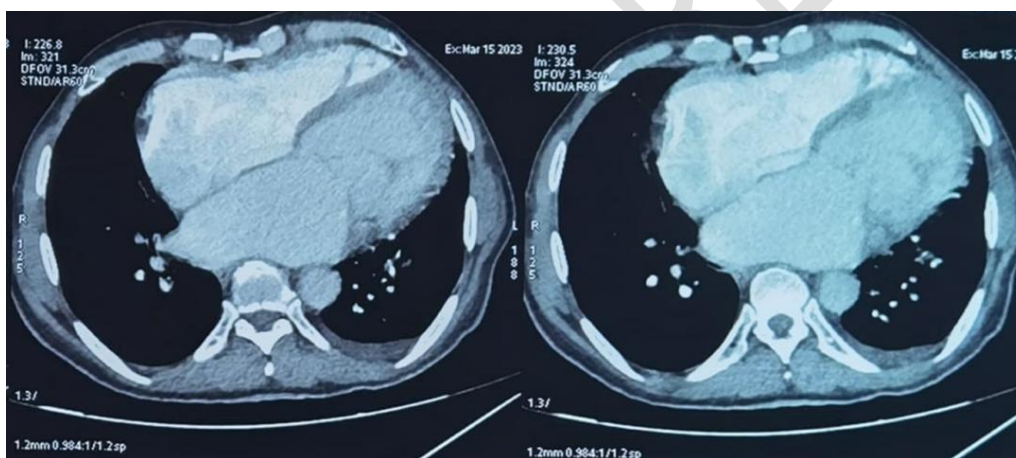


Figure 3. CT scans showing a severe dilation of the left cardiac chambers.

The patient was addressed to the cardiology department where a medical treatment was initiated and optimized. An electrocardiogram and a coronarography were performed and the patient was scheduled for a surgical intervention to manage both mitral and tricuspid valve regurgitation.

The patient has benefited from an injection of hyaluronic acid, followed by voice rehabilitation. He was subsequently examined during a 12-month follow-up, revealing a slight improvement of the hoarseness. Vocal cord medialization surgery was suggested, but the patient declined to proceed with the intervention.

3. Discussion

Surgical trauma and cancer invasion of the thyroid, lung, and esophagus have been identified as the main causes of recurrent laryngeal nerve paralysis.

Ortner's syndrome is a rare form of extralaryngeal voice hoarseness caused by mechanical compression of the left recurrent laryngeal nerve by mediastinal structures, resulting in homolateral vocal cord paralysis. Ortner originally proposed that compressive symptoms in mitral stenosis were caused by left atrial enlargement, which is caused by various cardiac or valvular abnormalities, pulmonary hypertension, aortic disorders, right subclavian artery aneurysm, and ductus arteriosus aneurysm [1-4]. Recurrent laryngeal nerve paralysis can be caused by a ventricular hypertrophy or pathological aortic or pulmonary lymphadenopathy [5].

The left RLN normally arises from the left vagus nerve along the anterolateral boundary of the aortic arch, between the main pulmonary artery and the aortic arch. It rises in the space between the trachea and the esophagus, slightly behind the ligamentum arteriosum. The right RLN connects the trachea with the esophagus by crossing and hooking around the first section of the subclavian artery. As a result,

adilated pulmonary artery, a persisting ductus arteriosus, or an aortic arch aneurysm may compress the RLN.

To identify this condition, the complete tract of the recurrent laryngeal nerves, including their passage through the aorto-pulmonary space, must be examined. The inferior extension of these can should include the pulmonary bifurcation [6-8].

For individuals with persistent dysphonia, an ENT evaluation is required. A chronic dysphonia lasting more than two weeks should be checked and investigated, with the potential reasons for voice change assessed [6]. As a result, imaging investigations are necessary to rule out a compressive etiology (neoplastic or vascular) [7].

Once a video fibroscopic evaluation has determined that vocal cord paralysis is the cause of hoarseness, the origin of the paralysis must be investigated. It is critical to confirm that there are no alarming lesions visible on ENT examination [6].

Cervico-thoracic imaging investigations should be performed to rule out compressive causes of paralysis. CT is the most often used test today because it can detect indirect symptoms of vocal paralysis, such as medial displacement of the ipsilateral posterior edge of the vocal cords [9, 10]. Furthermore, it enables us to assess a wider range of cervical, cardiovascular, and thoracic disorders that produce current laryngeal nerve paralysis. The mediastinum up to the level of the aortopulmonary window (left side) or the brachiocephalic artery (right side) should be included in the CT scan [10].

A basic chest X-ray can also be used to diagnose some vascular compressive causes, providing equivalent sensitivity at a lower cost [11, 12]. There are various entities that can compress the RLN due to cardiovascular reasons. The primary cause was mitral valvular disease with left atrial dilatation. Other diseases that might produce this cardiovascular condition have not emerged, including pulmonary artery aneurysms and aortic aneurysms [12-15].

Indirect laryngoscopy, paired with laryngeal electromyography, confirms the severity of cord paralysis.

The incidence of cardiovascular syndrome varies according to the underlying cause; in mitral stenosis, it ranges from 0.6% to 5%, which is reassuring for thoracic aortic aneurysm as a comparatively high incidence of more than 32% [15].

In most cases, treatment requires correcting the underlying condition. The duration and intensity of hoarseness may influence the totality and speed of recovery of normal voice.

In our case, hoarseness was linked to compression of the left recurrent laryngeal nerve in the aorto-pulmonary window caused by an enlarged left atrium caused by mitral stenosis, and mitral and tricuspid valve surgery reduced slightly voice hoarseness.

Clinicians should be aware that patients who present with hoarseness of voice require meticulous evaluation in order to rule out significant cardiovascular illnesses.

4. Conclusion

Ortner syndrome, also known as cardiovascular syndrome, is a rare condition characterized by left RLN paralysis caused by extrinsic compression of a cardiovascular etiology. The pathology of the mitral valve has been the most studied etiology, although new diseases responsible for this illness, such as aortic dissection and aortic and pulmonary aneurysms, have surfaced in recent years. Hoarseness is the most common symptom. To rule out malignant pharyngolaryngeal

lesions, a correct anamnesis and a fibroscopic examination are required for its diagnosis. To determine the compressive cause, imaging studies must be performed. Treatment is based on the treatment of the underlying cardiovascular condition, and there are several strategies for treating vocal paralysis.

5. Consent

As per International Standards or University Standards, Patient written consent has been collected and preserved by the authors.

6. Ethical approval

As per International Standard or University Standards written ethical approval has been collected and preserved by the authors.

7. Competing interests

Authors have declared that no competing interests exist.

References

- [1] Ortner N. Recurrent laryngeal nerve palsy in mitral stenosis. *Wien Klin Wochenschr* 1897; 10: 753-62.
- [2] Mulpuru SK, Vasavada BC, Punukollu GK, Patel AG. Cardiovascular syndrome: a systematic review. *Heart Lung Circ* 2008; 17: 1-4.
- [3] Chen RF, Lin CT, Lu CH. Ortner's syndrome—a rare cause of unilateral vocal cord paralysis: a case report. *Kaohsiung J Med Sci* 2009; 24: 203-6.
- [4] Kheok SW, Salkade PR, Bangaragiri A, Koh NSY, Chen RC, et al. Cardiovascular Hoarseness (Ortner's Syndrome): A Pictorial Review. *Curr Probl Diagn Radiol*. 2021; 50: 749-754. 2.
- [5] Shrimanth YS, Barwad P, Maralakunte M, Sharma A, Sihag BK, et al. Ortner's Syndrome Due to Giant Thoracic Aortic Aneurysm. *J Invasive Cardiol*. 2022; 34: E346.
- [6] Klee K, Eick C, Witlandt R, Gawaz M, Didczuneit-Sandhop B, et al. Unilateral recurrent nerve palsy and cardiovascular disease—Ortner's syndrome. *J Cardiol Cases*. 2016; 15: 88-90.
- [7] Ruiz-Serrato A, Pérez-Velasco MÁ, Guerrero-León M de L, García Ordóñez MÁ. Ortner syndrome and dysphagia due to a giant left atrium in the elderly patient [Dysphagia and Ortner syndrome due to a giant left atrium in the elderly]. *Rev Esp Geriatr Gerontol*. 2015; 50: 204-205.
- [8] Semionov A, Kosiuk J. Ortner syndrome secondary to aortic aneurysm. *Radiol Case Rep*. 2016; 12: 29-30.
- [9] Bashir MH, Joyce C, Bolduan A, Sehgal V, Smith M, Charous SJ. Revisiting CTS signs of Unilateral Vocal Fold Paralysis: A Single, Blinded Study. *AJNR Am J Neuroradiol*. 2022; 43: 592-596. 8.
- [10] Paquette CM, Manos DC, Psooy BJ. Unilateral vocal cord paralysis:

A review of CT findings, mediastinal causes, and the course of the recurrent laryngeal nerves. *Radiographics*. 2012;32:721-740.

- [11] Leoce BM, Bernik JT, Voigt B, Dardik H, Bernik TR, et al. Ortner syndrome secondary to aortic aneurysm. *J Vasc Surg Cases Innov Tech*. 2021;7:371-373.
- [12] Koh WJ, Azman M. Hoarseness in an older adult: Ortner syndrome. *Malays Fam Physician*. 2021;16:129-131.
- [13] Hurtarte Sandoval AR, Carlos Zamora R, Gómez Carrasco JM, Jurado Ramos A. Ortner's syndrome: a case report and review of the literature. *BMJ Case Rep*. 2014;2014:bcr2013202900.
- [14] Srinivasan A, Agarwal R. Cardiovascular syndrome. *Monaldi Arch Chest Dis*. 2011;75:241-242. 13.
- [15] Plastiras SC, Pamboucas C, Zafiriou T, Lazaris N, Toumanidis S, et al. Ortner's syndrome: A multifactorial cardiovascular syndrome. *Clin Cardiol*. 2010;33:E99-100.

UNDER PEER REVIEW