

Original Research Article

The Usefulness of Postoperative Tranexamic Acid in Primary Breast Augmentation with Implants

Abstract :

Aims:

Tranexamic acid, an anti-fibrinolytic agent, is finding more and more indications in surgery because it induces a decrease in blood loss. However, few articles have focused on its use in plastic surgery. The aim of this study was to investigate the impact of oral administration of tranexamic acid on post primary breast augmentation drainage volumes.

Methodology:

A total of 60 patients were included in this case-control study over a period of 17 months. Patients were divided into two equal groups. The case group received 2 g of oral tranexamic acid per day while the control group received no treatment. A record of the main data (study population characteristics, location and type of implant, duration of surgery, mean arterial pressure at surgery, volume in the drains, length of hospital stay and complications) was made.

Results:

Oral administration of tranexamic acid significantly reduces drain volumes by 20% at day 1 (40 mL in the control group versus 30 mL in the case group/ $p < 0.0001$) and increases the number of patients discharged at day 1 by 44% (43% in the control group versus 87% in the case group). There were no treatment-related side effects. The two groups were comparable in terms of age, implant placement and perioperative blood pressure. At a distance, there was no significant difference in terms of periprosthetic capsular contracture.

Conclusion:

Oral administration of TXA is a major contribution to therapies to reduce post-operative bleeding and probably the length of hospital stay.

Keywords : Tranexamic acid, breast augmentation , implant

1. Introduction

Breast augmentation by prosthesis is one of the most common operation in plastic surgery. Intra- and postoperative bleeding can lead to complications such as haematomas, implant's infection, and delayed exposure of the implant, leading to repeat visits to the operating theatre. These complications lead to additional risk for the patient and additional costs, with new hospital admissions and repeat administrations of general anaesthesia. In addition, breast augmentation surgery is not particularly incapacitating, but the drainage impairs the patient's movements and delays their discharge. It is therefore of interest to seek to minimise the volumes of the latter to allow rapid removal of the suction drain and thereby the patient's discharge from hospital.

Tranexamic acid is an antifibrinolytic. It works by blocking the lysine receptor on plasminogen, which prevents the activation of plasminogen into plasmin (1). Tranexamic acid has been primarily used in cardiac, orthopaedic, and trauma surgery. These indications have been increasingly extended with uses in oral surgery, gynaecology and gastroenterology (2).

However, relatively few articles have focused on the interest of using it in plastic surgery. The aim of this study was to investigate whether oral administration of tranexamic acid reduced drainage volumes after primary breast augmentation with implants.

A secondary, delayed complication of implants is the formation of a peri-prosthetic capsular contracture. This peri-prosthetic contracture can result in breast deformity and pain. The result then becomes unsightly. Implant replacement with capsulectomy is the standard treatment. Spear et al. (3) established Baker's classification to define the different stages of this capsular retraction. Handel et al. (4) have shown a link between early postoperative peri-prosthetic haematoma and the development of peri-prosthetic contractile capsules. We therefore contacted the patients' months to years later to see if the patients who had had tranexamic acid had fewer cases of capsular contracture than the control patients.

2. Material and Methods

Study participants were enrolled between 1 November 2014 and 1 April 2016. Patients were required to be between 18 and 50 years of age, admitted to the department for primary bilateral breast augmentation with prostheses. We excluded from the study patients with a history of venous thromboembolism, those taking anticoagulants or platelet aggregation inhibitors, those with severe co-morbidities (ASA III–IV), those with contraindications to the administration of tranexamic acid, those for whom the implants were placed above the pectoralis muscles, and those for whom we also performed a mastopexy. For each patient, we recorded their gender, age, type of implant inserted (anatomical or round shape), the texture of the implant (smooth or textured), the size of the implant, the surgical incision (sub-mammary or peri-areolar), the operating time (in minutes), the average blood pressure during surgery (in mmHg), the drainage volumes (in millilitres) per side and per day without recording the colour or consistency and the length of hospital stay (in days). Complications were also noted (haematoma, infection, early exposure of the implant, pulmonary embolism, phlebitis, anaphylactic reaction). All early (less than seven days) and delayed (less than thirty days) postoperative complications were also recorded. All side effects associated with treatment with Spotof® have also been listed.

A total of 60 patients were included in this retrospective cohort study. Participants were divided into two equal groups. The use of tranexamic acid is not yet standardised in breast augmentation. We therefore followed the recommendations of one gram twice a day, starting immediately after the end of the surgery, to avoid any adverse effects. The treated patients therefore received 2 grams of Spotof® (C.C.D laboratory, Portugal) oral solution per day for the first three days postoperatively, while the other patients received no equivalent treatment.

Four surgeons participated in this study. The operations were all carried out at the same hospital. The surgeries were performed by two operators. Each surgeon operated on one side of the patient. At the end of the surgery, a suction drain was placed in the retropectoral space of each breast, and a compressive garment was applied to the surgical site before discharge from the operating room. The surgical dressing was removed the day after the operation. The patients all received oral analgesics according to the hospital's protocols, and did not receive thromboprophylaxis according to the recommendations of the French Society of Anaesthesia and Intensive Care Medicine (SFAR). During their stay in the hospital, patients received a visit from a nurse every four hours after leaving the recovery room. Drainage volumes were recorded every 24 hours in the morning. The drain was removed if the volume was less than 40cc per 24 hours, in accordance with the department protocol. Patients were free to leave after both drainage tubes were removed. All patients were seen in consultation at seven days and at two months after surgery, in accordance with the department protocol. Patients were given a telephone number, which could be called at any time of the day, to deal with any complications promptly.

Patients were contacted again between March and April 2022. We attempted to contact all patients by email or phone. If our first attempt was not successful, we made two further attempts to contact them. Patients then answered our questions in-person or by phone. We looked for the presence of a capsular contracture, a breast asymmetry and a surgical second-look since primary breast augmentation. We also took pictures of the patients who came in person to the follow-up consultation.

Quantitative variables are presented with their median (interquartile range) [minimum-maximum]; they were compared between groups with the Wilcoxon test. Qualitative variables are presented with numbers (percentages); they were compared between groups with Fischer's exact test. The proportion of 40mL drainage volume \leq at D1 postoperatively was estimated per breast and per patient (40mL \leq volume, i.e. removal of suction drain for both breasts). Similarly, the volume of drainage at D1 and D1-2 (for patients with a suction drain at D2) was estimated per breast and per patient.

The proportion of 40mL drainage volume \leq at D1 and the drainage volumes per breast were compared as a function of TXA treatment using generalised linear mixed models with random effects on patient and surgeon (4 surgeons participated in the study). The proportion of patients whose 2 drainage tubes were removed on Day 1 (2 drainage volumes of \leq 40 mL on Day 1) and drainage volumes per patient (bilateral volume) were compared according to treatment with TXA using Wilcoxon tests. A linear regression model was then used to look for predictors of bleeding. This linear regression

model made it possible to explore the factors associated with response after a bivariate scan. This scan selected as a possible factor those with a significant response at $p=0.25$. A search for the best model was then carried out using a top-down step-by-step approach evaluated by the Akaike information criterion. All tests were two-tailed, and a significance level below 5% was considered to indicate a significant association. The statistical analysis was carried out using the software **R** [7] & various packages, in particular, tidyverse [8], FactoMineR [5] & baseph [6].

This study was authorised and registered with the FDA, ClinicalTrials.gov Identifier: NCT03364569.

3. Result

During the study period, we therefore included 60 patients; 30 of them received tranexamic acid (TXA) and 30 did not. The study population was homogeneous in age, implant type, surgical approach, surgeon, blood pressure during surgery and operative time (Table 1). Drainage volumes between the two groups were compared. (Table 2). Drainage volumes were lower in the treated patients compared to the untreated patients on D1 and on D1–2

Table 1: Characteristics of the study population

Variables	Total	No TXA	TXA	P
Total	60	30 (50)	30 (50)	
Age (year)	30 (25 to 37) [19 to 54]	30 (27 to 36) [19 to 52]	32 (23 to 38) [20 to 54]	0.78
shape of implants				1
Round	55 (92)	27 (90)	28 (93)	
Anatomic	5 (8)	3 (10)	2 (7)	
texture of implants				0.75
Smooth	12 (20)	5 (17)	7 (23)	
Textured	48 (80)	25 (83)	23 (77)	
Surgical pocket				
Retro-pectoral	60 (100)	30 (100)	30 (100)	
Surgeons				1
1	16 (27)	8 (27)	8 (27)	
2	13 (22)	6 (20)	7 (23)	
3	16 (27)	8 (27)	8 (27)	
4	15 (25)	8 (27)	7 (23)	
Look first				1
Periareolar	31 (52)	16 (53)	15 (50)	
Infra-mammaire	29 (48)	14 (47)	15 (50)	
Operating time	142 (131 to 170) [91 to 260]	140 (131 to 174) [91 to 258]	145 (134 to 160) [110 to 260]	0.67
TA moyenne (mmHg)	67 (63 to 71) [52 to 90]	68 (61 to 72) [52 to 79]	66 (64 to 71) [61 to 90]	0.99
Average BP				0.003
1	36 (60)	13 (43)	23 (77)	
2	13 (22)	7 (23)	6 (20)	
3	10 (17)	9 (30)	1 (3)	
6	1 (2)	1 (3)	0 (0)	
hospit duration > 1d	24 (40)	17 (57)	7 (23)	0.017

Table 2: Description of the drainage volumes

Variables	Total	No TXA	TXA	P
Comparison N=120 breasts				
Workforce	120	60	60	
Volume D1 ≤ 40 mL	87 (72)	32 (53)	55 (92)	0.003
Volume D1(mL)	30 (20 to 46) [0 to 175]	40 (28 to 60) [10 to 175]	30 (20 to 30) [0 to 140]	<0.0001
Volume D2(mL)	100 (70 to 125) [55 to 200]	100 (74 to 125) [55 to 200]	70 (60 to 135) [60 to 180]	0.22
Comparison N=60 breasts				
Workforce	60	30	30	
Volume D1 ≤ 40 mL, bilateral	39 (65)	13 (43)	26 (87)	0.0009
Volume D1(mL)	60 (44 to 91) [10 to 255]	75 (52 to 110) [30 to 255]	52 (32 to 65) [10 to 180]	0.001
Volume D2(mL)	135 (100 to 210) [60 to 325]	145 (100 to 230) [70 to 325]	132 (112 to 146) [60 to 180]	0.47

Statistically significantly, the number of suction drain with a volume of less than 40mL at D1 was higher in the TXA group: 92% ($P<0.05$). There was therefore more redon drain removal at D1 in this group (figure 1). Consequently, the number of patients discharged at D1 was 26 or 87% in the TXA group, whereas it was only 13 or 43% in the noTXA group. The two redon drains were therefore removed earlier in the treated patients. This difference was also statistically significant ($P<0.00009$) (figure 2).

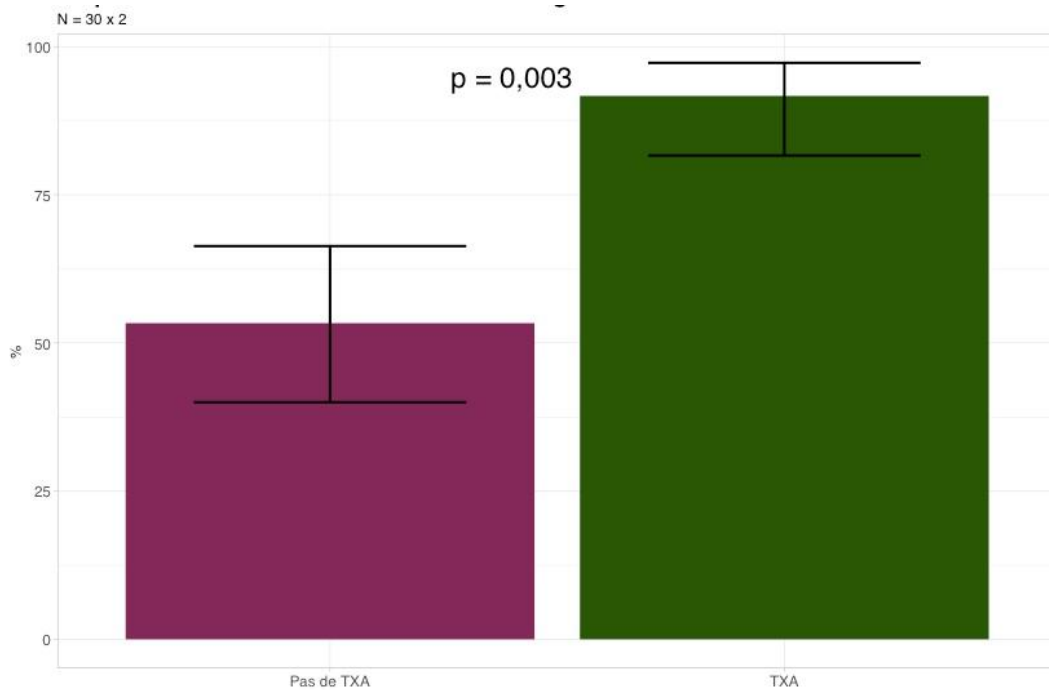


Figure 1 : Proportion of breasts with a drainage volume $\leq 40\text{mL}$ at D1 post-op ($N=60*2$)

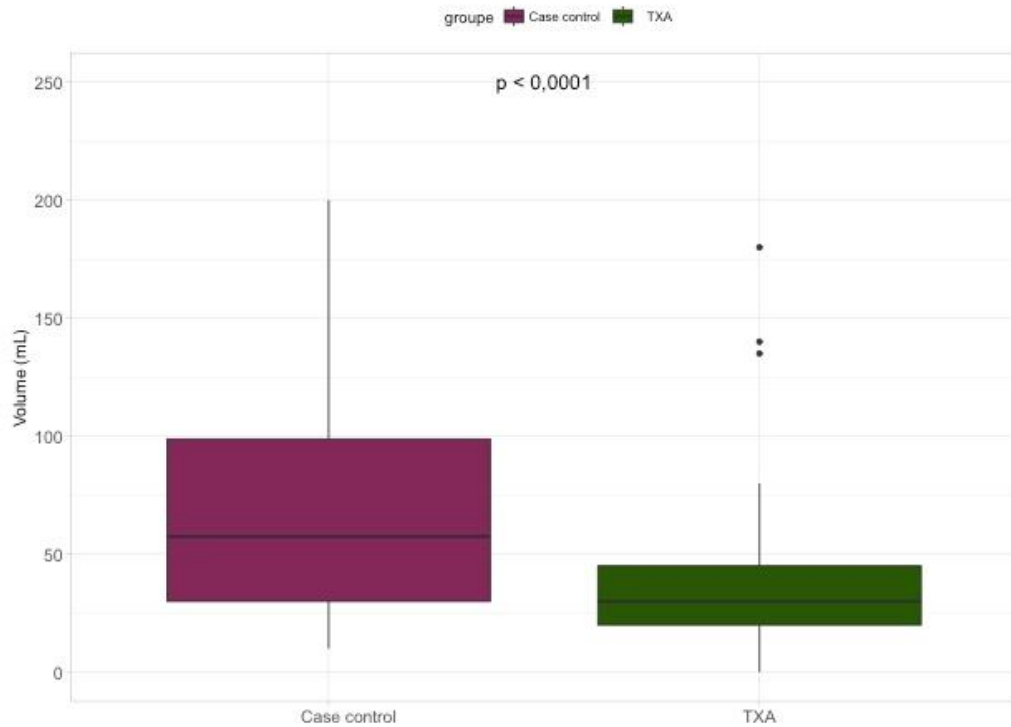


Figure 2: Proportion of patients with both drainage volumes (left and right breasts) $\leq 40\text{mL}$ at D1 post-op (N=30*2).

Finally, the plot (figure 3) shows the cumulative drain volumes in patients according to TXA treatment. As seen previously, drainage volumes were significantly lower in TXA patients.

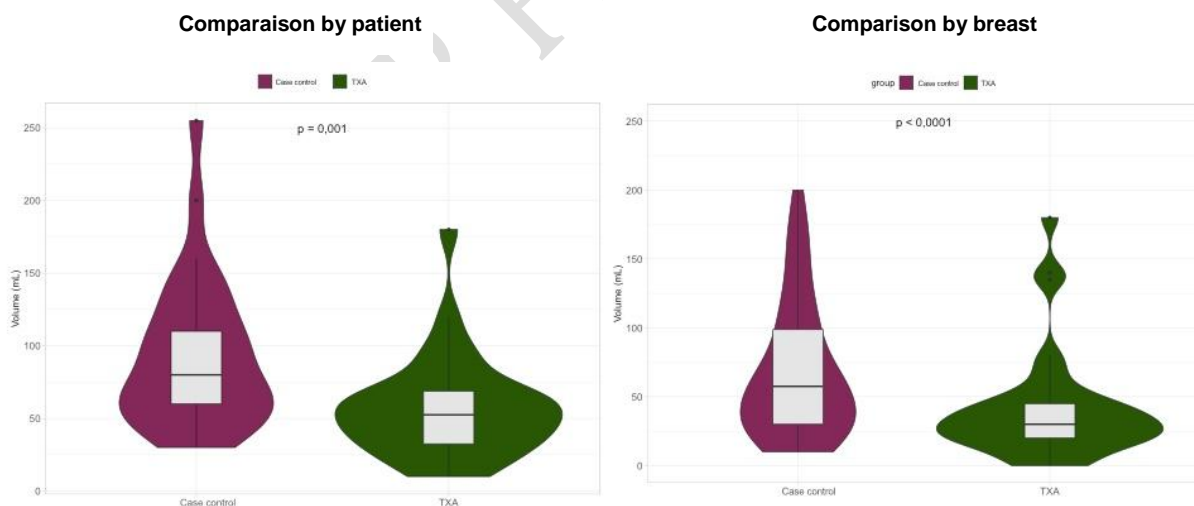


Figure 3: Comparison of drainage volumes according to TXA treatment, at D1 postoperatively, per breast and per patient

The question could have been raised as to whether there was an intercurrent factor explaining the difference in drainage volume and therefore bleeding. We carried out a monivariate analysis with its various factors. The results are presented in table 3. Only the duration of the operation seemed to influence the volume of drainage in the suction drains. Indeed, the longer the operating time, the greater the drainage volumes (figure 4).

Table 3: Bleeding factor – Monivariate Analysis

	p-value
groupe	0.023
Age (Year)	0.35
Implant Volume Right (cc)	0.224
Implant Volume Left (cc)	0.152
Implant Shape	0.602
Implant Texture	0.587
Operative Time (Min)	0.017
Mean Operative Blood Pressure (mmHg)	0.165

Note :
 factorial variables: t. test ; numerical variables: correlation test

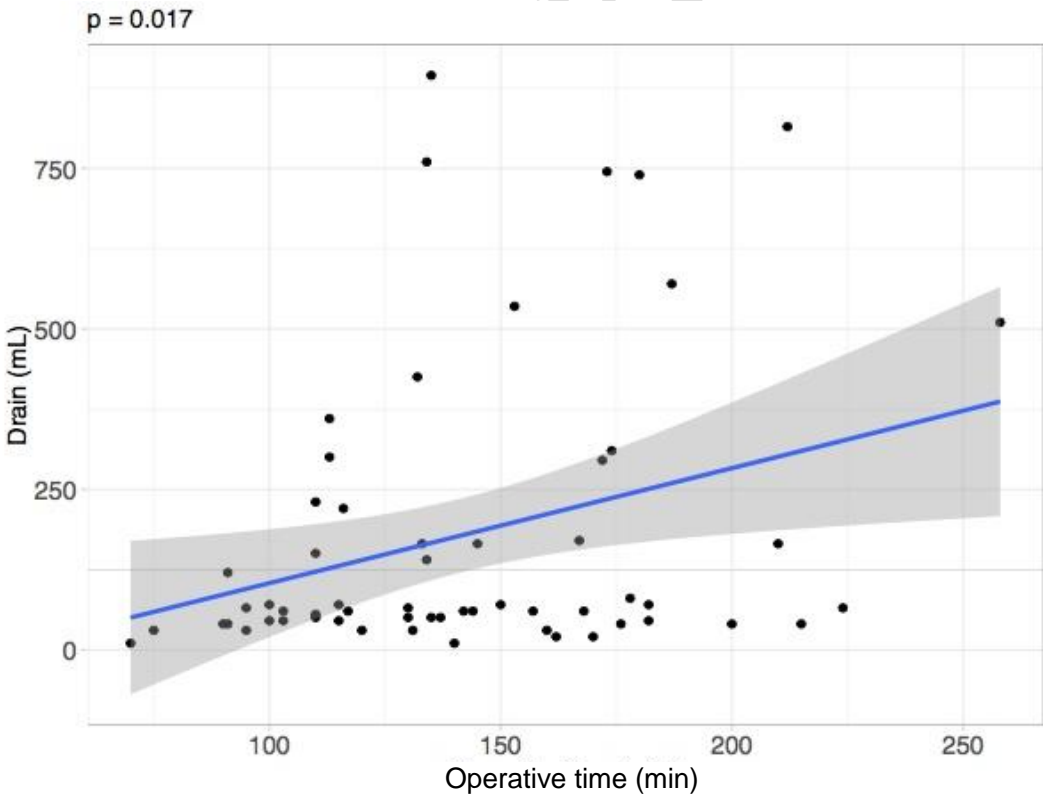
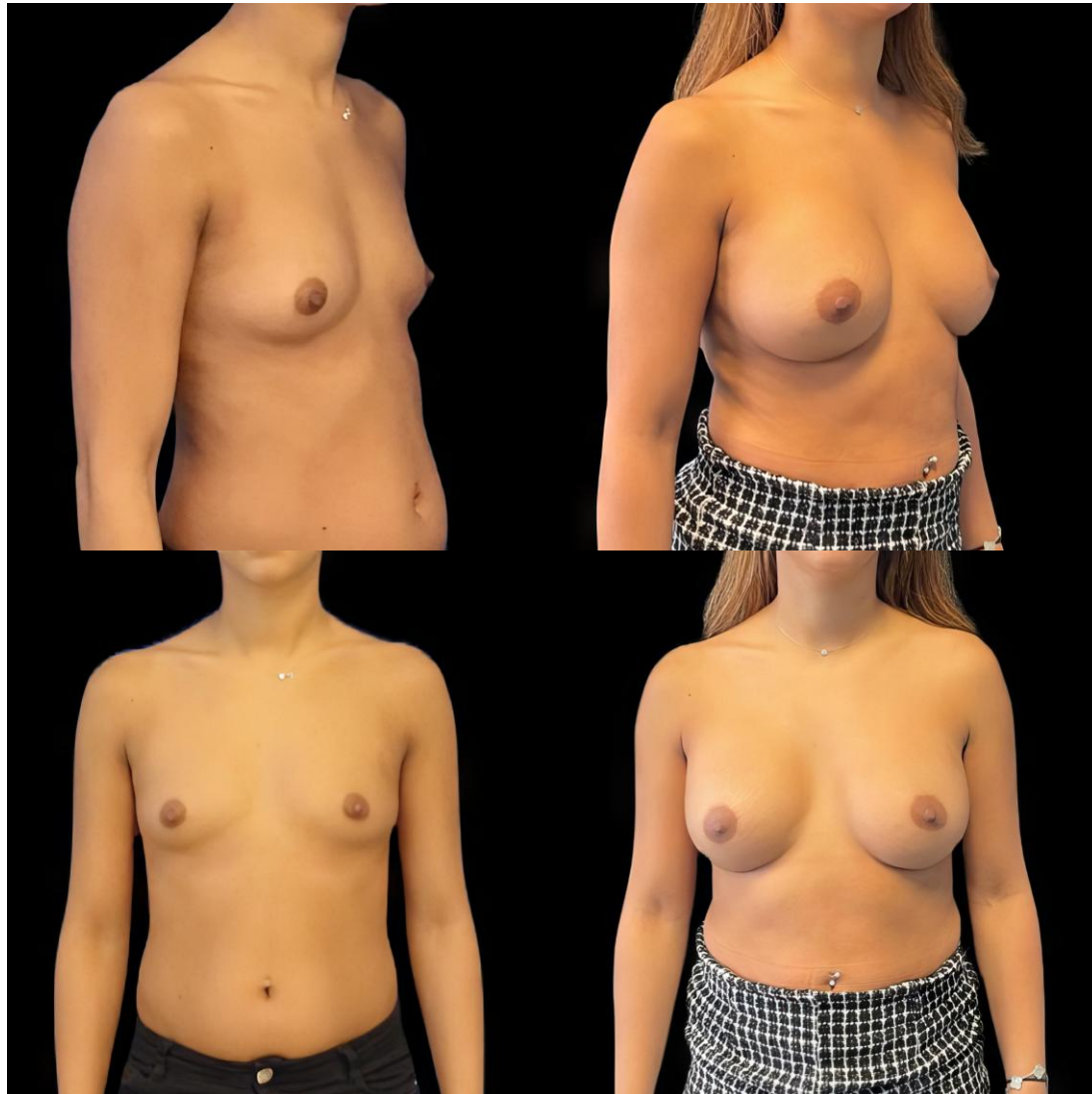


Figure 4: Operating time and drainage volume.

Finally, 27 patients were successfully re-contacted in the second phase of our study. One patient was unable to answer questions about capsular contracture and asymmetry correctly over the phone. In total, we found no significant difference between the two groups for the number of periprosthetic retractile capsule, surgical second-look or implant replacement and breast asymmetry. The prosthesis changes were caused by a capsular contracture and an implant malposition. Figure 5 and 6 show pre and post operative photos of two patients.



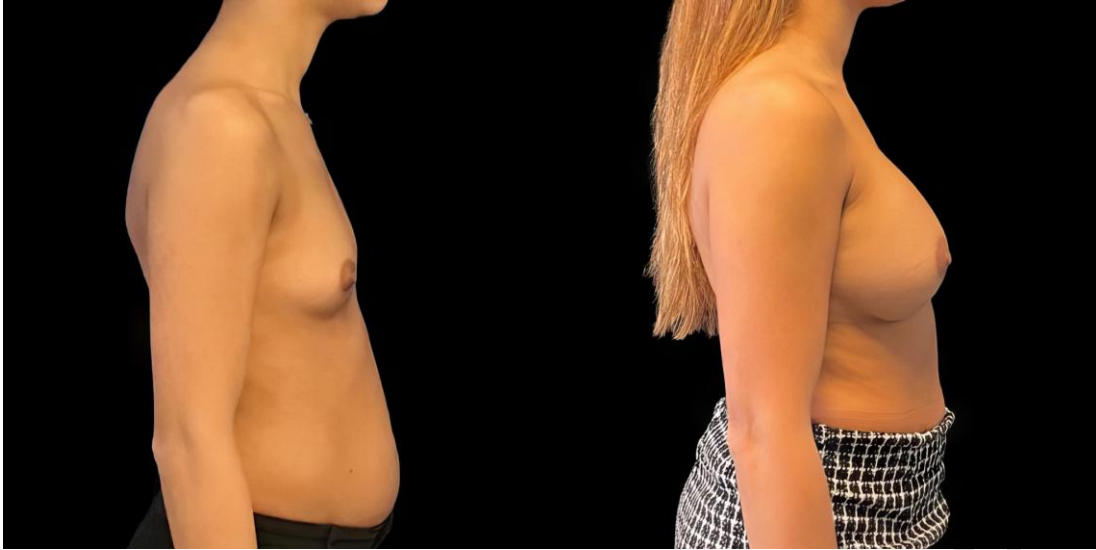
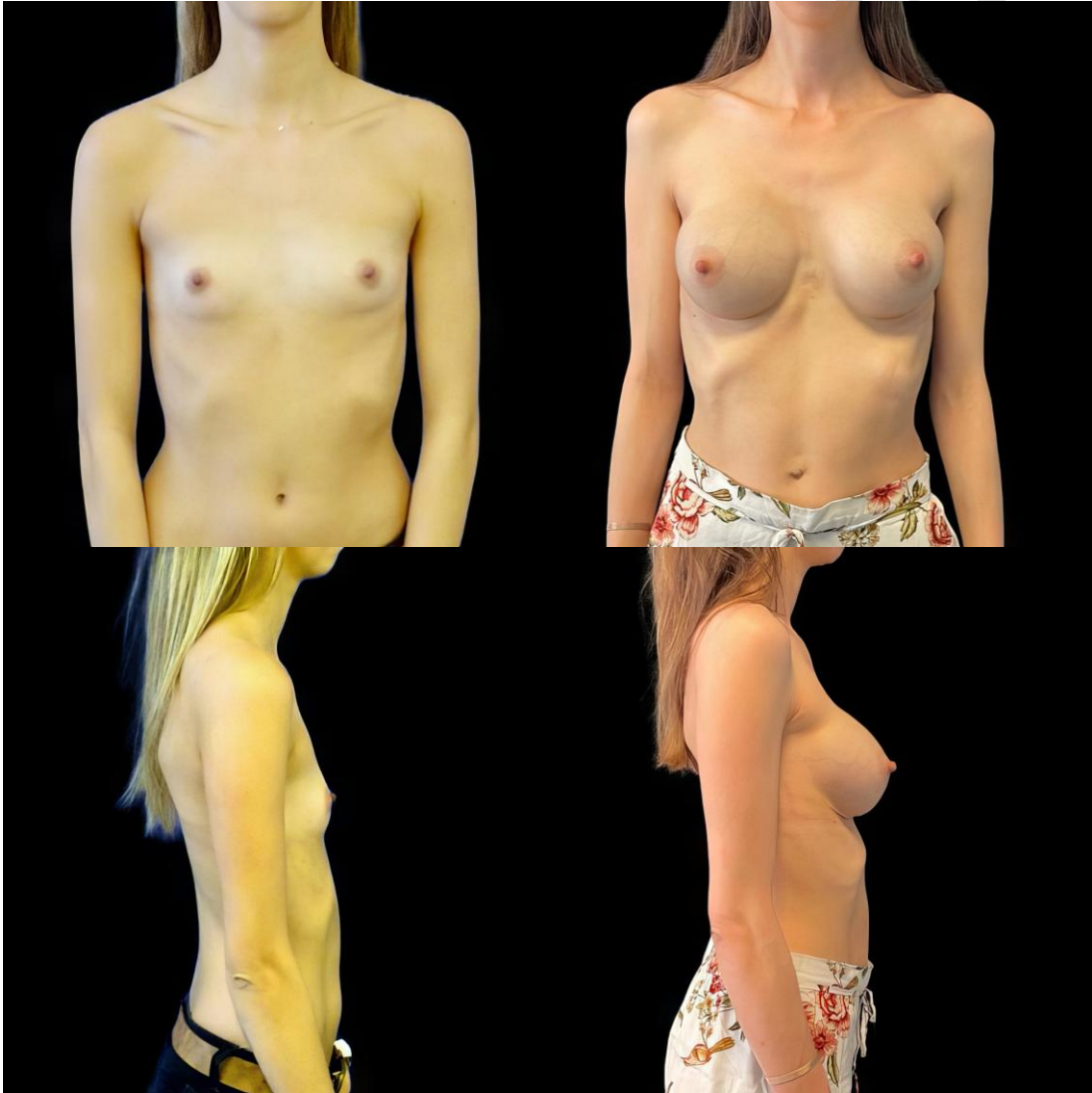

Figure 5 :Pre et post operative photos of patient treated with tranexamic acid , post operative photo were taken at 7 years old



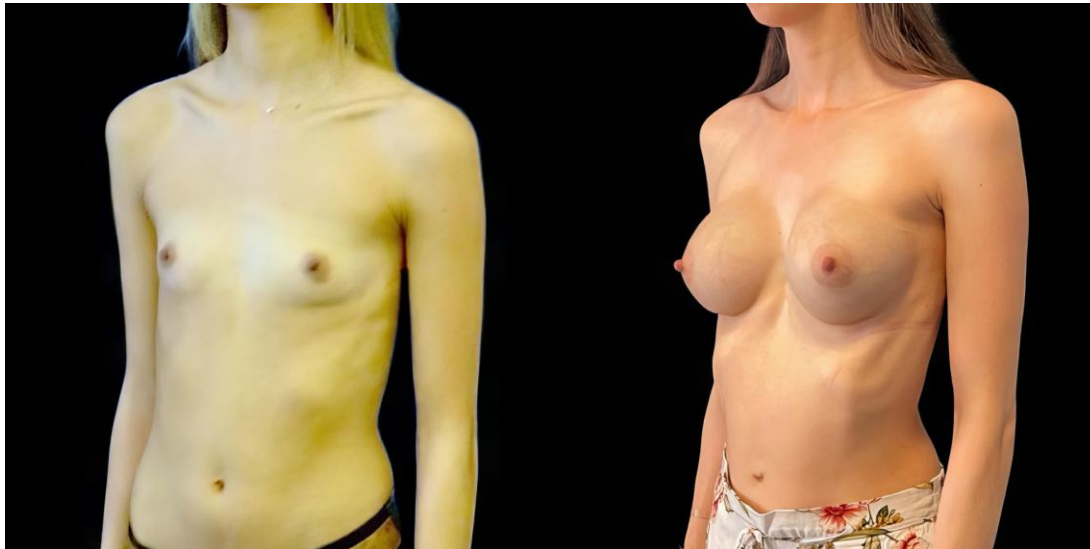


Figure 6 :Pre et post operative photos of patient treated without tranexamic acid, post operative photo were taken at 7 years old

During our study, there were no complications in the entire study population.

Discussion:

Tranexamic acid in surgery was mainly used for patients treated with anticoagulants (9). Subsequently, it found many indications in the management of post-traumatic haemorrhages (10), and cardiac and orthopaedic surgery (11). These applications are expanding as there is considerable research into its usefulness in the perioperative management of blood loss. For example, it has been shown that its use in perioperative settings reduces blood loss by 34% (12), with small differences depending on the type of surgery and the way the drug is administered. A systematic review of the literature also found that TXA decreased the likelihood of patients requiring transfusion by 38% (13).

Tranexamic acid is increasingly being used in cosmetic and functional surgery. In rhinoplasty, its indication has been proven by two meta-analyses (14) (15). They showed a reduction in perioperative bleeding, postoperative oedema and ecchymosis. In breast surgery, Ausen (16) used TXA-soaked compresses on perioperative breast reduction surgery. There was a 39% decrease in blood loss in the suction drains at 24 hours post-surgery. The clear benefit of tranexamic acid has recently been summarised in an article in Rohrich (17.)

In our study, we showed a 20% decrease in drainage volumes at D1, as well as an increase in discharge at D1 in patients on TXA. Therefore, it can be asserted that tranexamic acid reduces postoperative bleeding, and therefore reduces postoperative complications (haematomas, infections, etc.). Nevertheless, it is noted that there is no significant difference concerning the cumulative drainage volumes on D1–2. This can be explained by a lack of data. Indeed, in the TXA group, only 4 patients and 5 suction drains remained, compared to 17 patients and 28 drainage devices in the control group. If we look at the length of hospital stay of the patients, we can see that the maximum length of hospital stay for TXA patients is 3

days, whereas, in the other group, 10 patients were discharged between D3 and D6. Therefore, it can be accepted that drainage volumes remain greater than 40 mL for a longer period of time in untreated patients. However, the current trend is to maximise outpatient surgery. It could therefore be hypothesised that patients could be discharged with their drainage tubes and a prescription to remove the tubes if the volume is $\leq 40\text{mL}$. The problem remains unresolved as we are aware of the discomfort generated by the presence of drainage tubes in patients. In addition, the presence of a suction drain device at home often generates stress and discomfort for patients. Their early removal should therefore be considered an important goal prior to the hospital discharge.

One of the main concerns of our study is its non-randomisation of patients. Treatment should have been randomly defined to avoid selection bias. Indeed, nurses and surgeons, who collect data of drainage volumes, were also the ones who delivered the treatment. Measurement bias cannot be excluded. Furthermore, a group with placebo treatment should have been included. However, our study focuses only on the placement of primary breast augmentations. There are no additional procedures such as capsulectomy or placement of an acellular dermal matrix (ADM). As known, these procedures can promote the production of seromas. It can therefore be concluded that the drainage volumes recorded are a good reflection of the postoperative blood located in the implant pockets.

We have chosen to carry out oral and postoperative administrations of tranexamic acid. It is interesting to note that the majority of study protocols on this molecule favour intravenous perioperative administrations. It is questionable whether intraoperative administration of tranexamic acid, more or less in combination with postoperative administration, would not have the same effects or even improve its effectiveness.

The incidence rate of peri-prosthetic contracture varies according to the studies between 2.8% and 20.4%, with a follow-up of between 10 and 15 years (18). The link between capsular retraction and postoperative haematoma has been demonstrated by numerous studies. (19–21). In these studies, the authors highlight the link between haematoma, inflammation, infection and contracture. There is an important role for TGF- β inflammation factor in periprosthetic capsule thickening. Studies thus show an interest in limiting proinflammatory factors. Thus, there seems to be an interest in the use of a mechanical insertion device to limit infections. In our study, we had one case of capsular formation in the tranexamic acid group.

We chose to administer tranexamic acid orally. Various studies have shown favourable results on intravenous administration of tranexamic acid in reducing intraoperative and postoperative bleeding. (24–25) We could therefore question the interest of a combined intraoperative and postoperative intravenous administration for our primary breast augmentations.

Finally, the strength of our study is in the use of tranexamic acid in breast surgery since 2014. It would be interesting to try to contact patients again, 10 years after their first surgery.

Conclusion:

Tranexamic acid is increasingly being used in surgery to limit intraoperative and postoperative bleeding. We have shown in this study that its administration in the immediate postoperative period significantly decreased the drainage volumes after breast augmentation with implants. There is therefore a benefit to its administration in reducing postoperative bleeding and related complications such as haematomas. In addition, there were no adverse

reactions associated with the administration of tranexamic acid, corroborating its safety in this indication.

Consent

As per university standard guideline, participant consent and ethical approval have been collected and preserved by the authors.

Ethical approval

All authors declare that 'written informed consent was obtained from the patient for publication of this case report and accompanying images. A copy of the written consent is available for review.

References:

1. Dunn CJ, Goa KL. Tranexamic acid: a review of its use in surgery and other indications. *Drugs*. 1999;57:1005–1032.
2. Dunn CJ, Goa KL. Tranexamic acid: a review of its use in surgery and other indications. *Drugs*. 1999 Jun;57(6):1005-32. doi: 10.2165/00003495-199957060-00017. PMID: 10400410.
3. Spear, S. L., and J. L. Baker. "Classification of Capsular Contracture after Prosthetic Breast Reconstruction." *Plastic and Reconstructive Surgery* 96, no. 5 (October 1995): 1119-23; discussion 1124.
4. Handel N, Jensen JA, Black Q, Waisman JR, Silverstein MJ. The fate of breast implants: a critical analysis of complications and outcomes. *PlastReconstrSurg* 1995;96(0032-1052 (Print):1521–33.
5. Sébastien LÊ, Julie JOSSE and François HUSSON. "FactoMineR: A Package for Multivariate Analysis". In: *Journal of Statistical Software* 25.1 (2008), pp. 1–18. DOI: 10.18637/jss.v0 25.i01.
6. Philippe MICHEL. *Baseph : un package pour les études cliniques simples (Baseph: a package for simple clinical studies)*. Pontoise, France, 2022. URL: <https://github.com/philippemichel/baseph>.
7. R CORE TEAM. *R : A Language and Environment for Statistical Computing*. R Foundation for Statistical Computing. Vienna, Austria, 2022. URL: <https://www.R-project.org/>.
8. Hadley WICKHAM et al. "Welcome to the tidyverse". In: *Journal of Open Source Software* 4.43 (2019), p. 1686. DOI: 10.21105/joss.01686.
9. KeianiMotlagh K, Loeb I, Legrand W, Daelemans P, Van Reck J. Prévention des saignements postopératoires chez des patients sous anticoagulants oraux. Effets de l'acidtranexamique [Prevention of postoperative bleeding in patients taking oral anticoagulants. Effects of tranexamic acid]. *Rev StomatolChirMaxillofac*. 2003 Apr;104(2):77-9. French. PMID: 12750624.
10. Ramirez RJ, Spinella PC, Bochicchio GV. Tranexamic Acid Update in Trauma. *Crit Care Clin*. 2017 Jan;33(1):85-99. doi: 10.1016/j.ccc.2016.08.004. PMID: 27894501.

11. Wang Q, Liu J, Fan R, Chen Y, Yu H, Bi Y, Hua Z, Piao M, Guo M, Ren W, Xiang L. Tranexamic acid reduces postoperative blood loss of degenerative lumbar instability with stenosis in posterior approach lumbar surgery: a randomized controlled trial. *Eur Spine J.* 2013 Sep;22(9):2035-8. doi: 10.1007/s00586-013-2836-z. Epub 2013 29 May. PMID: 23715891; PMCID: PMC3777047.
12. Ker K, Prieto-Merino D, Roberts I. Systematic review, meta-analysis and meta-regression of the effect of tranexamic acid on surgical blood loss. *Br J Surg.* 2013 Sep;100(10):1271-9. doi: 10.1002/bjs.9193. Epub 2013 9 Jul PMID: 23839785.
13. Ker K, Edwards P, Perel P, Shakur H, Roberts I. Effect of tranexamic acid on surgical bleedings: systematic review and cumulative meta-analysis. *BMJ* 2012; 344:e3054.
14. de Vasconcellos SJA, do Nascimento-Júnior EM, de Aguiar Menezes MV, Tavares Mendes ML, de Souza Dantas R, Martins-Filho PRS. Preoperative Tranexamic Acid for Treatment of Bleeding, Edema, and Ecchymosis in Patients Undergoing Rhinoplasty: A Systematic Review and Meta-analysis. *JAMA Otolaryngol Head Neck Surg.* 2018 Sep 1;144(9):816-823. doi: 10.1001/jamaoto.2018.1381. PMID: 30098161; PMCID: PMC6233636
15. McGuire C, Nurmsoo S, Samargandi OA, Bezuhly M. Role of Tranexamic Acid in Reducing Intraoperative Blood Loss and Postoperative Edema and Ecchymosis in Primary Elective Rhinoplasty: A Systematic Review and Meta-analysis. *Jama Facial Plast Surg.* 2019 May 1;21(3):191-198. doi: 10.1001/jamafacial.2018.1737. PMID: 30605219; PMCID: PMC6537831
16. Ausen K, Fossmark R, Spigset O, Pleym H. Randomized clinical trial of topical tranexamic acid after reduction mammoplasty. *Br J Surg.* 2015;102(11):1348-1353. doi:10.1002/bjs.9878
17. Rohrich RJ, Cho MJ. The role of tranexamic acid in plastic surgery: review and technical considerations. *PlastReconstr Surg.* 2018;141(2):507-515. doi:10.1097/00006534-200108000-00035
18. Headon H, Kasem A, Mokbel K. Capsular Contracture after Breast Augmentation: An Update for Clinical Practice. *Arch Plast Surg.* sept 2015;42(5):532-43.
19. Codner MA, Mejia JD, Locke MB, et al. A 15-year experience with primary breast augmentation. *PlastReconstrSurg* 2011;127(3):1300–10.
20. Handel N, Jensen JA, Black Q, Waisman JR, Silverstein MJ. The fate of breast implants: a critical analysis of complications and outcomes. *PlastReconstrSurg* 1995;96(0032-1052 (Print)):1521–33
21. Bachour Y, Bargon CA, de Blok CJM, Ket JCF, Ritt MJPF, Niessen FB. Risk factors for developing capsular contracture in women after breast implant surgery: A systematic review of the literature. *Journal of Plastic, Reconstructive & Aesthetic Surgery.* 2018 Sep 1;71(9):e29-48.
22. Ozdemir M, Leach GA, Kanapathy M, Mosahebi A, Reid CM. Keller Funnel Efficacy in "No Touch" Breast Augmentation and Reconstruction: A Systematic Review. *PlastReconstrSurg Glob Open.* 23 nov 2022;10(11):e4676.
23. Oliver JD, DeLoughery EP, Gupta N, Boczar D, Sisti A, Huayllani MT, et al. Local Pro- and Anti-Coagulation Therapy in the Plastic Surgical Patient: A Literature Review of the Evidence and Clinical Applications. *Medicina.* May 2019;55(5):208.

24. Balogh ZJ, King KL. Perspectives on tranexamic acid in surgery. *ANZ Journal of Surgery*. 2020;90(4):409-409.
25. Abboud NM, Kapila AK, Abboud S, Yaacoub E, Abboud MH. The Combined Effect of Intravenous and Topical Tranexamic Acid in Liposuction: A Randomized Double-Blinded Controlled Trial. *AesthetSurg J Open Forum*. Jan 2021;3(1):ojab002.
- 24 Handel N, Jensen JA, Black Q, James R. Waisman, Silverstein MJ. The Fate of Breast Implants: A Critical Analysis of Complications and Outcomes. *Plastic and Reconstructive Surgery*. Dec 1995;96(7):1521-33.
- 25 Ajdic D, Zoghbi Y, Gerth D, Panthaki ZJ, Thaller S. The Relationship of Bacterial Biofilms and Capsular Contracture in Breast Implants. *AesthetSurg J*. March 2016;36(3):297-309.
- 26 Dunn CJ, Goa KL. Tranexamic acid: a review of its use in surgery and other indications. *Drugs*. June 1999;57(6):1005-32.
- 27 Tang YMJ, Chapman TWL, Brooks P. Use of tranexamic acid to reduce bleeding in burns surgery. *J PlastReconstrAesthet Surg*. May 2012;65(5):684-6.
- 28 Cansancao AL, Condé-Green A, David JA, Cansancao B, Vidigal RA. Use of Tranexamic Acid to Reduce Blood Loss in Liposuction. *Plastic and Reconstructive Surgery*. May 2018;141(5):1132-5.
- 29 What is the evidence for tranexamic acid in Burns? - ScienceDirect [Internet]. [cited 8 Feb 2022]. Available at:
<https://www.sciencedirect.com/science/article/abs/pii/S0305417914001569?via%3Dihub>