

Successful laparotomy myomectomy during 2nd trimester of pregnancy: A Case report

Massive subserosal myomectomy at 19 weeks of gestation with successful pregnancy outcome: A Case report and literature review.

Comment [OF1]: Successful pregnancy outcome is more important than successful myomectomy. It's important to mention the site and size of myomas as it gives clear picture to the readers

Abstract:

Myomectomy during pregnancy is rarely performed as it carries high risk of intractable haemorrhage which might necessitate hysterectomy. Most Majority of myomectomies of cases are performed at the time of caesarean section or with a laparoscopic approach after pregnancy. We report a case of successful laparotomy myomectomy in 26 years old primigravida at 19 weeks of gestation who presented with acute abdominal pain, pelvic pressure symptoms and difficulty in breathing due to huge abdominal mass. Imaging revealed a large multiple sub-serous and intramural myomas extended to xiphoid sternum compressing the diaphragm and causing breathing embarrassment. Laparotomy myomectomy was performed successfully. The subsequent antenatal ultrasound showed short cervix of 0.5 cm, patient was offered cervical cerclage but she refused, so she was on conservative medical management with local and systematic progesterone support. Follow up was uneventful and she delivered vaginally at 37 weeks of gestation with no complications. This report supports the safety of myomectomy during pregnancy in selected scenarios.

Comment [OF2]: To make it concise

Comment [OF3]: The sentence is about surgery not the approach

Comment [OF4]: Imaging can't conclude about the cause of breathing embarrassment

Comment [OF5]: It's better to omit the offer for cerclage and follow up by cervical length as this is not supported by literature or if you have you need to provide in your introduction part. I would suggest this if the myoma is cervical and the procedure was in the cervix. Injectable Hydroxyprogesterone Caproate was administered can be included here.

Keywords: Pregnancy, leiomyoma, Myomectomy, live birth, 2nd trimester, miscarriage

Introduction:

The estimated prevalence of uterine myomas during pregnancy varies from 0.3 to 15%. [1] Uterine fibroids usually asymptomatic during pregnancy, but some time may be complicated by painful red degeneration, increased risk of spontaneous abortion, preterm labour, premature rupture of foetal membranes, antepartum haemorrhage, malpresentations, obstructed difficult labour, operative delivery such as caesarean section and postpartum haemorrhage. [2] In pregnancy about 10% of cases of uterine fibroids can lead to obstetrical complications depending on their size, location, and number [2, 3, 4]. The most common symptoms of uterine myomas are abdominal pain which is usually managed conservatively by analgesia; however, conservative medical management fails in 2% of patients. [1]

Expectant management of uterine fibroids during pregnancy is usually preferable approach and surgical intervention is generally postponed until after delivery in most cases due to the risk of excessive haemorrhage and obstetrical complications. [2] ~~Due to high risk of excessive haemorrhage and obstetrical complications~~, myomectomy is generally avoided during pregnancy. ~~Surgical intervention is usually reserved for patients having intractable abdominal pain not responding to available analgesia, or symptoms associated with degeneration and rapid growth of myoma.~~ [1]

Comment [OF6]: This sentence is repeated and not cited

Comment [OF7]: Need to be checked as this is an indication during reproductive period than during pregnancy

Only a few cases of antepartum myomectomy have been reported in the literature. [1] Spyropoulou K [6] conducted a systemic review of pregnant patients with uterine myomas. He found that the median gestational age at diagnosis was 13 weeks, while the median age at myomectomy was 16 weeks. Most of cases were sub serous pedunculated or sub serous and fundal. Laparotomy was the main surgical intervention in (78.4 %) of cases; although laparoscopic and vaginal operations were also reported. The median duration of surgery was 53 min. Necrosis and degeneration were the main findings of removed fibroids identified during histopathology examination. The pregnancy was successful in most of the cases, with few complications reported. [6]

Case presentation:

26 years old female primigravida at 19 weeks of pregnancy, admitted in Obstetrics and Gynaecology department in Royal Hospital in 2021 with history of intractable pelvic pain, abdominal discomfort, lower back pain and difficulty in breathing. ~~The Her~~ medical and surgical history ~~of the patient~~ was uneventful. Obstetrical examination showed a large firm and irregular abdomino-pelvic mass up to xiphoid sternum, with uterine fundal height of 40 weeks. Trans-Abdominal ultrasound confirmed a viable fetus corresponding to 19 weeks and multiple subserous large implant-myoma (largest 20x18 cm) and Magnetic resonance imaging (MRI) confirmed the diagnosis (Figure 1&2).

Comment [OF8]: Known she is female

Comment [OF9]: There is no more pelvic mass but abdomino-pelvic

Comment [OF10]: It has to be changed to trans-abdominal ultrasonography

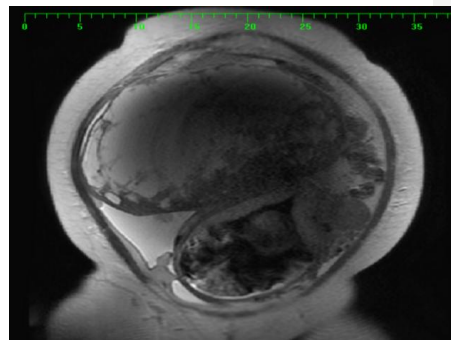
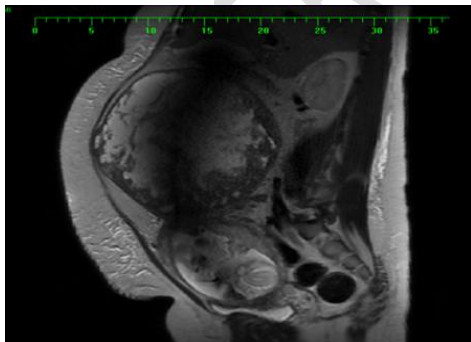


Figure 1 & 2: Sagittal T2 weighted MRI of the abdomen and pelvis showing a large well-defined heterogenous subserosal leiomyoma arising from the uterine fundus with predominantly high T2 signals. Gravid uterus with single fetus (partially showed).

Due to the huge myomas which was causing intractable acute abdominal pain laparotomy myomectomy was planned. Patient was extensively thoroughly counselled about the expected difficulties - anticipated risks with the operation like - risk of bleeding requiring - blood

Comment [OF11]: It's better to include to what medical management was tried and became intractable

transfusion, injuries to surrounding organs or vessels, risk of hysterectomy in case of un-control haemorrhage as lifesaving procedure, risk of miscarriage before 24 weeks of pregnancy and preterm labour if pregnancy continue. In view of volume and the location of the myomas and in order to be able to manage possible complications, midline laparotomy incision was chosen. After accurate operative field exposure, the huge myoma was removed (Figure 3&4). The operation took almost 2 hours' duration and estimated blood loss was 1500 ml.

Comment [OF12]: This sentence long need and I tried to change it

Comment [OF13]: Its better to talk about preoperative preparation like tocolytics if any.

Comment [OF14]: It's better to put this in discussion

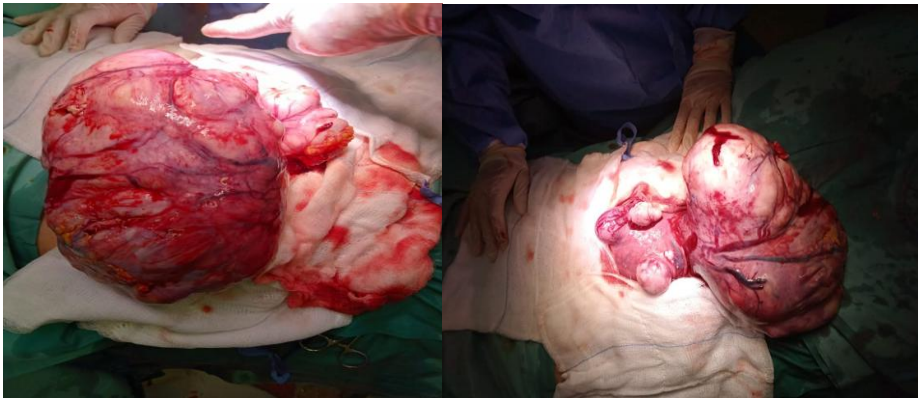


Figure 3&4: multiple sub serosal pedunculated fibroids with cystic changes, both tube and ovaries looks normal

Comment [OF15]: If you have a picture after removal of fibroid would be interesting to see the size of the base of the pedicle

Operative findings:

~~On laparotomy~~ After entering the abdomen gravid uterus with huge multiple sub-serosal pedunculated fibroids, largest arising from right fundal region of size 22x16x15cm with cystic changes and serous fluid and ~~Other one arising anterior lateral uterine sub-serosal fibroid 7x7 cm was identified.~~ Following leiomyoma ~~the removal~~ resection of the 2 kilograms of myoma, haemostasis was carefully achieved secured and ~~sample~~ The myomas weighing total of 2 kg was sent for histopathology examination. Patient ~~received~~ was transfused with 2 units of blood intra-operatively and ~~one third unit of blood~~ postoperatively operation. She was ~~given~~ ~~received~~ intravenous antibiotic for 3 days and injectable Hydroxyprogesterone Caproate was administered intramuscularly post operation to prevent a possible miscarriage. Patient was discharged post operation day three in good condition with oral antibiotic (cefuroxime) for 5 days, low molecular heparin for 10 days and was on weekly injection Hydroxyprogesterone Caproate till 34 weeks of gestation. She was seen day 10 post operation for clip removal, was asymptomatic and fetal ultrasound showed normal growing fetus. The histopathology report showed leiomyomata with degenerative changes associated with pregnancy. Focal mild cellular atypia and infarct type necrosis seen.

Comment [OF16]: It's better to be specific (the type of antibiotic)

Discussion

To the best of our knowledge the first case of intrapartum laparotomy myomectomy was from Latin America in 2000, 2nd from Nigeria in 2003 and then other cases reported subsequently in years 2010, 2011, 2013, 2016 (1, 2, 3) and last cases reported in a systemic review published in August 2020 include 97 cases. [6]

Laparotomic myomectomy is usually avoided during pregnancy due to higher risk of complication and effect on ongoing pregnancy. [1] Most cases are usually performed during a caesarean section at the end of the pregnancy if clinically indicated. Antepartum myomectomy has been performed in selected cases of acute unmanageable abdominal pain that does not respond to analgesic therapy or suspected torsion of the subserous pedunculated myomas or in cases of respiratory depression due to rapid abnormal increase in myoma size. [1] Other advantage of antepartum myomectomy observed is reversal of fetal complications such as oligohydramnios, fetal postural deformity and intrauterine growth restriction. [9]

Pawan Jhalta [3] found in his study that the risks of miscarriage with myomectomy occurs in 18% to 35% of cases. [3] The increased risk of miscarriage was attributed to the increase in uterine contractions, degeneration, and growth of myoma. Lolis [1] study reported that success rate of antepartum myomectomy reaching to 92. [1] Around 15-20% of women with myomas had preterm delivery, 10% had restriction fetal growth and 20% had malpresentation. [1, 8] Mollica [3] study concluded that regardless of gestational age, the outcomes for all women who underwent myomectomy was superior to those managed conservatively in terms of pregnancy loss (0% versus 13.6%), premature rupture of membranes (5.6% versus 22.7%), preterm labour (5.6% versus 21.6%) and post-caesarean hysterectomy (0% versus 4.5%). [3] [7]

Myomectomy during pregnancy can be performed by laparotomy or laparoscopy technique depending on the volume and location of fibroids. Laparoscopy done in selected cases (small, subserous pedunculated myomas). Advantage of laparoscopy myomectomy it is less invasive, minimal postoperative pain, earlier postoperative ambulation [1]. Two cases are reported in the literature with large pedunculated myomas operated by the vaginal route. [1]

This case and other reported cases demonstrates that myomectomy during pregnancy in special circumstances can be considered to prevent complication affecting mother and fetus.

Comment [OF17]: Discussion need major revision and it's better to discuss about your case discussion part is looking like introduction: why it reaches such big, why you didn't give tocolytics, why do you offer cerclage, etc. If intrauterine growth restriction is one of the complication what is the outcome of delivery in your case. Try to compare your intraoperative difficulties (bleeding) with other case reports.

Conclusions

Surgical management of uterine myomas during pregnancy can be successfully performed by expert surgeons in selected cases. Antepartum myomectomy should be performed only if unavoidable weighing risk and benefit of the operation on mother and fetus. In selected patients it could prevent miscarriage or an unacceptable obstetrical outcome. The surgical approach should be tailored to the patient and to the characteristics of the myoma. Surgical procedure should be done by expert surgical and anaesthesiologic team and in tertiary centres

Comment [OF18]: Repeated at the bottom it better to be omitted

in order to reduce risk of complications. This report highlights the safety of myomectomy during pregnancy in selected circumstances.

Declaration (this issues has to be adressed)

Ethical approval:

Informed consent:

Availability of data and material:

Funding:

Competing of interest:

References:

- (1). Domenici, L., Di Donato, V., Gasparri, M., Lecce, F., Caccetta, J. and Panici, P. Laparotomic Myomectomy in the 16th Week of Pregnancy: A Case Report. *Case Reports in Obstetrics and Gynecology*, 2014, pp.1-5.
- (2). Umezurike, C. and Feyi-Waboso, P. Successful myomectomy during pregnancy : A case report. *Reproductive Health*, 2005. 2(1).
- (3). Jhalta, P., Negi, S. and Sharma, V. Successful myomectomy in early pregnancy for a large asymptomatic uterine myoma: case report. *Pan African Medical Journal*, 2016, 24.
- (4). Allameh, T. and Allameh, Z. Successful Myomectomy in the Second Trimester of Pregnancy. *Advanced Biomedical Research*, 2019 , 8(1), p.60.
- (5). Ardovino, M., Ardovino, I., Castaldi, M., Monteverde, A., Colacurci, N. and Cobellis, L.,. Laparoscopic myomectomy of a subserous pedunculated fibroid at 14 weeks of pregnancy: a case report. *Journal of Medical Case Reports*, 2011,5(1).
- (6). Spyropoulou, K., Kosmas, I., Tsakiridis, I., Mamopoulos, A., Kalogiannidis, I., Athanasiadis, A., Daponte, A. and Dagklis, T. Myomectomy during pregnancy: A systematic review. *European Journal of Obstetrics & Gynecology and Reproductive Biology*, 2020 ,254, pp.15-24.
- (7). Basso, A., Catalano, M., Loverro, G., Nocera, S., Di Naro, E., Loverro, M., Natrella, M. and Mastrolia, S. Uterine Fibroid Torsion during Pregnancy: A Case of Laparotomic Myomectomy at 18 Weeks' Gestation with Systematic Review of the Literature. *Case Reports in Obstetrics and Gynecology*, 2017, pp.1-11.

(8).E. Danzer, W. Holzgreve, C. Batukan, P. Miny, S. Tercanli, and I. Hoesli, "Myomectomy during the first trimester associated with fetal limb anomalies and hydrocephalus in a twin pregnancy," *Prenatal Diagnosis*,2001, vol. 21, no. 10, pp. 848–851,.

(9). Leach, K., Khatain, L. and Tocce, K.First trimester myomectomy as an alternative to termination of pregnancy in a woman with a symptomatic uterine leiomyoma: a case report. *Journal of Medical Case Reports*, 2011, 5.

UNDER PEER REVIEW