

## Massive subserosal myomectomy at 19 weeks of gestation with successful pregnancy outcome: A Case report and literature review.

### Abstract:

Antenatal myomectomy is rarely performed as it carries high risk of intractable haemorrhage and hysterectomy. Majority of myomectomies are performed at the time of caesarean section or after pregnancy. We report a case of successful laparotomy myomectomy in 26 years old primigravida at 19 weeks of gestation who presented with acute abdominal pain, pelvic pressure symptoms and difficulty in breathing due to huge abdominal mass. Imaging revealed a large multiple sub-serous and intramural myomas extended to xiphoid sternum compressing the diaphragm. Laparotomy myomectomy was performed successfully. The subsequent antenatal ultrasound showed short cervix of 0.5 cm. Patient was on follow up with cervical length assessment and was on injectable Hydroxyprogesterone Caproate. Antenatal period was uneventful and she delivered vaginally at 37 weeks of gestation with no complications. This report supports the safety of myomectomy during pregnancy in selected scenarios.

Keywords: Pregnancy, leiomyoma, Myomectomy, live birth, 2<sup>nd</sup> trimester, miscarriage

### Introduction:

The estimated prevalence of uterine myomas during pregnancy varies from 0.3 to 15%. [1] Uterine fibroids usually asymptomatic during pregnancy, but some time may be complicated by painful red degeneration, increased risk of spontaneous abortion, preterm labour, premature rupture of foetal membranes, antepartum haemorrhage, malpresentations, obstructed difficult labour, operative delivery such as caesarean section and postpartum haemorrhage. [2] In pregnancy about 10% of cases of uterine fibroids can lead to obstetrical complications depending on their size, location, and number [2, 3, 4]. The most common symptoms of uterine myomas are abdominal pain which is usually managed conservatively by analgesia; however, conservative medical management fails in 2% of patients. [1]

Expectant management of uterine fibroids during pregnancy is usually preferable approach and surgical intervention is generally postponed until after delivery in most cases due to the risk of excessive haemorrhage and obstetrical complications. [2] Surgical intervention is usually reserved for patients having intractable abdominal pain not responding to available analgesia, or symptoms associated with degeneration. [1]

Comment [AH1]: Antenatal

Comment [AH2]: abdominal myomectomy (laparotomy)

Comment [AH3]: sometimes it

Comment [AH4]: [2-4]

Comment [AH5]: Conservative

Only a few cases of antepartum myomectomy have been reported in the literature.[1]To the best of our knowledge the first case of antepartum laparotomy myomectomy was from Latin America in 2000, 2nd from Nigeria in 2003 and then other cases reported subsequently in years 2010, 2011 ,2013, 2016 (1,2, 3)and then cases reported in a systemic review published in August 2020 include 97 cases.[6]

Comment [AH6]: [1-3]

Comment [AH7]: this number may be 5, not 6.

### Case presentation:

26 years old primigravida at 19 weeks of pregnancy, admitted in Obstetrics and Gynaecology department in Royal Hospital in 2021with history of intractable pelvic pain, abdominal discomfort, lower back pain and difficulty in breathing.Hermedical and surgical history was uneventful. Obstetrical examination showed a large firm and irregular abdominal mass up to xiphoid sternum, with uterine fundal height of40weeks.Trans-abdominal ultrasonography confirmed a viable fetus corresponding to 19 weeks and multiple subserous large myoma (largest 20x18 cm) and Magnetic resonance imaging (MRI) confirmed the diagnosis (Figure 1&2).

Comment [AH8]: Figures

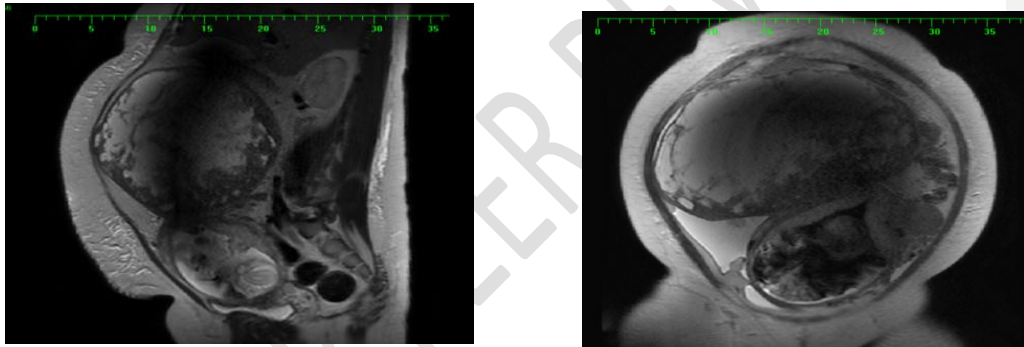


Figure 1& 2: Sagittal T2 weighted MRI of the abdomen and pelvis showing a large well-defined heterogenous subserosal leiomyoma arising from the uterine fundus with predominantly high T2 signals. Gravid uterus with single fetus (partially showed).

Comment [AH9]: Please, separate the two figures & write a legend for each one.

Due to the huge myomas which was causing significantacute abdominal pain, not responding to morphine and pethidine, laparotomy myomectomy was planned. Patient was thoroughlycounselled aboutrisk of procedure bleeding,blood transfusion,injuries to surrounding organs or vessels, risk of hysterectomy in case of un-control haemorrhage as lifesavingprocedure,risk of miscarriageand preterm labour if pregnancy continue.So patient had laparotomy with infra umbilical midline incision.After accurate operative field exposure, the huge myoma was removed (Figure 3&4). The operation took almost 2 hours' duration and estimated blood loss was 1500 ml.

Comment [AH10]: Figures

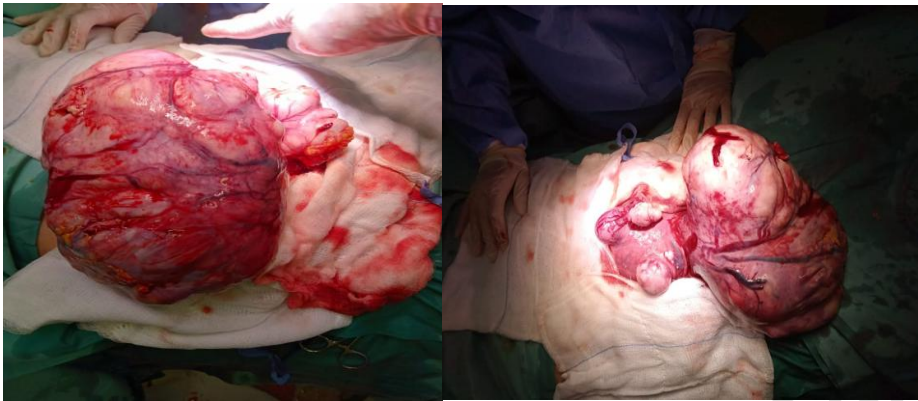


Figure 3&4: multiple sub serosal pedunculated fibroids with cystic changes, both tube and ovaries looks normal

**Comment [AH11]:** Please, separate the two figures & write a legend for each one.

### Operative findings:

After entering the abdomen gravid uterus with huge multiple sub-serosal pedunculated fibroids, largest arising from right fundal region of size 22x16x15cm and Other arising antero-lateral uterine 7x7 cm was identified. Following the resection of the 2 kilograms of myoma haemostasis was carefully secured and sample was sent for histopathology examination. Patient was transfused with two units of blood intra-operatively and third unit postoperatively with estimated blood loss of 1500 ml. She was given intravenous cefuroxime for 3 days and injectable Hydroxyprogesterone Caproate was administered intramuscularly post operation to prevent a possible miscarriage. Patient was discharged post operation day three in good condition with oral antibiotic (cefuroxime) for 5 days, low molecular heparin for 10 days and was on weekly injection Hydroxyprogesterone Caproate till 34 weeks of gestation. She was seen day 10 post operation for clip removal, was asymptomatic and fetal ultrasonography showed normal growing fetus. The histopathology report showed leiomyomata with degenerative changes associated with pregnancy. Focal mild cellular atypia and infarct type necrosis seen.

**Comment [AH12]:** Please, add photography of histopathology.

**Comment [AH13]:** Please add the obstetric history after fibroid removal. You can also discuss why the birth occurred at 37 weeks and whether it was vaginal or via CS. This is because the uterus has scarring and is vulnerable to rupture during vaginal delivery.

### Discussion

The current changes in social cultural aspect toward marriage and the tendency to delay the age of pregnancy had led to increase in the frequency of pregnant women with uterine fibroid in recent years. [10] Our Patient was 26 years old primigravida, at 19 weeks of gestation, not known to have fibroid before pregnancy and this is matching with available reports published that the age of the patients ranged from 21 to 44 years old, while at least 30 % of them were primigravida. [10] The diagnosis of the existing myoma was made up to 26 weeks of gestation and the symptoms prior to diagnosis were mainly severe abdominal pain, that did

not respond to analgesic therapy. [10] In most of the patients the myomas were subserous which is the scenario of our patient. Reports showed that the gestational age at which the myomectomy was performed, was from 8 weeks up to 26 weeks [10] and our patient was 19 weeks of gestation.

Regarding the type of surgery, in 60 cases, a laparotomy was chosen, while only 10 patients were subjected to laparoscopy. There was also one case of a submucous fibroid that was excised through the vaginal route. [10] The size of myomas was measured from 4 to 40 cm and they weighed 95 g up to 10,000 g. The operating time and intraoperative blood loss ranged from 30 to 150 minutes and 30–4500 mL, respectively. [10] Our patient had myoma of size 22x16 cm, weighing 2killogram.

Laparotomic myomectomy is usually avoided during pregnancy due to higher risk of complication and effect on ongoing pregnancy, [2] But in our patient as it was huge fibroid with significant pain and pressure symptoms not responding to analgesia, Patient underwent laparotomy myomectomy by midline infra-umbilical incision as fibroid was fundal and huge in size. The operation was complicated by blood loss of around 1500 ml, which is expected and reported in case of myomectomy in general. [1] No bladder or vessels injuries occurred as patient had no operations before and no adhesions. Anti natal patient did not received any kind of tocolytic apart from Analgesia, review of literature did not suggest such intervention and all reported cases of antepartum myomectomy none received tocolysis [11], on follow up by ultrasonography, fetus growth was within normal, but cervix noticed to be short so patient was offered cervical cerclage she refuse, although the current guideline not recommend cervical cerclage in no history of previous 2nd trimester or previous preterm delivery [14], and patient was on injectable hydroprogesterone caproate till 34 weeks of gestation. Patient had spontaneous vaginal delivery which was **un eventful**. Although some recommendation advice to perform Caesarean section on women who underwent myomectomy during pregnancy, due to fear of intrauterine rupture of the uterus. [12] However Babunashvili EL [11] study reported that more than half (54.2%) of the women included in his series had vaginal delivery with no complication and he recommend evaluation of myomectomy scar to be done, and thickness of 2 mm consider as a safety margin to allow trial of vaginal delivery. [11]

Comment [AH14]: uneventful

Maternal outcomes were mostly favourable after myomectomy. [10] Our patient had successful full term vaginal delivery with good outcome, she delivers male baby with weight 2.7 kg with good Apgar score 8&9 at 5&10 minutes. Diakosavvas M [11] reported that three cases of aborted foetuses directly postoperatively, 68 women delivered from 29 to 41 weeks of gestation. [11] The neonate weights ranged from 1606 to 4460 g. The neonate outcomes of the 70 newborns (66 singleton pregnancies and two twin pregnancies) were excellent, besides one newborn with internal hydrocephalus with Apgar scores of 9, 10 and 10 at 1, 5 and 10 minutes, respectively, and one other infant with complete absence of the right hand directly above the wrist at delivery. Notably, out of the 68 gestations that resulted in the delivery of a newborn, 59 reached term and just nine ended preterm (before 37th week of gestation), while only two foetuses had to be delivered before the 34th week. All women that delivered prematurely had underwent myomectomy through laparotomy [10]

On the other hand, Pawan Jhalta [3] found in his study that the risks of miscarriage with myomectomy occurs in 18% to 35% of cases. [3] The increased risk of miscarriage was attributed to the increase in uterine contractions, degeneration, and growth of myoma. Lolis [1] study reported that success rate of antepartum myomectomy reaching to 92. [1] Around 15-20% of women with myomas had preterm delivery, 10% had restriction fetal growth and 20% had malpresentation. [1, 8] Mollica [3] study concluded that regardless of gestational age, the outcomes for all women who underwent myomectomy was superior to those managed conservatively in terms of pregnancy loss (0% versus 13.6%), premature rupture of membranes (5.6% versus 22.7%), preterm labour (5.6% versus 21.6%) and post-caesarean hysterectomy (0% versus 4.5%).[3][7][13]

All reported case support that the advantage of antepartum myomectomy observed is reversal of fetal complications such as oligohydramnios, fetal postural deformity and intrauterine growth restriction.[9]This case and other reported cases demonstrates that myomectomy during pregnancy in special circumstances can be considered to prevent complication affecting mother and fetus.

Comment [AH15]: cases

## Conclusions

Antepartum myomectomy should be performed only if unavoidable weighing risk and benefit of the operation on mother and fetus. In selected patients it could prevent miscarriage or an unacceptable obstetrical outcome. The surgical approach should be tailored to the patient and to the characteristics of the myoma. Surgical procedure should be done by expert surgical and anaesthesiologic team and in tertiary centres in order to reduce risk of complications. This report highlights the safety of myomectomy during pregnancy in selected circumstances.

## Declaration (this issue has to be addressed)

**Ethical approval:**obtained

**Informed consent:**informed consent taken.

**Availability of data and material:**all references up to date, images provided

**Funding:**no Funding

**Competing of interest:**No conflicts of interest.

## References:

- (1). Domenici, L., Di Donato, V., Gasparri, M., Lecce, F., Caccetta, J. and Panici, P. Laparotomic Myomectomy in the 16th Week of Pregnancy: A Case Report. *Case Reports in Obstetrics and Gynecology*, 2014, pp.1-5.
- (2). Umezurike, C. and Feyi-Waboso, P. Successful myomectomy during pregnancy : A case report. *Reproductive Health*, 2005. 2(1).
- (3). Jhalla, P., Negi, S. and Sharma, V. Successful myomectomy in early pregnancy for a large asymptomatic uterine myoma: case report. *Pan African Medical Journal*, 2016, 24.
- (4). Allameh, T. and Allameh, Z. Successful Myomectomy in the Second Trimester of Pregnancy. *Advanced Biomedical Research*, 2019 , 8(1), p.60.
- (5). Ardovino, M., Ardovino, I., Castaldi, M., Monteverde, A., Colacurci, N. and Cobellis, L.,. Laparoscopic myomectomy of a subserous pedunculated fibroid at 14 weeks of pregnancy: a case report. *Journal of Medical Case Reports*, 2011,5(1).
- (6). Spyropoulou, K., Kosmas, I., Tsakiridis, I., Mamopoulos, A., Kalogiannidis, I., Athanasiadis, A., Daponte, A. and Dagklis, T. Myomectomy during pregnancy: A systematic review. *European Journal of Obstetrics & Gynecology and Reproductive Biology*, 2020 ,254, pp.15-24.
- (7). Basso, A., Catalano, M., Loverro, G., Nocera, S., Di Naro, E., Loverro, M., Natrella, M. and Mastrolia, S. Uterine Fibroid Torsion during Pregnancy: A Case of Laparotomic Myomectomy at 18 Weeks' Gestation with Systematic Review of the Literature. *Case Reports in Obstetrics and Gynecology*, 2017, pp.1-11.
- (8). E. Danzer, W. Holzgreve, C. Batukan, P. Miny, S. Tercanli, and I. Hoesli, "Myomectomy during the first trimester associated with fetal limb anomalies and hydrocephalus in a twin pregnancy," *Prenatal Diagnosis*, 2001, vol. 21, no. 10, pp. 848–851,.
- (9). Leach, K., Khatain, L. and Tocce, K. First trimester myomectomy as an alternative to termination of pregnancy in a woman with a symptomatic uterine leiomyoma: a case report. *Journal of Medical Case Reports*, 2011, 5.
- (10). Diakosavvas M, Angelou K, Fasoulakis Z, Kathopoulos N, Zacharakis D, Blontzos N, Antsaklis P, Haidopoulos D, Daskalakis G, Rodolakis A, Theodora M. Myomectomy during pregnancy; diagnostical dilemmas: two case reports and a systematic review of the literature. *J Obstet Gynaecol*. 2022 Jul;42(5):757-765
- (11). Babunashvili EL, Son DY, Buyanova SN, Schukina NA, Popov AA, Chechneva MA, Glebov TA, D'Amato A, Haydamous J, Chiantera V, Laganà AS, Etrusco A. Outcomes of Laparotomic Myomectomy during Pregnancy for Symptomatic Uterine Fibroids: A Prospective Cohort Study. *J Clin Med*. 2023 Oct 8;12(19):6406
- (12). Fuchs A, Dulaska A, Sikora J, Czech I, Skrzypulec-Plinta V, Drosdzol-Cop A. Symptomatic uterine fibroids in pregnancy - wait or operate? Own experience. *Ginekol Pol*. 2019;90(6):320-324
- (13). Anniyappa, Saravana; Havaldar, Nusrat A.1.; Purra, Pallavi. Antenatal myomectomy. *Saudi Journal for Health Sciences* 4(2):p 138-140, May–Aug 2015

**Comment [AH16]:** Please write all references in the same style, especially with regard to number of volume, issue and pages.

(14). Green-top Guideline No. 75 , Cervical Cerclage, published 24 February 2022 .

UNDER PEER REVIEW