

Three years follow-up of endodontic microsurgical combined with orthograde retreatment of Oehler's Type III Dens Invaginatus: a case report

ABSTRACT

This report describes the management of an unusual case of dens invaginatus in a 48-year-old female patient. Cone beam computed tomography and pre-operative periapical radiograph showed the presence of type III dens invaginatus with inadequate obturation, poor apical seal, and presence of periapical lesion related to maxillary lateral incisor. The case was managed successfully by a combination of nonsurgical and microsurgical endodontic retreatment. Orthograde endodontic retreatment was performed using rotary files and calcium hydroxide paste as intracanal medication for one week, then the root canal was obturated using thermoplasticized guttapercha and a sealer. One week later, microsurgery was done. After 3 years follow up, absence of periapical radiolucency and satisfactory healing were observed. Microsurgical retrograde with orthograde retreatment of dens invaginatus preserve the entire tooth. It should be considered to promote periapical healing with complete reconstitution of bone and periodontal ligament regeneration without signs of recurrence over a period of 3 years.

Keywords: Cone beam CT, Dens invaginatus, Microsurgical endodontics, Periapical lesion, Retreatment.

Introduction

“Dens invaginatus is a developmental dental anomaly characterized by the invagination of the dental papilla before the mineralization stage, resulting in the formation of a lateral or accessory canal within the tooth”. [1] “The precise etiology of DI remained unclear, but it tends to include genetic and environmental factors. Numerous theories have been suggested, including infection, trauma, changes in tissue pressure, or local discrepancies in cellular hyperplasia” [2]. “Nevertheless, the exact etiology is still indistinct. Dens invaginatus is a considerably common condition, its incidence is between 0.3% and 10% in all teeth, with maxillary lateral

incisors being the most commonly affected, followed by the maxillary central incisors, but it is rarely found in the mandibular incisor” [3, 4]. “Multiple classification systems for dens invaginatus have been proposed, including dens in dentes, dentoids in dentes, invaginated odontomes, and dilated composite odontomas, but the most widely used and clinically relevant classification system was proposed by Oehlers” [5, 6]. “This classification system divides invagination into three types, according to the depth of enamel invagination observed radiographically. In type I, there is minimal invagination that is limited to the crown; in type II, the invagination extends beyond the cemento-enamel junction (CEJ) in the form of a blind sac. In type III, the invagination invades throughout the root, laterally extends to the periodontal tissues, penetrates through the root, and apically opens in the periapical tissues but does not communicate with the pulp. Hence, infection in a type III invagination could result in an inflammatory response within the periodontium and periapical tissues, leading to periapical periodontitis” [7, 8]. Endodontic treatment of dens invaginatus can be challenging because of the complex anatomy of the tooth, and treatment failure is common. This case report describes a 48-year-old female patient who had failed endodontic treatment before for Oehler's Type III dens invaginatus. The patient reported a periapical lesion on the maxillary lateral incisor, which had previously undergone endodontic treatment twice, 10 and 5 years ago, respectively. Despite previous treatments, a repeated intraoral fistula appeared buccally with pain on percussion.

Case Description:

A 48-year-old female patient with no relevant medical, family or psychosocial history was reported with chief complaint of dull pain and discomfort in the maxillary lateral incisor, tooth number #22 (According to FDI system), and repeated fistula on the buccal gingiva opposite to its root apex. The patient claimed that endodontic treatment was done on the tooth 10 years ago, however due to persistent infection, endodontic retreatment was performed again on the same tooth after 5 years (in year 2009). Upon clinical examination, a recurrent intraoral fistula appeared on the buccal mucosa, exacerbated by pain on percussion and grade I mobility. Despite previous treatments, the patient continued to experience pain and discomfort in the affected tooth.

Radiographic examinations showed periapical radiolucency as well as an invagination which had a central invaginated canal extending from the pulp chamber throughout the apical foramen in the maxillary lateral incisor with

inadequate root canal filling (Figure 1). This type of anatomy was consistent with a **dens invaginatus** Odhlers type III. Cone-beam computed tomography (CBCT) (Vatech, Pax-i3D Smart, Korea) was taken at standardized settings (90 kV, 6 mA, 5 cm × 5 cm, 18 s) as a complementary examination to reach an accurate diagnosis and to assess the information on periapical lesion extent and the proximity to anatomic structures. The preoperative measurements of the lesion extent were viewed **in the sagittal section** (Figure 2). The CBCT images showed an invagination of the lateral incisor extending from the crown throughout to the root canal apex; but, it **did not** communicate with the main root canal. The apical foramen was incomplete and had a periapical radiolucency of approximately 2.2×3.8 mm (Figure 2). **An inadequate root canal filling with inadequate apical seal, can lead to endodontic treatment failure due to micro leakage along the root canal walls with the appearance of an apical lesion.**

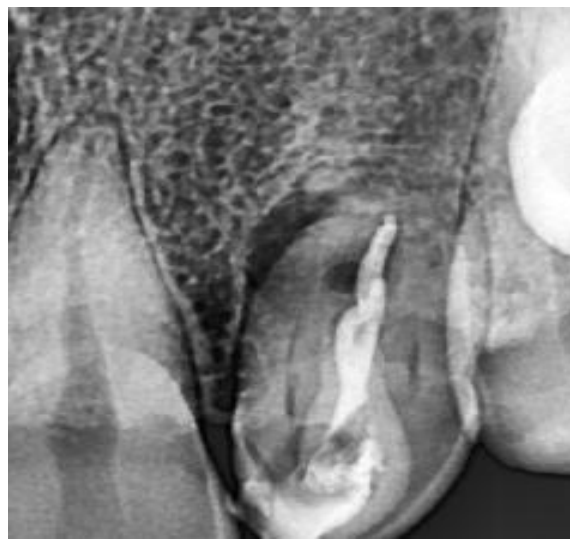Therapeutic interventions:

Orthograde retreatment combined with endodontic microsurgery was planned for **the treatment of maxillary lateral incisor**. The patient was informed about the risks and benefits of the **procedure, and written consent was obtained.**

Local anesthesia (2% lidocaine with **1:100,000** epinephrine) was administered. **followed by single tooth rubber dam isolation.** The access cavity was opened using round carbide bur #008 (LusterDent, France). **Gutta-percha** was removed from the coronal area with a gates glidden size #2 (VDW, Munich). The previous **root canal filling in the middle third was eliminated by brushing H files ISO #30 (FKG Dentaire, Switzerland) in an up and down against the root canal wall.** The H file was **used again in the same manner for the apical section with adding gutta-percha solvent** (Eucaliptol, Maquira Industry of Dental Products, Brazil). A periapical radiograph was performed to confirm the complete removal of the gutta-percha. The canal was mechanically prepared utilizing rotary instruments (A3 Azure, endostar Ni-Ti rotary files taper 0.04, Poland). The working length (WL) was 20mm, which was validated both by the apex locator (Geosoft, Russia) and periapical **radiograph** (Figure 3). Apical gauging was performed with a 0.02 manual K-file NiTi ISO 80, yielding a diameter of 0.80 mm for the apical foramen. Between each instrument change, the root canal was irrigated with 5ml of Dual Rinse HEDP solution. According to the manufacturer's instructions, a Dual Rinse HEDP-based solution was made by mixing 10 mL of 3% NaOCl with one capsule of Dual Rinse etidronic acid (HEDP) powder (Medcem, GmbH, Vienna,

Austria) using a syringe with a 28gauge side vented needle. The depth of the irrigation needle was 2 mm from the apex. In addition, an ultrasonic activation (Woodpecker, UDS K (LED), China) was applied to attain a more effective debridement. Paper points were used to dry the invaginated canal, followed by the application of calcium hydroxide paste, and temporary filling material (Cavition; GC Co., Tokyo, Japan) to seal the access cavity. After one week, upon examination, no abnormality detected and the previous fistula has been resolved. Copious irrigation using Dual Rinse HEDP solution and ultrasonic activation were used to remove the intracanal medication. After that, paper points were applied to dry the invaginated canal, which was then obturated using thermoplasticized guttapercha and a sealer (Meta Biomed, Korea). Finally, the access cavity was sealed using GIC and composite resin (Z350; 3M ESPE, St Paul, MN, USA).

One week after that, on her third visit, the microsurgery was done under the dental operating microscope DOM (Zumax, China) with magnification 1.2x. After administration of local anesthesia using 2% lidocaine with 1: 100,000 epinephrine, crevicular and vertical releasing incisions were done followed by reflection of a full-thickness flap. The granulation tissue surrounding the root apices was thoroughly removed using an ultrasonic piezo scalpel (US4, SOGA, Shenzhen Soga technology co., Ltd, China), the following parameters were set: 120 VA, working frequency 30KHZ, with physiological saline for cooling, revealing the extent of bone loss. Apicoectomy was done by removing 3 mm from the root apex of #22, using piezoelectric device tips XM-NINJA (SOGA, Shenzhen Soga technology co., Ltd, China), then retrograde cavity preparation was performed using ultrasonic tips (UE2) and retrograde filling was added using Mineral Trioxide Aggregate (MTA Angelus® Brazil), Figure (4). "Surgical site was irrigated with normal saline 0.9%, flap approximated, and sutured with 4-0 nylon suture (Ethicon; Johnson & Johnson). Antibiotics and nonsteroidal inflammatory drugs as well as 2% chlorhexidine mouthwash were prescribed". [29]



**Fig. 1: Initial periapical radiograph showing a poor quality
Obturation with periapical radiolucency**

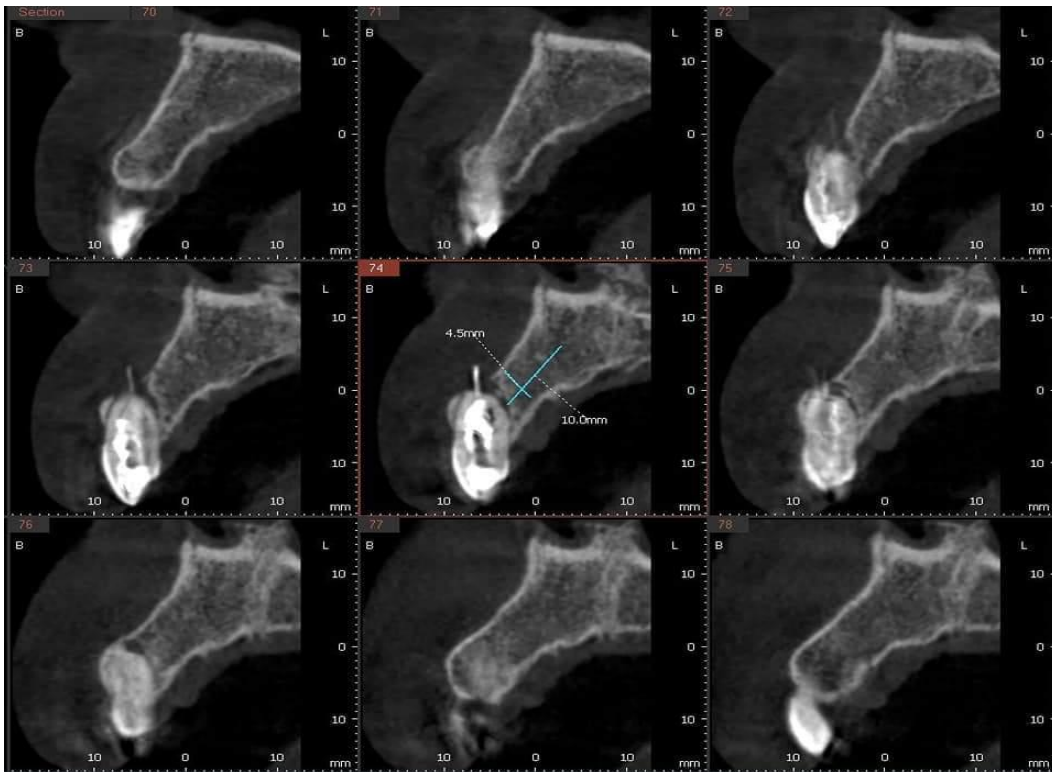


Fig. 2: Cone Beam Computed Tomography: Sagittal view

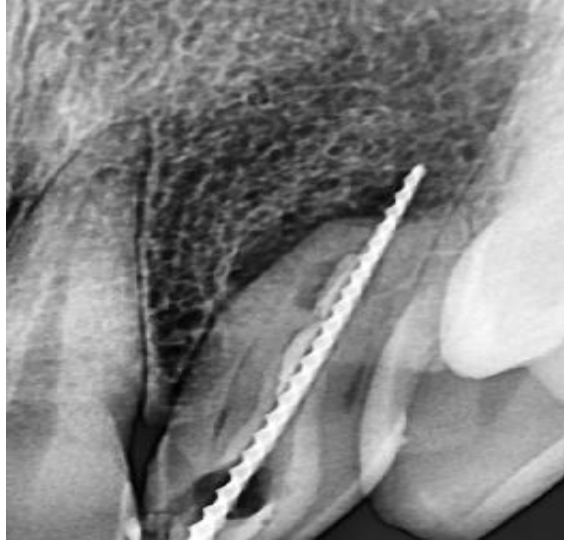


Fig. 3: working length determination

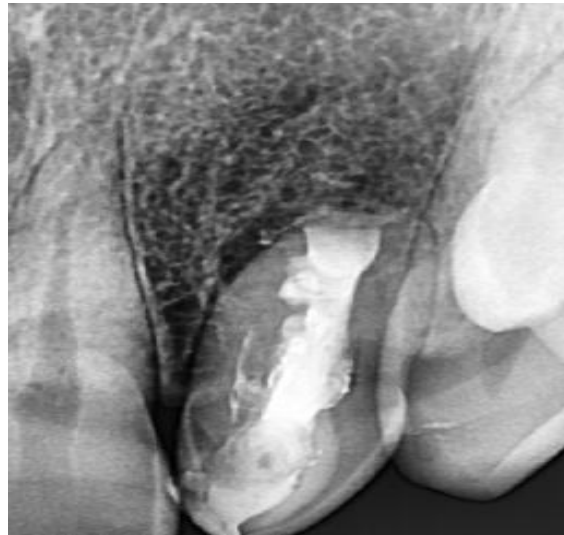
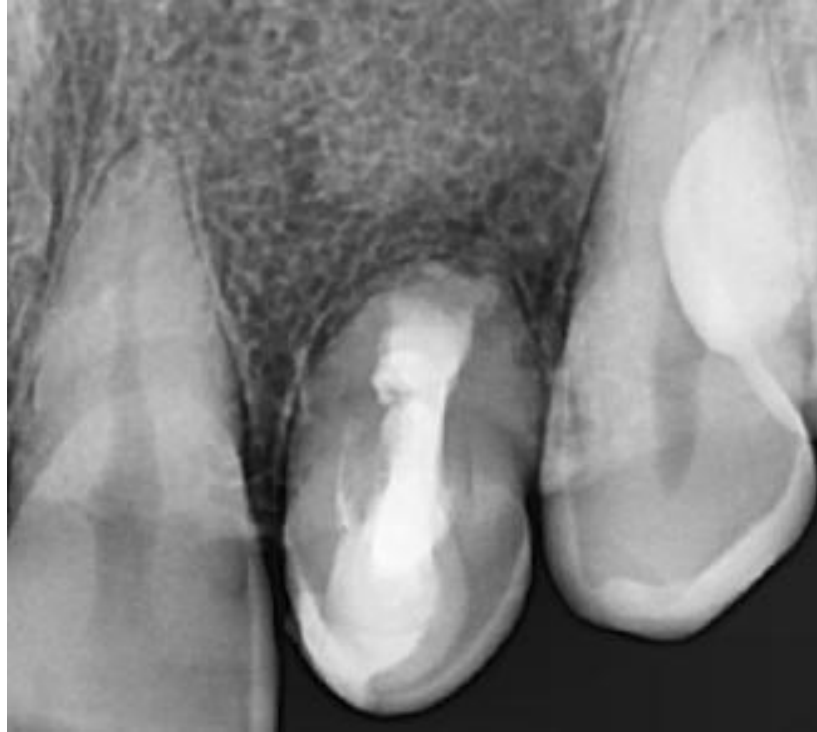

Fig. 4: Periapical radiograph after root canal obturation

Follow-up and Outcomes:

The patient was followed-up **one week post-surgery and the sutures were removed.** On palpation, the gingiva was smooth with no discomfort. The tooth's **mobility** was within physiological limitations (Grade I). **Follow-up appointments were scheduled after six months, one-, two- and three-years.** It showed **satisfactory healing on the radiograph (Figure 5).**



(Figure 5): satisfactory healing of periapical lesion

Discussion:

Dental anomalies such as Dens Invaginatus (DI) exhibit a wide range of morphologic changes and can lead to dental caries, pulpitis, and apical periodontitis in more severe cases [9, 10]. According to this case report, “Oehler's Type III Dens Invaginatus is the most severe form of the anomaly, characterised by a deep infolding of the enamel and dentin in the affected tooth that extends into the root and forms a pseudo foramen to communicate laterally with the periodontal space” [11, 12]. “The enamel lining in these defects is frequently hypomineralized and incomplete with various channels that communicate with the pulp thereby allowing easy access for irritants from the invagination to reach the pulp space” [13, 14]. “Treatment options include preventive sealing of the invaginated pit in teeth that are asymptomatic as well as regular evaluations. Endodontic therapy of the invaginated area alone or of the invaginated section and the root canal has been recommended in cases of pulp necrosis” [15]. When nonsurgical methods fail to address significant periapical lesions or when gaining a coronal access prevents nonsurgical treatment, surgical endodontics should be considered in addition to conventional endodontics. The apical part of the invagination and/or root canal will

be disinfected and retrogradelysealed during surgery, eliminating the possibility of an infection source [9, 16–20]. Because Type III DI is frequently linked to modifications in the root canal's morphology, endodontic procedures are challenging because of the abnormal anatomy in the invaginated track and pulp space. Furthermore, as this case report illustrates, if the invagination expands into the periodontal space (Figure 1), there may not be a real apical constriction, which adds to the complexity of endodontic procedures [9, 17]. “Cases of DI with its complicated anatomy always pose a diagnostic and treatment challenge to the clinician. Due to the intrinsic limitations of the conventional radiographs, they are unable to reveal the details of the DI three-dimensionally. In cases of DI, CBCT images show the details in terms of type, extension, and morphologic changes in the tooth” [21, 22]. “CBCT uses low effective radiation dose and besides generating undistorted 3D reconstruction of the teeth and surrounding soft tissues provides interrelational images in three orthogonal planes: axial, sagittal, and coronal” [23, 24]. “Based on these CBCT images we decided to retreat the main root canal with nonsurgical endodontic therapy and do a surgical endodontic approach with retrograde filling for the apical portion of the invagination. A similar combination of conventional and surgical endodontics has also been reported” in a case report by Vier-Pelisser et al. [25]. Since calcium hydroxide's high alkalinity promotes healing in necrotic teeth with periapical lesions, it was utilised as an intracanal medication in the root canal for a week. Even though MTA has been the preferred root end material, It was first developed for the endodontic treatment of root perforations. Nevertheless, MTA application has grown over time [26]. Because of its bioactive qualities, excellent sealing ability, antibacterial effect, and osseointegrative and conductive power that promotes tissue regeneration when it comes into touch with the pulp and periradicular tissues, it is currently regarded as the gold standard [27]. Moreover, it is readily detectable on control radiographs due to its radiopacity[28].

Conclusion:

Endodontic treatment of dens invaginatus can be challenging because of the complex anatomy of the tooth. Orthograde retreatment combined with endodontic microsurgery have been successful for a 3 years period, showing a satisfying results and outcome.

Consent

As per international standards or university standards, patient(s) written consent has been collected and preserved by the author(s).

Ethical Approval:

As per international standards or university standards written ethical approval has been collected and preserved by the author(s).

References:

- [1] Alani A, Bishop K. Densinvaginatus. Part 1: classification, prevalence and aetiology. *IntEndod J.* 2008;41(12):1123–36.
- [2] Zhu J, Wang X, Fang Y, Von den Hof JW, Meng L. An update on the diagnosis and treatment of dens invaginatus. *Aust Dent J.* 2017;62(3):261–75.
- [3] Hamasha AA, Alomari QD. Prevalence of dens invaginatus in Jordanian adults. *IntEndod J.* 2004;37(5):307–10.
- [4] Zhang P, Wei X. Combined therapy for a rare case of type III densinvaginatus in a mandibular central incisor with a periapical lesion: a casereport. *J Endod.* 2017;43(8):1378–82.
- [5] Kirzioglu Z, Ceyhan D. The prevalence of anterior teeth with densinvaginatus in the western Mediterranean region of Turkey. *IntEndod J.* 2009;42(8):727–34.
- [6] Oehlers FA. Dens invaginatus (dilated composite odontome). I. Variations of the invagination process and associated anterior crown forms. *OralSurg Oral Med Oral Pathol.* 1957;10(11):1204–18.
- [7] Carvalho-Sousa B, Almeida-Gomes F, Gominho LF, Albuquerque DS. Endodontic treatment of a periradicular lesion on an invaginated type III mandibular lateral incisor. *Indian J Dent Res.* 2009;20(2):243–5.
- [8] Keles A, Cakici F. Endodontic treatment of a maxillary lateral incisor with vital pulp, periradicular lesion and type III dens invaginatus: a case report. *IntEndod J.* 2010;43(7):608–14.
- [9] M. Hulsmann, “Dens invaginatus: aetiology, classification, prevalence, diagnosis, and treatment considerations,” *IntEndod J.* 1997;30(2):79–90.

- [10] A. Alani and K. Bishop, "Dens invaginatus. Part 1: classification, prevalence and aetiology," *IntEndod J.* 2008; 41(12):1123–1136.
- [11] W. G. Shafer, M. K. Hine, and B. M. Levy, *Shafer's Textbook of Oral Pathol*, section I, Elsevier, 6th edition, 2009.
- [12] F. A. C. Oehlers, "Dens invaginatus (dilated composite odontome): I. Variations of the invagination process and associated anterior crown forms," *Oral SurgOral Med Oral Pathol.* 1975;10(11): 1204–1218.
- [13] M. Yamada, M. Nagayama, A. Katsumata et al., "Hypomineralized Enamel of Dens Invaginatus: its distinct images and pathogenesis of the type III invagination using micro-focusing computed tomography," *JHard Tissue Biol.*2014; 23(4):449–453.
- [14] K. T. Ceyhanli, D. C. elik, S. H. Altintas, T. Tas, demir, and O. "Sezgin, "Conservative treatment and follow-up of type III dens invaginatus using cone beam computed tomography," *JOral Scien.* 2014;56(4): 307–310.
- [15] A. H. Borges, A. S. Segundo, M. R. Nadalin, F. L. M. Pedro, A.M. D. Filho, and M. D. Sousa-Neto, "Conventional treatment of maxillary incisor type III dens Invaginatus with periapical lesion: a case report," *ISRN Dentistry*, 2011, Article ID 257609, 5 pages.
- [16] K. Bishop and A. Alani, "Dens invaginatus. Part 2: clinical, radiographic features and management options," *IntEndod J* 2008;41(12):1137–1154.
- [17] U. X. da Silva Neto, V. H. G. Hirai, V. Papalexiou et al., "Combined endodontic therapy and surgery in the treatment of dens invaginatus type 3: case report," *JCanadian DentAssoc.* 2005;71(11): 855–858.
- [18] E. R. Fregnani, L. F. B. Spinola, J. R. O. Sonogo, C. E. S. Bueno, and A. S. De Martin, "Complex endodontic treatment of an immature type III dens invaginatus. A case report," *IntEndod J.* 2008;41(10): 913–919.
- [19] H. Ozbas, "Rustem Kemal Subay, MelikeOrdulu, Surgical Retreatment of an invaginated maxillary central incisor following overfilled endodontic treatment," *Euro JDent.* 2010; 4: 324.
- [20] G. Sauveur, F. Roth, M. Sobel, and Y. Boucher, "Surgical treatment of a periradicular lesion on an invaginated maxillary lateral incisor (dens in dente)," *IntEndod J.* 1997;30(2):145–149.

- [21] H. Kato, "Non-surgical endodontic treatment for dens Invaginatus type III using cone beam computed tomography and dental operating microscope: a case report," *The BullTokyoDentCol.* 2013;54(2):103–108.
- [22] D. D. A. Decurcio, J. A. Silva, R. D. A. Decurcio, R. G. Silva, and J. D. Pecora, "Influence of cone beam computed tomography on dens invaginatus treatment planning," *DentPress Endod.* 2011;1(1): 87–93.
- [23] C. William Scarfe, M. D. Levin, D. Gane, and G. Allan Farman, Use of cone beam computed tomography in endodontics. *InterJDent.*2009, Article ID 634567,20 pages.
- [24] S. Patel, A. Dawood, T. Pitt Ford, and E. Whaites, "The potential applications of cone beam computed tomography in the management of endodontic problems," *IntEndod J.* 2007;40(10): 818–830.
- [25] F. V. Vier-Pelisser, R. D. Morgental, G. Fritscher, A. C. Ghisi, M.G. de Borba, and R. K. Scarparo, "Management of type III dens invaginatus in a mandibular premolar: a case report," *Brazilian Dent J.* 2014;25(1):73–78.
- [26] Agrafioti A, Tzimpoulas N, Chatzitheodoridis E, Kontakiotis EG. Comparative evaluation of sealing ability and microstructure of MTA and Biodentine after exposure to different environments. *Clin Oral Investig.* 2016; 20:1535–40.
- [27] Aydemir S, Cimilli H, Gemi PM, Bozkurt A, Orucoglu H, Chandler N. Comparison of the sealing ability of Biodentine, Iroot BP Plus and mineral trioxide aggregate. *CDJ.* 2016;19:166–71.
- [28] Biočanin V, Antonijević Đ, Poštić S, Ilić D, Vuković Z, Milić M. Marginal gaps between 2 calcium silicate and glass ionomer cements and apical root dentin. *J Endod.* 2018; 44:816–21.
- [29] Jie Zhang, Yuan Wang, Lei Xu, Zhifang Wu, Yan Tu. Treatment of type III dens invaginatus in bilateral immature mandibular central incisors: a case report. 2022 Feb 4;22(1):28