

EARLY AND INTENSIVE MANAGEMENT IN CHEMICAL EYE INJURIES OF EYE: PREVENTING BLINDNESS CASE SERIES

Comment [OY1]: OF

1) ABSTRACT:-

Chemical injuries of the eyes are true ophthalmic emergencies causing significant visual morbidities. Most chemical injuries are due to acid and alkali compounds with the latter being more common. The extent of chemical injuries depends on several factors like the strength of the chemical agents, concentration, volume of solution and duration of exposure.

2) INTRODUCTION:-

ALKALI: -Ammonia and sodium hydroxide causes the most serious alkali injuries which as these chemicals penetrate immediately into the eyes producing serious anterior segment damage. However, Lime or calcium hydroxide is the most common cause of alkali injury which after traversing the epithelial cell membrane forms calcium salt which precipitate and prevents further deeper penetration.

Comment [OY2]: Kindly reference these statements.

ACID: -Sulfuric, sulfurous, hydrofluoric, acetic, chromic and hydrochloric acids are the most common acids substances producing acid injury, out of which hydrofluoric acid is the most serious.

Comment [OY3]: Please reference

PATHOPHYSIOLOGY:-

Alkali have more penetrate more ion than acid. Alkali causes fatty acid saponification and disruption in cell membrane causing cell death. Hydration of glycosaminoglycans in the corneal stroma leads to loss of clarity of the stroma. Hydration of collagen fibrils leads to thickening and shortening which distorts trabecular meshwork and releases prostaglandins, leading to raised intraocular pressure. Intraocular structures such as iris, ciliary body and trabecular meshwork may be affected depending on the degree of penetrance and the pH of aqueous. Sometimes there may be ciliary shutdown leading to hypotony. Nonhealing of corneal epithelial defect, inflammation, release of proteolytic enzymes, tear deficiency and impaired collagen synthesis can lead to stromal ulceration and melt. Type 1 collagenase breaks down collagen molecule leading to corneal ulceration which is inhibited by epithelial cytokines, highlighting the importance of intact epithelium. Within 12-24hrs after chemical injury, infiltration of peripheral cornea with PMN and monocytes occurs due to chemotactic attraction by cellular proteins released from necrotic tissues.

In acid injuries there is protein precipitation and denaturation in the corneal epithelium and superficial stroma producing ground glass appearance of epithelium. This prevents deeper penetration of acid. However, in cases of strong acids there is deeper penetration which causes similar effects as seen in alkali injury.

Comment [OY4]: These need to be referenced appropriately

3) METHODOLOGY:-

Grading the severity of ocular chemical injuries according to two standard classification system and managing the condition accordingly.

Comment [OY5]: This is not methodology at all. This is simply grading of chemical eye injury

Table 1. ROPER-HALL CLASSIFICATION:-

Comment [OY6]: Ensure to reference the sources of the classifications/ grading

GRADE	CORNEA	LIMBUS	PROGNOSIS
1	Corneal epithelial damage	No limbal ischemia	Good
2	Corneal haze, iris details visible	<1/3 rd limbal ischemia	Good
3	Stromal haze, iris details obscured	1/3-1/2 limbal ischemia	Guarded
4	Opaque cornea, iris and pupil obscured	>1/2 limbal ischemia	Poor

Table 2.DUA CLASSIFICATION:-

GRADE	PROGNOSIS	CLOCK HOURS OF LIMBAL INVOLVEMENT	CONJUNCTIVAL INVOLVEMENT	ANALOGUE SCALE
I.	Very good	0	0%	0/0%
II.	Good	<=3	<30%	0.1-3/1-30%
III.	Good	3-6	30-50%	3-6/30-50%
IV.	Good to guarded	7-9	51-75%	6.1-9/51-75%
V.	Guarded to poor	9-11	76-99%	9.1-11/76-99%
VI.	Poor	12	100%	12/100%

4) CASE SERIES:-

CASE 1

A 31Y female patient, presented to OPD after injury with Holicolor. Her complaints were-

- Severe pain in both eyes
- Pricking sensation
- Watering both eyes
- Sudden diminution of vision both eyes

As per history given by patient, her children accidentally spilled Holicolor in her both eyes while she was doing her household chores.

Comment [OY7]: What is the duration of the complaints?

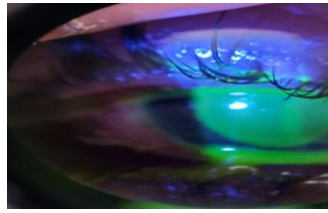


Fig 1. RIGHT EYE with diffuse F stain positive

Table 3. Variation in parameters among right and left eye (Case 1)

	Right eye	Left eye
VISUAL ACUITY	5/60	6/36
LIDS	Both upper and lower lid edema with cilia matted with discharge , reduced IPA	Both upper and lower lid edema
CONJUNCTIVA	Grade 2 chemosis with both circumcorneal and conjunctival congestion with perilimbal ischemia from 9- 1 o clock position	conjunctival congestion
CORNEA	On fluorescein staining entire cornea showed F stain positive sparing only temporal 3mm of cornea from limbus and inferior 1mm from limbus	Bright with F stain negative.
ANTERIOR CHAMBER	Depth normal, content clear	Depth normal, content clear
IRIS	Iris details fairly visible	Brown in color, normal in pattern
PUPIL	Central, circular brisk reactive to light	Central, circular brisk reactive to light
LENS	Transparent	Transparent

Comment [OY8]: F is not an acceptable abbreviation for fluorescein

Comment [OY9]: How about the picture of the left eye?

Comment [OY10]: What is the full meaning of IPA?

Comment [OY11]: What of the disc findings?

Comment [OY12]: Are the visual acuities unaided at entry, with pin hole or best correction

How was case 1 managed? This should be highlighted before proceeding to case 2

CASE 2:-

A female patient, 57y old visited with a/h/o acid thrown into her both eyes at home by her husband, with complaints as under of:

- 1) Sudden diminution of vision in both eyes
- 2) Pain with burning sensation in both eyes
- 3) Inability to open both eyes
- 4) Watering of both eyes

Comment [OY13]: a/h/o is not acceptable.

Comment [OY14]: Duration please?

Table 4. Variation in parameters among right and left eye (Case 2)

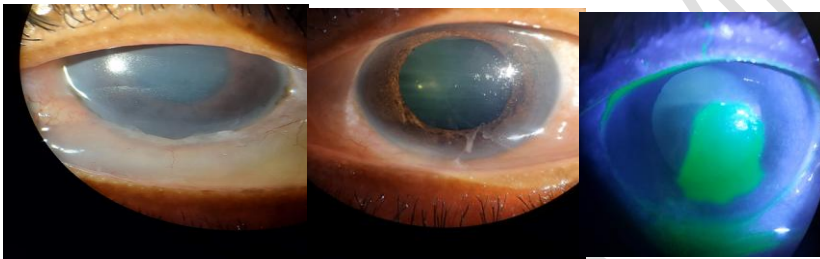
	RIGHT EYE	LEFT EYE
VISUAL ACUITY	CF1m	4/60
EXTERNAL	Both upper and lower lid edema	Both upper and lower lid edema
CONJUNCTIVA	Chemosis grade 2 with 360 ° limbal ischemia	Circumcorneal+ conjunctival congestion
CORNEA	Diffuse stromal edema with fair visibility of iris details, F stain negative	Epithelial defect appx 6*5mm
ANTERIOR CHAMBER	Normal depth	Normal in depth and content
IRIS/PUPIL	3mm, sluggishly reactive to light	Normal brisk reactive to light
LENS	Early IMSC	Early IMSC

Comment [OY15]: The dimension of the epithelial defect is in what direction? Horizontal, vertical or diagonal?

Comment [OY16]: appx, F are not acceptable abbreviations

Comment [OY17]:

Comment [OY18]: What are the funduscopy findings?



RIGHT EYE

LEFT EYE

Fig 2. Acid thrown into both eyes

5) RESULT EXAMINATION AND MANAGEMENT-

Case 1

Copious saline irrigation done to neutralize the pH for around 30 min.

Comment [OY19]: What was the grading of the injuries in case 1?

Comment [OY20]: Any lid eversion done? What was the ph after irrigation?

Systemic medication started in form of-

1. Tab Doxycycline 100mg BD
2. Tab Vitamin C 500mg QID
3. Tab Ciprofloxacin 500mg BD
4. Tab Pantoprazole 40mg OD

Locally (RE)

Patching done by eye ointment Atropine+ ocupol (Chloramphenicol + Polymixin B) + Panthegel

Locally (LE)

1. E/D Prednisolone Acetate 1% 6/ day
2. E/D Moxifloxacin 0.5% 1hrly

Comment [OY21]: E/D is not a standard abbreviation

3. E/D Homatropine 2% TDS
4. E/D Brimonidine+ Timolol BD
5. E/D Sodium Hyaluronate 2hrly
6. E/D CMC 1% 6/day

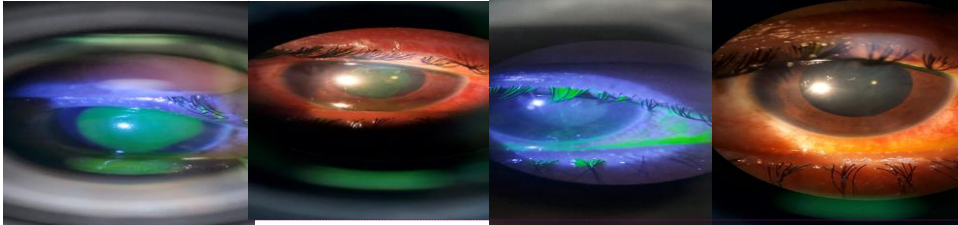


Fig 3. Improvement in ocular condition in successive days as treatment progressed

Comment [OY22]: What is CMC?

Comment [OY23]: Kindly label the eyes, right or left?

Comment [OY24]: How many days after treatment commencement?

Table 5. OCULAR EXAMINATION AFTER 1 WEEK:-

	Right eye	Left eye
VISUAL ACUITY	6/36 with pinhole correction 6/18 BCVA- -0.75 DSP 6/6	6/36 with pinhole correction 6/12 BCVA -0.75DSP 6/6
LIDS	Both upper and lower lid edema (decreased than earlier)	Normal lid and cilia
CONJUNCTIVA	Mild congestion with regaining of vasculature around limbus.	Clear
CORNEA	Nebulomacular opacity as thin line from center to 6 o'clock position, F stain negative	Cornea appeared bright
ANTERIOR CHAMBER	Depth normal, content clear	Depth normal, content clear
IRIS	Brown in color, normal in pattern	Brown in color, normal in pattern
PUPIL	Dilated, fixed, nonreactive under effect of atropine.	Semidilated under mydriatics
LENS	Transparent	transparent
FUNDUS (BE)	Media Clear, CDR 0.3, Disc margin well defined, B/V & B/G appear Normal, FR (+)	

Comment [OY25]: What does cornea appeared bright mean?

Comment [OY26]: What is B/V, B/G?

Case 2-

1. Copious irrigation with normal saline was done at the time of presentation for 30min.
2. Injectable antibiotics (~~inj~~-Ceftriaxone 1g I.V. BD)
3. Tab. Doxycycline 100mg BD
4. Tab. Vitamin C 500mg QID with plenty of water
5. Tab. Acetazolamide 250mg BD

RE

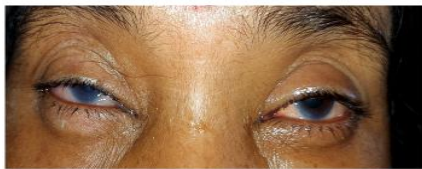1. E/d Prednisolone acetate 1% 1hrly
2. E/d moxifloxacin 0.5% 1hrly
3. E/d atropine TDS
4. E/d Brimonidine+ Timolol BD
5. E/d sodium hyaluronate 2hrly

Comment [OY27]: E/d is not a standard abbreviation

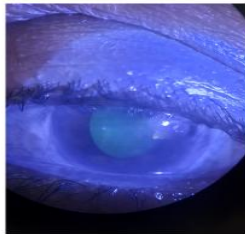
LE

Overnight Patching with eye ointment ocupol (chloramphenicol with polymyxin-B) with atropine ointment and panthegel.

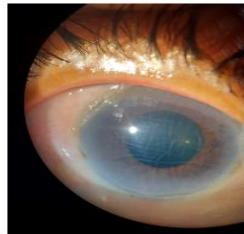2 days after the initiation of treatment:-



Reduction in both eyes lid edema with improvement in eye opening

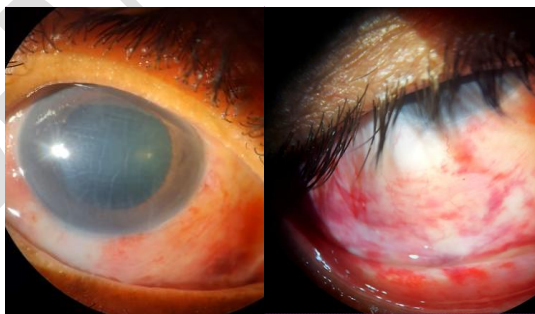

Healed epithelial defect of left eye



Significant improvement in corneal edema and chemosis

DAY 6



Comment [OY28]: Kindly label the eyes please

Fig 4. Post operative measure

Comment [OY29]: Are you implying post-operative appearance?

RE

1. Anterior Segment Ischemia with maximum visual acuity of 6/60.

2.Perilimbal ischaemia with conjunctival necrosis with multiple petechial subconjunctival haemorrhage.

3.Diffuse corneal edema with Descemet's folds

DAY 25-

Patient developed RE dendritic keratitis for which tab Acyclovir 400mg BD and eye ointment acyclovir 5/day was started and eyedrop Prednisolone was stopped.




Fig 5. Patient later developed right eye secondary glaucoma.

6)DISCUSSION:-

-In my study on chemical ocular injury, my first case had grade 3 chemical injury in her right eye with grade 1 chemical injury in her left eye. She showed good improvement in her vision and her symptoms with active management.

-My second case sustained grade 4 chemical injury in her right eye with grade 2 chemical injury in her left eye. With active management, **there was improvement in the symptoms and vision in her left eye improved both in vision and signs** but her right eye developed anterior segment ischemia with secondary glaucoma with best corrected visual acuity of 6/60. Even with thorough treatment, due to severe grade of injury, right eye developed complications and reduced vision.

In a rare case report on ocular chemical injury by **Deeksha Rani et al in 2020**, they reported about **a 5-year-old boy** with the history of lime falling into the left eye. Immediate management included **saline wash and lime particle removal was done**. On presentation, visual acuity in the **right eye was 20/20** and in the left eye was hand movements. On slit-lamp examination, the left eye showed **360 degrees patchy limbal blanching with mucous discharge**. The cornea was hazy with **deep stromal infiltration measuring (3x5) mm** in the superior part of the cornea. It was a severe ocular chemical burn that was graded as **Grade IV burn** as per Roper-Hall Classification and **Grade VI** as per Dua's Classification. **The donor cornea patch was harvested and sutured to the host bed using 10-0 monofilament nylon**. Amniotic membrane graft (AMG) was placed with the epithelial side down and adhered using fibrin glue. AMG was supported at the limbus and lid margin using 8-0 polyglactin suture.

In **another** case report by **Mayur Anil Patil et al in 2022** at Dr.D.Y.Patil Medical College, Hospital and research centre, Pimpri, they reported about a **11-year-old male patient who came to the ophthalmology OPD with complaints of loss of vision in the left eye for 5 days**. The patient gave a history of trauma to the left eye by a chemical explosive from a carbide gun, after which the patient developed diminution of vision in the left eye for 5 days. The patient was diagnosed with

Comment [OY30]: Reference?

Comment [OY31]: Reference?

grade 4 chemical injury in her left eye with total epithelial defect, corneal haze with 270degree limbal ischemia. The patient underwent amniotic membrane transplantation and simple limbal epithelial transplantation. After the surgery patient showed drastic improvement.

7)CONCLUSION:-

Ocular chemical injuries are one of the most important ocular emergencies, constituting a significant proportion of all traumas. To minimize sequelae, prompt and accurate treatment in the early period and successful adequate prevention and management of complications in the long term are essential. Chemical ocular injuries have significant psychological, physical, and economic effects, especially since serious injuries can cause permanent blindness. The distribution and severity of ocular chemical injuries worldwide vary according to socio-economic conditions, as in all other traumas.

9) REFERENCES:-

- i. Akgun Z, Selver OB. Epidemiology and etiology of chemical ocular injury: A brief review. *World J Clin Cases*. 2023 Feb 26;11(6):1245-1251. doi: 10.12998/wjcc.v11.i6.1245. PMID: 36926138; PMCID: PMC10013112.
- ii. Eslani M, Baradaran-Rafii A, Movahedan A, Djalilian AR. The ocular surface chemical burns. *J Ophthalmol*. 2014;2014:196827
- iii. Sharma N, Kaur M, Agarwal T, Sangwan VS, Vajpayee RB. Treatment of acute ocular chemical burns. *SurvOphthalmol*. 2018;63:214–235
- iv. Rani D, Sharma N, Sinha R, *et al*. A rare presentation of ocular lime injury *BMJ Case Reports CP* 2020;13:e235889.
- v. Patil MA, Alapati A, Paranjape R, Kilari S, Bora S, Garlapati AG, Palimar MP, Singh VD, Naik KS, Chaudhary NS. A case of ocular chemical injury. *Int J Med Rev Case Rep*. 2022; 6(11): 84-88. doi:10.5455/IJMRCR.172-1646767808

Comment [OY32]: This has no page numbers

Comment [OY33]: Kindly maintain Times new roman font size 12