

Case report

SONAL'S U BONDED SPACE MAINTAINER- A CASE REPORT

Abstract:

Premature loss of the primary teeth is a common occurrence in children. The safest way to prevent future malocclusions is to place a space maintainer that is effective, durable and economical. Of the various fixed space maintainers, the band and loop space maintainer are one of the most frequently used appliances, but it has various shortcomings like extensive laboratory work, minimum two visit for final delivery, patient compliance, etc. In view of all these limitations, a new bonded space maintainer is being fabricated, which can be delivered in a single sitting and it also eliminates number of fabrication steps. This innovative appliance saves a lot of time both for patient and for dentist and may be proven as a good alternative to the conventional band and loop space maintainer.

Key-words: primary dentition, space maintainer, band and loop space maintainer and bonded space maintainer.

INTRODUCTION

An intact arch and adequate space for permanent teeth are preserved by a healthy primary dentition. Primary teeth are crucial for a child's growth and development since they not only help with speaking, chewing, appearance, and the avoidance of undesirable habits, but they also act as a natural space maintainer for the permanent teeth that will eventually replace them^[1]. Premature loss of primary teeth, particularly the molars, is thought to eventually cause crowding in the dental arches, alterations in the circumference of the arch, mesial drifting of the posterior teeth, and potentially inadequate space for the eruption of the permanent teeth^[2, 3,4].

Dental caries is frequently cited as the leading cause of primary teeth that fall out too soon, nevertheless other factors such as trauma, ectopic eruption, congenital diseases, and inadequate arch length can also be accountable^[5]. By retaining the primary teeth in the arch until their natural time of exfoliation, these issues can be avoided in the best possible way^[6]. Diverse eating habits make kids more prone to dental caries and cause the early loss of primary teeth, necessitating treatment whenever indicated. In case of unsalvageable crown which is indicated for extraction, the safest approach to maintain arch space and to prevent

future malocclusion is by placing an effective, inexpensive, and long lasting space maintainer.^[7]

It is recommended to place a space maintainer immediately following tooth loss because the greatest degree of tooth displacement occurs within 6 months.[9]Premature tooth loss causes a permanent tooth to be positioned improperly in that quadrant in about 51% of cases for first primary molars and 70% of cases for second primary molars. [10]Maintaining mesio-distal relations in the employed dental arch is the most important role of space maintainers. With space maintainers, complex orthodontic treatment is put off and the eruption of the permanent teeth is guided.Space maintenance is an indispensable part of Paediatric Dentistry and is the primary preventive orthodontic care that is provided to avoid future dental anomalies. [8]

Depending on the dental growth stage of the kid, the affected dental arch, the number of teeth involved, and the position and kind of primary teeth involved, many types of appliances can be utilised as space maintainers. [9]In paediatric dentistry, the conventional band and loop space maintainer is the most often used space maintainer. They do, however, have a number of drawbacks, including cement dissolution, soldering failure (SF), side-line band deterioration, and lengthy assembly. Additionally they also have limitations such as:

1. Requiring at least two appointments
2. Impression making in uncooperative children or children with a gag reflex.
3. Technique sensitive during different stages like band displacement during cast pouring.
4. The fabrication requires a lot of laboratory work and effort, including soldering twice, which is one of the major reasons for the appliances failure.

Taking into account all these limitations, a novel design called “SONAL’S U BONDED SPACE MAINTAINER” is being explained in this article. This appliance can be delivered in a single sitting, it also eliminates a number of fabrication steps like impression making, band transfer and laboratory procedures like soldering. It saves a lot of time both for the dentist and for the patient and may be proven as a good alternative to the conventional band and loop SM.

FABRICATION AND DELIVERY OF SONAL’S U BONDED SPACE MAINTAINER:

- Thorough oral prophylaxis is done.
- The abutment tooth is etched with 37% orthophosphoric acid, followed by rinsing (15 second) and air drying (15second).
- Dentin bonding agent is applied and light cured for 15 second.
- A Begg’s orthodontic bracket is bonded horizontally with the help of ortho composite on the buccal aspect of the abutment teeth and cured for 20 second.
- Using a 0.033” (21 gauge) stainless steel wire, a ‘U’ shaped loop is prepared.
- The size of ‘U’ loop is kept universal i.e same for every patient, the length is kept 6 mm and the width is kept 7 mm.

- Excess wire is cut when adapting the loop according to patient's size of extraction site.
- The prepared loop is inserted in the Begg's bracket and is secured with composite button on both the ends.

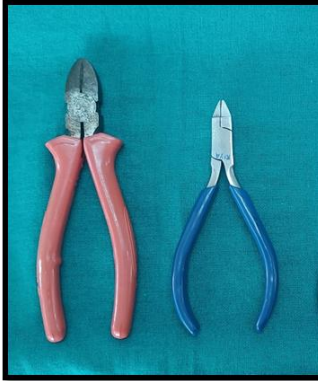

Fig 1. ARMAMENTARIUM

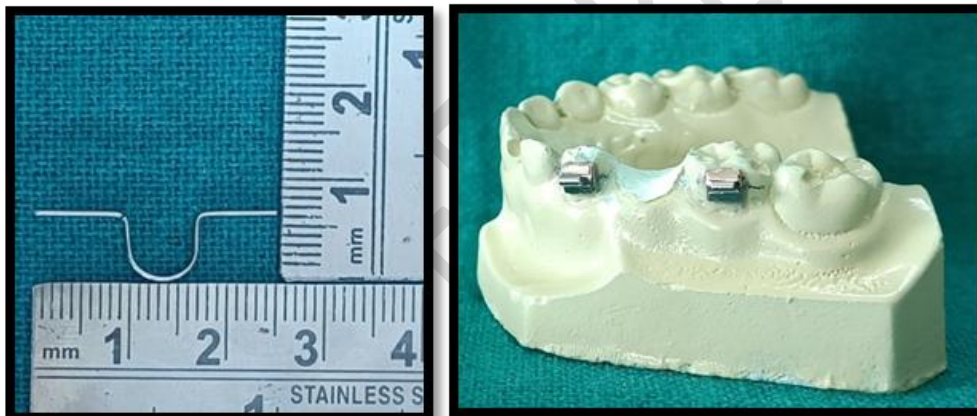


Fig 2. 'U' LOOP, L=6 mm;

Fig 3. BEGG'S BRACKET

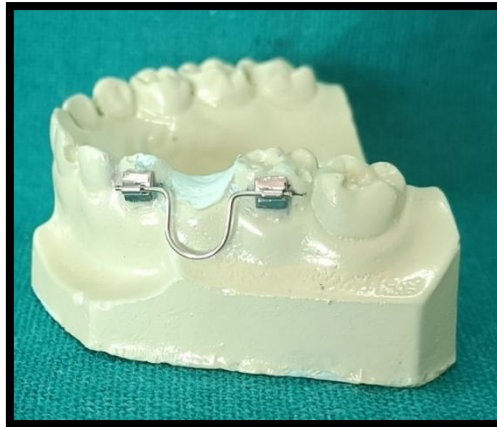

Fig 4. SONAL'S 'U' BONDED SPACE MAINTAINER

CASE REPORT

A 5-year-old male child reported to the Department of Pedodontics and Preventive Dentistry with a chief complaint of pain in the maxillary left posterior region for the past 1 week. Clinical examination revealed grossly decayed primary maxillary left first molar (tooth number 64). Intraoperative periapical radiograph revealed caries involving enamel, dentin and pulp with bone loss in the periradicular area.

Since, the prognosis was poor, extraction was planned followed by fabrication and delivery of the new bonded space maintainer, (SONAL'S U BONDED SPACE MAINTAINER).

Post appliance delivery instructions was given to the patient. Patient was recalled after 1, 3 and 6 months for the evaluation of survival rate, plaque level, gingival health, patient acceptance level of the appliance.

In survival rate we have checked for success or failure of the appliance and caries experience. For plaque level, the presence of plaque in terms of mild, moderate or severe was noted. Gingival health was also noted in terms of severity of the gingival condition- mild, moderate or severe gingivitis.

Table 1. EVALUATION CHECKLIST FOR 1 MONTH, 3 MONTH & 6 MONTH FOLLOW UP

CRITERIA		INSPECTION METHOD	RATING
1.Survival rate			

<ul style="list-style-type: none"> • Success/failure • Breakdown/deformation • Cries experience 		Visual inspection Visual inspection with explorer and mirror	Failed /Successful Absent /Present Absent /Present
2.Plaque level		Visual inspection with blunt periodontal explorer and mirror	Normal Mild plaque Moderate plaque Severe plaque
3.Gingival health		Visual inspection with blunt periodontal explorer and mirror	Normal Mild gingivitis Moderate gingivitis Severe gingivitis
4.Patient acceptance of appliance <ul style="list-style-type: none"> • Level of comfort • Ease of cleaning • Time taken for fabrication of appliance 		Questionnaire	Yes/No

In our patient, the survival rate of new bonded space maintainer was successful at the end of 1 month, 3 month and 6 month. No breakdown or deformation of the space maintainer was seen at the end of 6 months. Similarly no caries was found around the Begg's bracket placed at the abutment tooth.

Plaque level at the follow up of 1month showed mild plaque accumulation around the Begg's bracket placed on the abutment tooth. The oral hygiene instructions was demonstrated again to the patient which led to decrease in plaque level at the subsequent follow up.

Gingival health was seen to be normal at all the subsequent follow ups. Patient's level of acceptance for the appliance was good as it was delivered in a single visit, there was no need for impression and very less time was taken for the delivery of the appliance.

The appliance was very easy to clean for the patient as it was present on the buccal surface of the tooth and no occlusal hindrance was present. Another advantage of this new space maintainer is that the U loop can easily be removed at subsequent follow up for routine cleaning of the area and fluoride application.

Thus, this new space maintainer is found to be very easy to place, comfortable, cost and time effective appliance that can be a viable alternative to the conventional band and loop space maintainer.

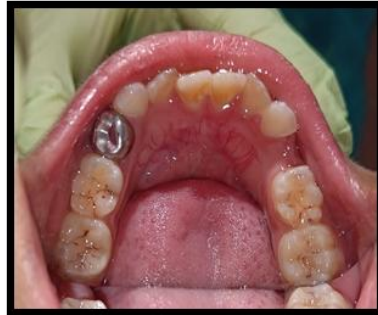

Fig 5. PRE-OPERATIVE

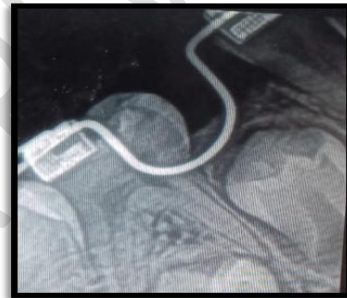
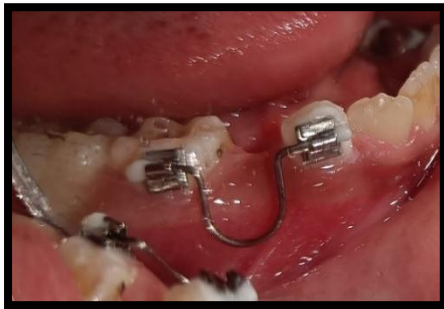
Fig 6. POST-OPERATIVE

DISCUSSION

One of the primary tooth's key functions is to occupy the physiological space and control the emergence of permanent teeth.^[10] The collapse of vertical and horizontal occlusal relationships in primary and permanent dentitions is caused by the premature loss of primary molars. For this reason, it is important that the space created by premature loss of primary teeth need to be maintained until the eruption of permanent successors.^[11] Hence the use of space maintainers counteract the effect of early tooth loss and reduce the severity of negative outcomes, such as crowding, ectopic eruption, tooth impaction, and poor molar relationship.^[12] Out of various space maintainer used, band and loop is the most commonly given appliance but it possess various disadvantages. Numerous authors have undertaken investigations to identify the factors that lead to band and loop failure, and they have discovered that cemental loss, band breaking, and soldering failure are the primary causes.^[13] In order to address these issues, bonded space maintainers were developed that needed to be directly bonded to the tooth, doing away with the requirement for banding and impressions.

Various studies have been conducted to compare the band and loop with bonded space maintainer.

Simsek (2004)^[14], Vikas S (2014)^[15], Qudeimat (2015)^[16], Kirzioğlu Z (2017)^[17], Tyagi M (2021)^[18], in their separate studies have compared the survival rate of bonded space maintainers with conventional band and loop space maintainer and have found that survival rate of bonded space maintainer was comparable to the conventional band and loop space maintainer.

Subramaniam P (2008)^[13], Nidhi C (2012)^[19], Rani R (2020)^[20] conducted various studies where they compared the clinical efficacy of two fixed space maintainers - conventional band and loop and fiber-reinforced composite resin (FRCR) space maintainers and came to the conclusion that FRCR (Ribbond) space maintainers can be considered as an alternative to the conventional band and loop space maintainers.

Garg A (2014)^[21], Kamal Y M (2017)^[22], Sudhir M (2018)^[23], Agarwal T (2020)^[24], EL-Awady (2021)^[25] in their studies compared the patient satisfaction level in bonded space maintainer and conventional band and loop space maintainer and concluded that the bonded space maintainer was better accepted by the patients.

The design of Sonal's U bonded space maintainer put forwards several advantages over the conventional band and loop SM. The complete procedure from fabrication till delivery of the appliance finishes in the single sitting, it saves a lot of time both for the patient, their parents as well as the dentist. The hassle of taking impression is reduced. Since no banding is done, there is no need for transferring of the band and thus it is a viable option for uncooperative and special need children.

The present invention SONAL'S U BONDED SPACE MAINTAINER discloses a process of fabricating a new bonded space maintainer and delivering it in a single sitting.

Some of the key features of this appliance are:

- Easy to fabricate
- Less technique sensitive
- cost effective
- Oral hygiene can be maintained
- Single appointment procedure
- Saves time for both patient and dentist
- Fixed space maintainer
- Better patient compliance thus can be used in special need children
- No need of taking impression
- No banding required
- The U loop can easily be rotated upwards for routine cleaning of the area
- The loop can be removed if required, without disturbing the Begg's bracket.

CLINICAL SIGNIFICANCE

New bonded space maintainer provides an added advantage of better acceptability by special need children, uncooperative children and patients with high gag reflex as it is easy to fabricate, less technique sensitive, single appointment procedure, saves time for both patient and dentist as there is no need of taking impression and band formation.

CONCLUSION

The present invention SONAL'S U BONDED SPACE MAINTAINER is an easy to make appliance which can be used as an alternative to conventional band and loop space maintainer.

Key Messages: New bonded space maintainer provides an added advantage of better acceptability by special need children, uncooperative children and patients with high gag reflex as it is easy to fabricate, less technique sensitive, single appointment procedure, saves time for both patient and dentist as there is no need of taking impression and band formation.

REFERENCES

1. Barbería E, Lucavechi T, Cárdenas D, Maroto M. Free-end space maintainers: Design, utilization and advantages. *J Clin Pediatr Dent* 2006;31:5-8.
2. Baroni C, Franchini A, Rimondini L. Survival of different types of space maintainers. *Pediatr Dent* 1994;16:360-361.
3. Yilmaz Y, Kocogullari ME, Belduz N. Fixed space main-tainers combined with open-face stainless steel crowns. *J Contemp Dent Pract* 2006;7:95-103.
4. Simsek S, Yilmaz Y, Gurbuz T. Clinical evaluation of simple fixed space maintainers bonded with flowable com-posite resin. *J Dent Child* 2004;71:163-168
5. Kirzioglu Z, Ozay MS. Success of reinforced fiber material space maintainers. *J Dent Child* 2004;71(2):158-162.
6. Owen DG. The incidence and nature of space closure following the premature extraction of deciduous teeth: A literature review. *Am J Orthod.* 1971;59:37-49.
7. Kirzioglu Z, Ozay MS. Success of reinforced fiber material space maintainers. *J Dent Child* 2004;71:158-62.
8. Deshpande SS, Bendgude VD, Kokkali VV. Survival of Bonded Space Maintainers: A Systematic Review *Int J Clin Pediatr Dent.* 2018;11(5):440-445.
9. Tulunoglu O, Ulusu T, Genç Y. An evaluation of survival of space maintainers: A six-year follow-up study. *J Contemp Dent Pract* 2005;6:74-84.

10. Nayak UA, Lous J, Sajeev R, Peter J. Band and loop space maintainer-made easy. *J Indian Soc Pedod Prev Dent* 2004 Sep;22(3):134-136.
11. Horax S. Fixed space maintainer with molar band in premature loss of primary first molar teeth (case report). *J Med Nurs* 2006;27(3):174-176.
12. Law CS. Management of premature primary tooth loss in child patient. *J Calif Dent Assoc* 2013 Aug;41(8):612-618.
13. Subramaniam P, Babu G, Sunny R. Glass fiber-reinforced composite resin as a space maintainer: A clinical study. *J Indian Soc Pedod Prev Dent* 2008;26 Suppl 3:S98-103.
14. Simsek S, Yilmaz Y, Gurbuz T. Clinical evaluation of simple fixed space maintainers bonded with flow composite resin. *J Dent Child (Chic)*. 2004 May-Aug;71(2):163-8. PMID: 15587102.
15. Setia V, Kumar Pandit I, Srivastava N, Gugnani N, Gupta M. Banded vs Bonded Space Maintainers: Finding Better Way Out. *Int J Clin Pediatr Dent*. 2014 May;7(2):97-104. doi: 10.5005/jp-journals-10005-1245. Epub 2014 Aug 29. PMID: 25356008; PMCID: PMC4212165.
16. Qudeimat MA, Sasa IS. Clinical success and longevity of band and loop compared to crown and loop space maintainers. *Eur Arch Paediatr Dent*. 2015 Oct;16(5):391-6. doi: 10.1007/s40368-015-0183-y. Epub 2015 Mar 19. PMID: 25788173.
17. Kirzioğlu Z, Çiftçi ZZ, Yetiş CÇ. Clinical Success of Fiber-reinforced Composite Resin as a Space Maintainer. *J Contemp Dent Pract*. 2017 Mar 1;18(3):188-193. PMID: 28258262.
18. Tyagi M, Rana V, Srivastava N, Kaushik N, Moirangthem E, Gaur V. Comparison of the Conventional Band and Loop Space Maintainers with Modified Space Maintainers: A Split-mouth Randomized Clinical Trial. *Int J Clin Pediatr Dent*. 2021;14(Suppl 1):S63-S68. doi: 10.5005/jp-journals-10005-2046. PMID: 35082470; PMCID: PMC8754275.
19. Nidhi C, Jain RL, Neeraj M, Harsimrat K, Samriti B, Anuj C. Evaluation of the clinical efficacy of glass fiber reinforced composite resin as a space maintainer and its comparison with the conventional band and loop space maintainer. An in vivo study. *Minerva Stomatol*. 2012 Jan-Feb;61(1-2):21-30. PMID: 22274307.
20. Rani R, Chachra S, Dhindsa A, Sharma M. Clinical success of fixed space maintainers: Conventional band and loop versus fiber-reinforced composite loop space maintainer. *N Niger J Clin Res* 2020;9:1-6.
21. Garg A, Samadi F, Jaiswal JN, Saha S. 'Metal to resin': a comparative evaluation of conventional band and loop space maintainer with the fiber reinforced composite resin

- space maintainer in children. *J Indian Soc Pedod Prev Dent.* 2014 Apr-Jun;32(2):111-6. doi: 10.4103/0970-4388.130783. PMID: 24739908.
22. Kamal YM, Mohammed KN. Evaluation of posterior fixed functional space maintainers made of fiber reinforced composite. *Oral Health Dent Manag.* 2017;16(2):1-5.
23. Mittal S, Sharma A, Sharma AK, Gupta KK, Gaur A, Pathania V. Banded versus single-sided bonded space maintainers: A comparative study. *Indian J Dent Sci* 2018;10:29-36.
24. Agarwal T, Agarwal N. A Modified Removable Space Maintainer for Compromised Dentition of Children: A Case Series. *Int J Clin Pediatr Dent.* 2020 Nov-Dec;13(6):722-724. doi: 10.5005/jp-journals-10005-1843. PMID: 33976501; PMCID: PMC8060940.
25. EL-Awady, A. A., & Badreldin, H. M. (2021). Children's satisfaction and survival rate of fiber-reinforced space maintainer versus band and loop space maintainer in children with premature loss of maxillary primary first molar: A randomized clinical trial. *International Journal of Health Sciences*, 5(2), 212–222. <https://doi.org/10.53730/ijhs.v5n2.13567>