

Case report

Use of Botox prior to abdominal wall reconstruction - A local experience in a tertiary hospital in Singapore

Comment [MU1]: Kindly Change the Heading Suggested.....

Use of Inj. Botox to the abdominal wall in Large Incisional Hernia Repair – A Local Experience in a Tertiary Hospital in Singapore.

ABSTRACT

Comment [MU2]: The abstract should be short. It should not include sub-headings...Kindly rearrange them...

Introduction: Large incisional hernias are challenging to manage even with techniques like component separation. Although chemical component separation with botulinum toxin A (BTA) prior to surgical repair has gained popularity over the years, it still remains poorly described in Southeast Asian literature. We share our local experience using BTA as an adjunct prior to CS in the repair of a large incisional hernia.

Comment [MU3]: Capital 'C'

Comment [MU4]: Try to write the word & then place within brackets...

Comment [MU5]: Grammar Check...

CASE REPORT: A 72-year-old male developed an 8 x 15 cm incisional hernia 5 months after an emergency right hemicolectomy for severe diverticular bleeding. 3 weeks before surgical repair of his hernia, 300 IU of BTA was injected over 3 sites of the lateral abdominal wall (LAW) muscles bilaterally. The patient subsequently underwent elective surgery and was discharged well on postoperative day 5. A CT scan was done at 3 months showing no recurrence and sustained lengthening of his LAW muscles.

DISCUSSION: Low dose BTA increases LAW muscle length, facilitates fascial closure without tension as well as increasing abdominal cavity volume hence promoting better physiological postoperative adaptation. Despite being a useful adjunct in the management of large incisional hernias, there is significant variation in the dosage, concentration and techniques in which BTA is administered, as well as the optimal duration for administration prior to surgery. Further studies would have to be performed to obtain a consensus as to the best practice for the use of BTA.

Keywords: Botulinum toxin A, Chemical Component Separation, Large Incisional hernia

Comment [MU6]: Include - Lateral abdominal wall..

INTRODUCTION

Large incisional hernias are debilitating complications that are difficult to manage even with techniques such as Ramirez' components separation (CS) and Progressive Preoperative Pneumoperitoneum (PPP) which have been described in the literature for decades [1,2,3]. Incisional hernias occur at previous laparotomy incision sites as they are inherent areas of weakness that are susceptible to separation in the face of intra-abdominal pressures. The European Hernia Society recommends consideration of component separation with or without posterior release for moderate-large complex hernias[4].

CS techniques were first described by Ramirez et al to elongate LAW musculature and reduce tension for primary fascia closure. Apart from being technically challenging, CS is associated with complications such as surgical site infection, seroma, wound dehiscence and enterocutaneous fistula at the site of hernia repair[5].

Subsequently, in the 1990s, Ibarra-Hurtado et al[6] introduced chemical compartment separation, using BTA to paralyze and elongate the LAW musculature before surgical repair. Ibarra-Hurtado et al. demonstrated that BTA use allowed a mean of 5.25 cm reduction in fascial defect width at 4 weeks while Zielinski et al. from Mayo Clinic further reported BTA use to increase the closure rate of midline defect by 6% within 24h[7]. BTA use has also been safely described for fascial defects of 6-18cm by several other authors[8-12], showing its benefit in complex abdominal wall reconstruction.

To our knowledge, despite the benefits of BTA, there is limited literature on its use in the management of large complex hernias in Southeast Asia. One of the reasons for this could be due to the significant variation in the dosage, concentration and anatomical landmarks in which BTA is administered, as well as the optimal duration for administration prior to surgery. As such, we would like to share our experience with BTA chemical component separation prior to surgery for a large incisional hernia.

Comment [MU7]: Kindly highlight the incidence [in %] of BTA usage in Large Incisional hernia repair across the globe with appropriate reference...

Comment [MU8]: Quote any reference to this sentence...

CASE SUMMARY

The patient is a 72- year- old male who was admitted for massive diverticular bleeding from the caecum, resulting in haemorrhagic shock requiring massive blood transfusions. He underwent angioembolization but had recurrent bleeding post embolization and became hemodynamically unstable again. He underwent emergency laparotomy, right hemicolectomy and temporary closure. He subsequently underwent re-look laparotomy, ileocolic anastomosis and abdominal closure a day later. Post operatively, his stay was complicated by a sealed anastomotic leak which was managed by percutaneous drainage and antibiotics. He also developed wound infection which was managed conservatively with wound packing. His anastomotic leak sealed eventually and he was discharged.

Five months after discharge, he was reviewed in clinic and found to have developed a large 8 x 15 cm incisional hernia above the level of the umbilicus. The large incisional hernia was limiting his daily activities and he was keen for surgical repair.

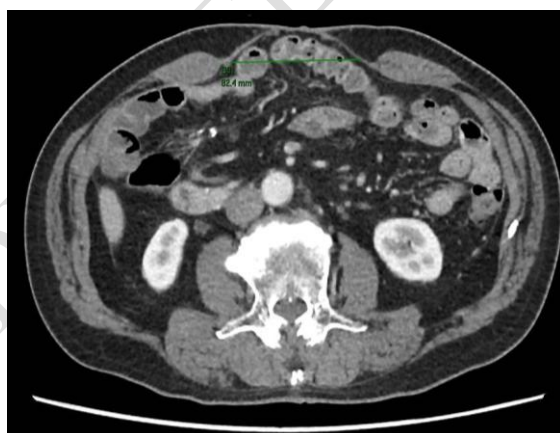

Figure 1: CT showing 8 cm incisional hernia defect

TECHNIQUE

Our interventionalist elected to choose the technique described by Zendejas Et al, 3 weeks prior to definitive surgery, a total of 300 IU of BTA was injected over 3 spots along the anterior axillary

Comment [MU9]: Specify how many days after the surgery, the patient was discharge...

Comment [MU10]: Any pre-op pictures of the patient?

Comment [MU11]: Kindly add some few findings related to GE, LE ... Also add the salient other investigations done on this patient...

Comment [MU12]: Check Grammar, Comma Check...

Comment [MU13]: Try to show an arrow on the defect site...

Comment [MU14]: Kindly add the reference number to cited article...

line bilaterally, infiltrating the aponeurosis of the external oblique, internal oblique and transversus abdominus. The patient did not develop any complications after the procedure.

Comment [MU15]: Try to include - 'in the abdominal wall'

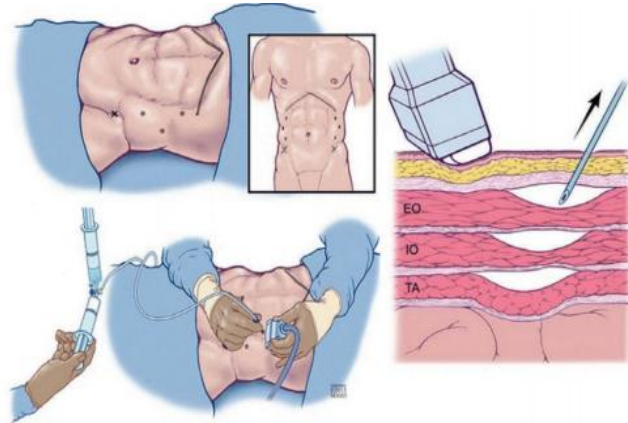


Figure 2: Botox injection technique described by Zendejas et al[13]

Three weeks later, the patient underwent elective laparotomy, adhesiolysis and anterior component separation. The abdomen was entered via the midline and adhesiolysis was performed. The anterior rectus sheath was divided lateral to the linea semilunaris from above the costal margin to the anterior superior iliac spine. Interrupted closure of the anterior sheath was performed with PDS II/II. The overlying hernia sac and excess skin were trimmed before subcutaneous closure with Vicryl 2/0 and staples to skin. Drains were inserted to the subcutaneous planes bilaterally to avoid seroma formation.

Comment [MU16]: Please include - On-table Surgery pics...to add strength to your article...

Post operatively, the patient recovered uneventfully. He did not develop any ileus, abdominal compartment syndrome or respiratory complications. By post operative day (POD) 2, he could ambulate 50 metres with minimal pain. He was placed on an abdominal binder while ambulating to avoid wound complications. He was progressed to diet on POD 3. Immediate post operative pain control was initially managed with bilateral paravertebral On-Q pumps until POD 4, with only oral Oxycodone and Paracetamol thereafter. The patient was sent home with subcutaneous drains on POD 5 to avoid seroma formation.

Comment [MU17]: Add Post-op pics...

On review in clinic on POD 12, both lateral subcutaneous drain outputs were minimal and both were removed. The midline wound had healed well and staples were also removed. A repeat CT abdomen/pelvis done at 3 months showed no early recurrence. The patient was followed up for 1 year with no recurrence on clinical examination.

Comment [MU18]: Space Check...

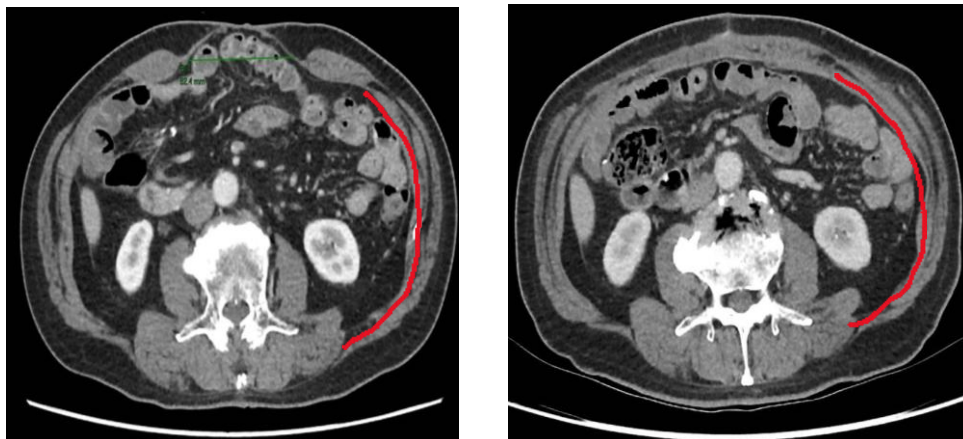


Figure 3: Pre-operative and post operative CT comparisons showing persistent lengthening of LAW musculature and successful primary fascial closure after CS.

Comment [MU19]: Kindly Highlight - Drawn red-line...Also show with arrows the closure site...

DISCUSSION

The aim of pretreatment with BTA prior to surgical repair of large incisional hernias is to promote improved rates of primary fascial closure by decreasing hernia defect size and to allow for healing under tension-free circumstances [14]. Botox can also possibly avoid the need for CS, reduce recurrence, and avoid abdominal compartment syndrome post operatively.

BTA is a protein with neurotoxin activity that is produced by *Clostridium botulinum*. It works at the neuromuscular junction by inhibiting the release of acetylcholine, thereby inducing flaccid paralysis. This muscle flaccidity results in LAW musculature lengthening by 3–4 cm on each side; and 6–8 cm in total. This suggests that a defect of 6–8 cm size would likely get the best benefit for primary closure without component separation techniques[15]. The peak onset of action is approximately 2

Comment [MU20]: Kindly rearrange the sentences so as to highlight the BTA first, then about large incisional hernia...later comparing with other articles ...

weeks and can last up to 6 months[16]. Commercial brands available locally in Singapore are BOTOX[®] and Dysport[®].

Despite multiple papers being published about the use of BTA for abdominal wall reconstruction there is significant variation in the dosage used, technique of injection and duration before surgery. This is demonstrated in the paper published by Timmer et al[18]. Dosage wise, generally, either 500 units of Dysport[®] or 200-300 units of BOTOX[®] is most commonly used. In terms of technique, Ibarra-Hurtado, Zielinski, Zandejas and Elstner[6,7,13,17], have described four different techniques but with one end result. They concluded that the administration should be at 3-5 locations bilaterally between the midclavicular to midaxillary line and should involve all 3 layers of LAW. The pattern could be a straight line or in a triangle from costal margin to superior iliac fossa. As for the optimal pretreatment duration before surgery, most papers in general advocate a duration of 2-4 weeks post injection as the peak onset of action for BTA is approximately 2 weeks.

Reported complications of BTA injections include weak cough or sneeze, backache and dyspnoea [19,20]. Some authors have suggested decreasing the dose of BTA used to minimize said complications while others have suggested sparing one of the layers of the LAW complex. With the currently available data, it is not possible to assess an optimal dosage and technique. However, despite the reported problems, it is fair to say that BOTOX pretreatment seems safe as there has not been any major complications reported so far.

CONCLUSION

The injection of BTA in the lateral abdominal wall muscles is safe without major procedural complications. The technical aspects and treatment regimens for BTA differ substantially. Randomized trials and prospective studies are therefore needed for comparison of outcomes in future research.

References

Comment [MU21]: Kindly mention the BTX used in your case...

Comment [MU22]: Grammar Check...

Comment [MU23]: Compare to your case..

Comment [MU24]: Compare with your case - With no complications..

Comment [MU25]: Try to specify the usage of BTA - in Large incisional hernia...

Comment [MU26]: Kindly make sure it is aligned to the Journal admitted reference style...Also Grammar Check...

1. Ramirez OM, Ruas E, Dellon AL. "Components separation" method for closure of abdominal-wall defects: an anatomic and clinical study. *PlastReconstr Surg*. 1990 86:519–26. doi: 10.1097/00006534-199009000-00023
2. Moreno IG. Chronic eventrations and large hernias; preoperative treatment by progressive pneumoperitoneum; original procedure. *Surgery*. (1947) 22:945–53.
3. Gillion JF, Sanders D, Miserez M, et al. The economic burden of incisional ventral hernia repair: a multicentric cost analysis. *Hernia* 2016;20:819-830
4. Sanders DL, Pawlak MM, de Beaux AC. European Hernia Society incisional hernia guidelines. *British Journal of Surgery*. 2023 Mar 1;110(3):343-.
5. Reshma Brahmabhatt, Stacey A. Carter, Stephanie C. Hicks, David H. Berger, and Mike K. Liang. Identifying Risk Factors for Surgical Site Complications after Laparoscopic Ventral Hernia Repair: Evaluation of the Ventral Hernia Working Group Grading System. *Surgical Infections* 2014 15:3, 187-193
6. Ibarra-Hurtado TR, Nuño-Guzmán CM, Echeagaray-Herrera JE, Robles- Vélez E, de JesúsGonzález-Jaime J. Use of botulinum toxin type a before abdominal wall hernia reconstruction. *World J Surg*. 2009. 33:2553–6. doi: 10.1007/s00268-009-0203-3
7. Zielinski MD, Goussous N, Schiller HJ, Jenkins D. Chemical components separation with botulinum toxin A: a novel technique to improve primary fascial closure rates of the open abdomen. *Hernia*. 2013. 17:101–7. doi: 10.1007/s10029-012-0995-1
8. Whitehead-Clarke Thomas, Windsor Alastair. The Use of Botulinum Toxin in Complex Hernia Surgery: Achieving a Sense of Closure. *Frontiers in Surgery* 2021. Doi:10.3389/fsurg.2021.753889
9. Rodriguez-Acevedo O, Elstner KE, Jacombs ASW, Read JW, Martins RT, Arduini F, et al. Preoperative Botulinum toxin A enabling defect closure and laparoscopic repair of complex ventral hernia. *SurgEndosc*. 2018. 32:831–9. doi: 10.1007/s00464-017-5750-3
10. Jacombs A, Elstner K, Rodriguez-Acevedo O, Read JW, Ho-Shon K, Wehrhahn M, et al. Seven years of preoperative BTA abdominal wall preparation and the Macquarie system for surgical management of complex ventral hernia. *Hernia*2021. doi: 10.1007/s10029-021-02428-2.
11. Yurtkap Y, van Rooijen MMJ, Roels S, Bosmans JML, Uyttebroek O, Lange JF, et al. Implementing preoperative Botulinum toxin A and progressive pneumoperitoneum through the use of an algorithm in giant ventral hernia repair. *Hernia*. 2021. 25:389–98. doi: 10.1007/s10029-020-02226-2
12. Bueno-Lledó J, Carreño-Saenz O, Torregrosa-Gallud A, Pous-Serrano S. Preoperative botulinum toxin and progressive pneumoperitoneum in loss of domain hernias-our first 100 cases. *Front Surg*. 2020. 7:3. doi: 10.3389/fsurg.2020.00003
13. Zendejas B, Khasawneh MA, Srivantstyan B, Jenkins DH, Schiller HJ, Zielinski MD. Outcomes of chemical component paralysis using botulinum toxin for incisional hernia repairs. *World J Surg*. 2013. 37:2830–7. doi: 10.1007/s00268-013-2211-6
14. Soltanizadeh S, Helgstrand F, Jorgensen LN. Botulinum toxin a as an adjunct to abdominal wall reconstruction for incisional hernia. *PlastReconstrSurg Glob Open*. 2017;5(6):e1358. doi: 10.1097/GOX.0000000000001358.
15. Lien SC, Hu Y, Wollstein A, Franz MG, Patel SP, Kuzon WM, Urbanchek MG. Contraction of abdominal wall muscles influences size and occurrence of incisional hernia. *Surgery*. 2015;158:278–88. <https://doi.org/10.1016/j.surg.2015.01.023>.
16. Dressler D. Clinical applications of botulinum toxin. *Curr. Opin. Microbiol*. 2012;15:325–336. doi: 10.1016/j.mib.2012.05.012.
17. Elstner KE, Read JW, Rodriguez-Acevedo O, Ho-Shon K, Magnussen J, Ibrahim N. Preoperative progressive pneumoperitoneum complementing chemical component relaxation in complex ventral hernia repair. *SurgEndosc*. 2017;31:1914–22. <https://doi.org/10.1007/s00464-016-5194-1>.
18. A.S Timmer, J.J.M Claessen, J.J. Atema, MVH Rutten, R Hompes, MA Boermeester. A systematic review and meta-analysis of technical aspects and clinical outcomes of botulinum toxin prior to abdominal wall reconstruction. *Hernia*. 2021; 25(6): 1413–1425. 2021 Sep 21. doi: 10.1007/s10029-021-02499-1
19. Farooque F, Jacombs AS, Roussos E, Read JW, Dardano AN, et al. Preoperative abdominal muscle elongation with botulinum toxin A for complex incisional ventral hernia repair. *ANZ J Surg*. 2016;86:79–83.
20. Rodriguez-Acevedo O, Elstner KE, Jacombs ASW, Read JW, Martins RT, et al. Preoperative botulinum toxin A enabling defect closure and laparoscopic repair of complex ventral hernia. *SurgEndosc*. 2018;32:831–9.