

# Prosthetic Management in patient with bruxism: A Case Report

## Abstract :

The aim of this study is to present a global management of this parafunction in order to satisfy the requirements of the patient, to minimize the risk of prosthetic failure and to improve the quality of life of these patients. The success of a prosthetic rehabilitation integrated within the manducatory system depends on several parameters that must be taken into consideration as early as the clinical examination. A 70-year-old patient, in good general health, was consulting the removable partial denture department at the dental clinic of Monastir (Tunisia) for an aesthetic and functional reason. The patient reports a diurnal and especially nocturnal grinding of the teeth which leads to a suspicion of bruxism. The patient seems to be stressed and nervous due to his work which is driving instructor. The clinician will also have to take into consideration the maintenance sessions, the perfect occlusal adjustment in post-prosthetic and the patient's compliance after wearing the splint. He must also assure a very regular follow-up in order to be able to detect and analyze any alarming sign such as loosening or repeated fracture of the abutment screws and fracture of the cosmetic material to reach the objectives of the treatments and to reduce the later complications. It appears that any decision will be based on clinical experience and on the correct diagnosis of the level and type of bruxism which needs a certain level of knowledge by the dentist.

**Keywords:** Clinical case report, Bruxism, Combined Prosthesis, Implant.

## Introduction:

The success of a prosthetic rehabilitation integrated within the manducatory system depends on several parameters that must be taken into consideration as early as the clinical examination. In fact, the dentist is confronted with many challenges in his daily practice, among which we note bruxism (1).

This inconstant phenomenon of the manducatory system, which is mainly nocturnal, is considered by the American Academy of sleep disorders as a sleep problem or a harmful movement related to sleep since 2005 (2).

The current reviews admit that this parafunction is a multifactorial disorder with no specific cause and incriminate stress and mismanaged anxieties as predisposing factors. They define it as an oromandibular behavioral problem that is difficult to diagnose because there is no pathognomonic symptoms (3). This disorder without curative treatment until now has irreversible consequences in particular the loss of occlusal references and mandibular posture, and destructive prosthetic incidences. Thus, bruxism complicates the prosthetic management and makes the prognostic critical.

The aim of this article is to present a global management of this parafunction in order to satisfy the requirements of the patient, to minimize the risk of prosthetic failure and to improve the quality of life of these patients.

### **Clinical case:**

A 70-year-old patient, in good general health, was consulting the removable partial denture department at the dental clinic of Monastir (Tunisia) for an aesthetic and functional reason. The patient reports a diurnal and especially nocturnal grinding of the teeth which leads to a suspicion of bruxism. The patient seems to be stressed and nervous due to his work which is driving instructor.

Endobuccal examination reveals:

-In the maxilla: The teeth present are: 14, 13, 12, 11, 21, 22, 23, and 24. Wear surfaces reaching half of the teeth with myololysis and fissures. All teeth have a good radiologic ratio with no mobility and are endodontically treated with sufficient endodontic treatment.

-On the mandible: The missing teeth are 36, 37, 46 and 47. Wear surfaces are present on all teeth with myololysis and fissures. (Fig.1)

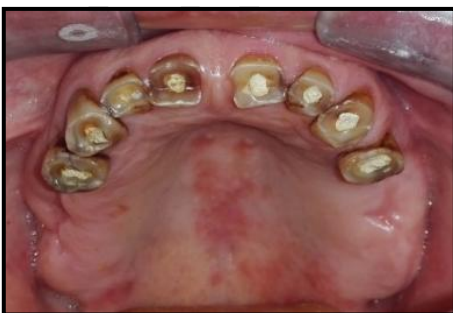

Fig1.a: The maxillary arch

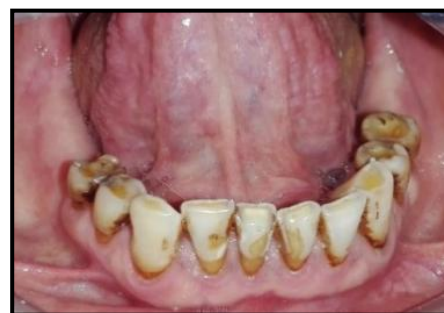

Fig1.b: The mandibular arch

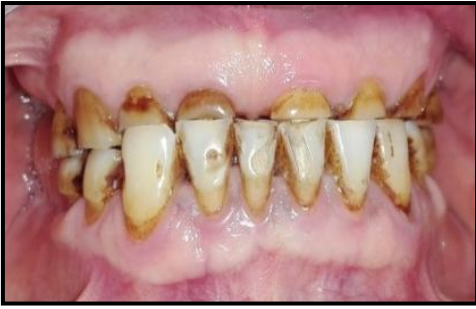

Fig1: intraoral view

Fig 1 c : Arches in occlusion

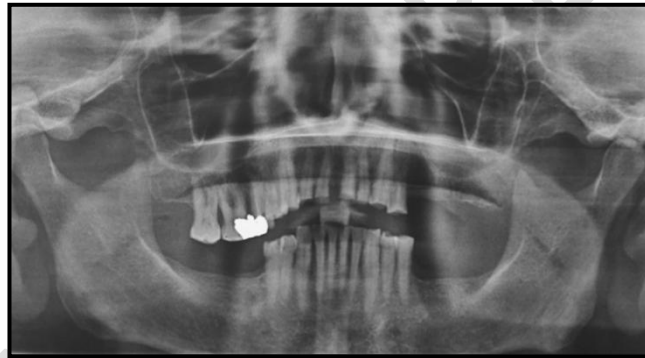


Fig2: Panoramic X-ray before extraction of compromised teeth

Panoramic X-ray examination reveals a bone resorption in the 15, 16 and 17 which have already been extracted. (Fig 2)

In occlusal examination, the vertical dimension was slightly reduced, the occlusal plane was affected by tooth abrasion and the prosthetic space was insufficient.

The prosthetic decision was:

- In the maxilla: combined prosthesis: solidarized crowns from 14 to 24 with two extra-coronal articulated attachments: Ceka Preci-line®.

In the mandible: Simple composite prosthesis: ceramo-metal crowns on 34, 35 and 44, 45

This decision was established and presented to the patient to obtain his consent.

To solve the problem of the reduction of the available vertical prosthetic space in relation to the fixed prosthesis, the prosthetic project was carried out with an increase of the vertical dimension of 3mm at the level of the incisal bar of the articulator. This was possible because the patient is normodivergent and the temporomandibular joints are healthy. (Fig3)

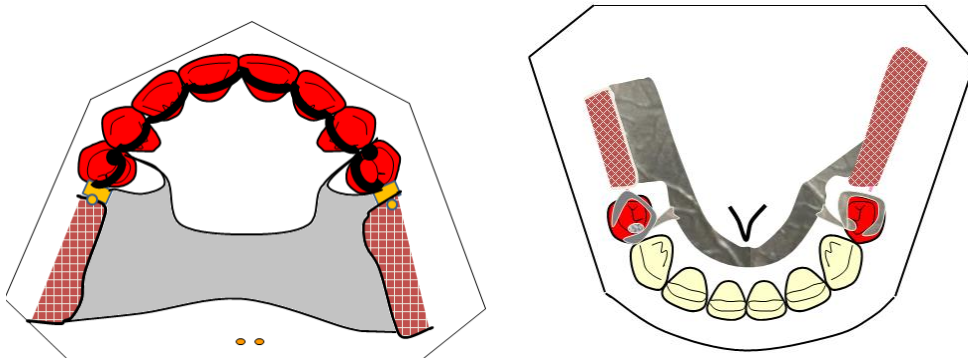


Fig3 : Prosthetic design

The treatment planning was:

**Cognitive-behavioral treatment:**

The objective of this treatment is to decrease the constraints on the various structures dental, articular, muscular, and tendinous as well as to release muscular tensions. The patient must learn to put the mandible at rest.

The sequences of this approach are as follows:

Mandibular resting posture: Lips touching, teeth not touching, tongue resting lightly on the palate (behind the incisors), breathe through the nose.

## Swallowing

- Gently put all the teeth in contact, the tongue pressed to the palate.
- Never put the tongue between the teeth or press it against the teeth during swallowing, don't clench the lips and don't grind the teeth.

Release by returning to the rest posture of the mandible

## Prosthetic steps:

A favorable result was obtained after 8 weeks of behavioral treatment. Then, a crown lengthening on 11 and 21 was done. The upper teeth were reconstructed with fiber posts and rebuilding resin then they were prepared (fig 4).

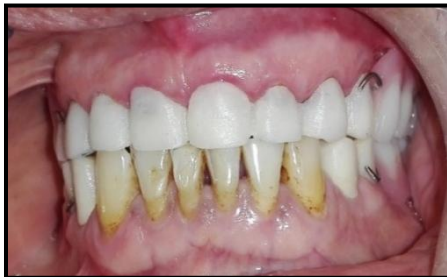

Fig.4.a : Crownlengthening

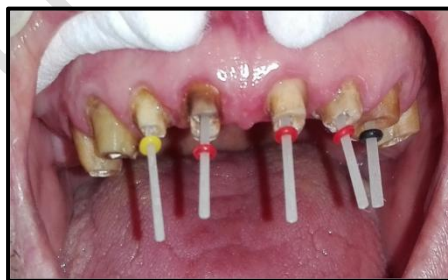

Fig 4.b : Fiber post reconstitution

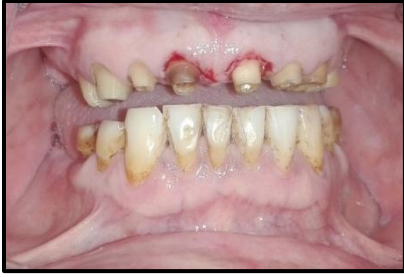

Fig4.c : Temporary prosthesis

Fig 4: Maxillary residual teeth preparation

Provisional acrylic resin crowns were fabricated and a provisional removable partial denture was created to replace missing teeth. This is an important step of treatment to verify vertical dimension and to visualize prosthodontic project by provisional restorations.

Then, the metal frameworks of the fixed prosthesis are designed according to the design of the removable denture and the metal frameworks are tried on in the mouth, followed by the mounting of the ceramic.

A pick-up impression with acrylic custom tray and polyether was made. Polyether seems to be ideal for this situation impression it's known for its precision and rigidity. The mandibular impression was made using silicone of low and heavy viscosity. (Fig 5)

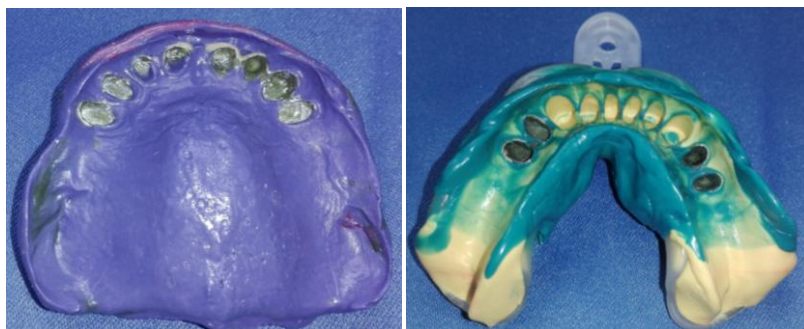


Fig 5-a: Maxillary Pick-up impression      Fig 5-b Mandibular Pick –up impression

Fig 5: Pick –up impressions

A removable partial denture (RPD) framework was cast in a cobalt-chromium alloy and clinically tried to check seating. (Fig 6)

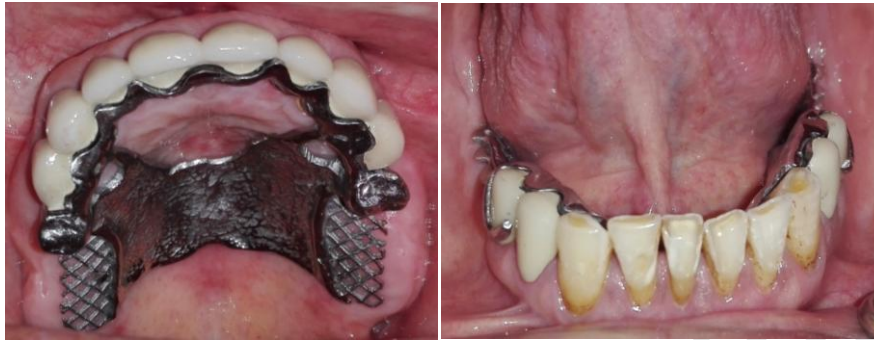

Fig 6-a: Clinical try-in of maxillary RPD framework      Fig 6-b: Clinical try-in of mandibular RPD framework

Fig 6: Clinical try-in of RPD framework

Try in of the metallic frame was done and Maxillomandibular relation was recorded and mounted on semi-adjustable articulator. Teeth arrangement was done as well as wax try. Cast partial dentures were fabricated in heat cure denture base resin. Female components of attachments were attached to cast partial denture by relining method after verifying occlusal contacts.

The patient was satisfied by the combined prosthesis, (Fig 7) he was instructed regarding oral hygiene, how to remove and insert the partial denture and the time to recall to check female components, in order to have a good functionality.

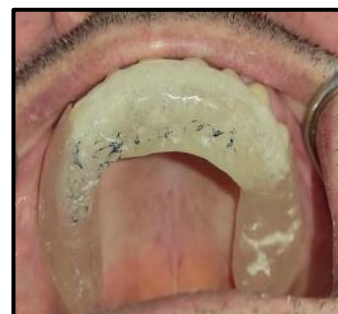
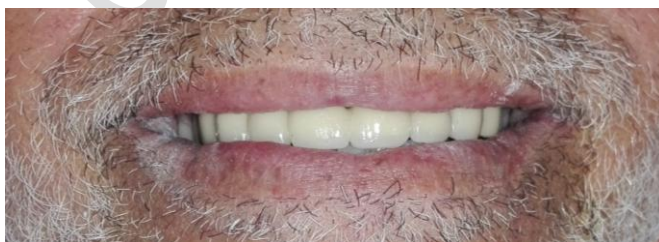
Fig 7: Post-treatment smile and protective splint

A splint was placed at the end of the treatment to protect the prosthetic structures. A regular follow-up was established in order to help the patient in the management of bruxism and to verify the durability of the prosthetic restoration.

## **Discussion:**

Bruxism is a common complaint in dental practice. Yet, few relevant articles studied the relation between bruxism and prosthetic treatment or on the management of this problem. In most of the published articles, the authors focused on the effect of bruxism on the implant-supported prosthesis, the restorative materials used and the structural integrity of the prosthesis, thus the importance of this manuscript in the scientific research and the demonstration of the clinical impact of bruxism and the different therapeutic solutions available to deal with it especially if it's associated to an edentulism (4).

So far, the relationship between bruxism and prosthetic treatment can be summarized in the role that the treatment may play as a risk factor for the development of post-prosthetic complications. On the other side, there is no scientific evidence that accuses prosthetic restorations of being at the origin of this phenomenon or that demonstrates that they can totally eliminate bruxism (1).

Indeed, the rehabilitation approaches are based on expert clinical experience rather than scientific evidence due to the limited research on the restoration of tooth wear in patients with nocturnal bruxism. In this context, conservative and reversible treatments are favored to restore the vertical dimension of the occlusion, which is often necessary to create a needed prosthetic space. In our case, the edentulism guided us to a complex combined prosthesis. The association between fixed and removable partial dentures by means of attachments is an important alternative for oral rehabilitation, particularly when the use of dental implants and fixed denture is limited or not indicated. In the absence of an effective curative treatment to date, complementary strategies to prosthetic treatment, such as behavioral rehabilitation associated with the use of a protective splint, seem to be an interesting option (5) in order to minimize the repercussions of occlusal charges on the dento-osteo-mucosal support surfaces and to increase the longevity of the restorations, which is still uncertain despite all the efforts made (6).

In this case, the implant solution was not an option because the patient refused it not because he was a bruxer. In this regard, the literature shows numerous controversies concerning the use of implants in patients with bruxism: Harder and al (7) showed that implants could be used to rehabilitate bruxers in various prosthetic indications with fixed and removable prostheses without fracture or implant loss, Komiyama and al (8) reported that occlusal overstress caused by teeth grinding may be related to the risk of loss of osseointegration, implant fracture, damage to the materials, and loosening of screws of fixed implant-supported partial dentures.

In the same context, Brägger and al (9) recognized a causal relationship between bruxism and crowns fracture, but they could not show the relationship between bruxism and implant failure. Engel and al (10) suggested that bruxism never affected the marginal bone loss of the dental implant. It is therefore concluded that a formal contraindication for implants-bruxism does not exist and there is still no sufficient scientific evidence of a causal relationship between bruxism and implant failure, or specific case management since most research and clinical trials on the influence of bruxism on biomechanical implant failure.

In the prosthetic rehabilitation, a specific management of the parafunction is essential before planning a dental prosthesis, in particularly an implant treatment. The dentist will have to perform a meticulous occlusal examination, determine the type of bruxism (waking or sleeping, taking medication or predisposing disease), and propose to the patient solutions to protect his teeth and limit his parafunction as much as possible (splint, psychological management, medication).(9)The clinician will also have to take into consideration the maintenance sessions, the perfect occlusal adjustment in post-prosthetic and the patient's compliance after wearing the splint. He must also assure a very regular follow-up in order to be able to detect and analyze any alarming sign such as loosening or repeated fracture of the abutment screws and fracture of the cosmetic material to reach the objectives of the treatments and to reduce the later complications. It appears that any decision will be based on clinical experience and on the correct diagnosis of the level and type of bruxism which needs a certain level of knowledge by the dentist.

## **Conclusion:**

Bruxism is a parafunction that requires special management, especially if a prosthetic rehabilitation is considered. If a clinician decides to adopt this solution, he must keep in mind that the prosthesis does not cure the patient of his parafunction and that restoring a damaged dentition without trying to prevent bruxism cannot lead to a successful result.

On the patient's side, consent should no longer be a passive acceptance, but should become an expression of the patient's active participation and engagement in the treatment.

## **References:**

1. Anders Johansson. Bruxism and prosthetic treatment: a critical review. *J Prosthodont Res.* 2011.
2. Sylwia Bulanda, Danuta Ilczuk-Rypuła, Aleksandra Nitecka-Buchta, Zuzanna Nowak, Stefan Baron, Lidia Postek-Stefańska. Sleep Bruxism in Children: Etiology, Diagnosis, and Treatment—A Literature Review. *Int J Environ Res Public Health.* 2021 Sep.
3. F Lobbezoo, M Naeije. Etiology of bruxism: morphological, pathophysiological and psychological factors. *Ned Tijdschr Tandheelkd.* 2000 Jul;107(7):275-80
4. HEY Jan. A Critical Review on the Relation and Impact of Bruxism and Prosthetic Treatment. *Egyptian Journal of hospitalmedicine.* 2017.
5. D A Paesani. *Bruxism Theory and practice.* Quintessence, London. 2010: 359–382.
6. G.E. Carlsson. Critical review of some dogmas in prosthodontics. *J Prosthodont Res* 53. 2009: 3-10.
7. Harder S, Wolfart S, Egert C, Kern M. Three-year clinical outcome of single implant-retained mandibular overdentures – results of preliminary prospective study. *J Dent.* 2011;39:656–661
8. Komiyama O, Lobbezoo F, De Laat A, et al. Clinical management of implant prostheses in patients with bruxism. *Int J Biomater.* 2012:369063.
9. U Bragger, S Aeschlimann, W Burgin, CH F Hammerle, N P Lang. Biological and technical complications and failures with fixed partial dentures (FPD) on implants and teeth after four to five years of function. *Clinical Oral Implants Research.* 2001; vol.12 (1): 26–34.
10. E Engel, G Gomez-Roman, D Axmann-Krcmar. Effect of occlusal wear on bone loss and periosteal value of dental implants. *International Journal of Prosthodontics.* 2001; vol.14 (5): 444–450.

UNDER PEER REVIEW