

Systematic Review Infections by *Alloscardoviaomnicolens* and Associated Clinical Conditions: A Systematic Review

ABSTRACT

Background and Aim: *Alloscardoviaomnicolens* is a Gram-positive, non-motile, non-sporulating bacillus that is occasionally identified as a member of the human microbiota. Despite its infrequent colonization of humans, it has been detected in various anatomical sites, including the gastrointestinal tract, urinary tract, vaginal mucosa, and oral cavity, and has the potential to cause opportunistic infections. This systematic literature review aims to analyze the pathogenic potential of *A. omnicolens* and the underlying clinical conditions associated with infection.

Methods: A systematic review of scientific manuscripts was conducted using the PubMed, SciELO, and Google Scholar databases. The search terms employed included "*Alloscardoviaomnicolens*," "infection" "culture," and "identification". Manuscripts published in English, Portuguese, Spanish, and French from 2007 to 2023 were considered for review.

Results: Following the bibliographic selection process, a total of five articles discussing *Alloscardoviaomnicolens* infections were included, along with an additional thirty-six articles for analytical support.

Conclusion: Infections caused by *Alloscardoviaomnicolens* are infrequent and are predominantly associated with underlying medical conditions. The detection of this bacterium in cultures of organic specimens from patients, particularly those with neoplastic diseases, warrants clinical attention when patients are in critical health states or exhibit risk factors for opportunistic infections. Given the antibiotic susceptibility profiles of the prevailing strains of *Alloscardoviaomnicolens*, we recommend the use of narrow-spectrum antibiotics for treatment in these cases, with the exception of Metronidazole. This approach can effectively eliminate *Alloscardoviaomnicolens* while minimally impacting the broader human microbiota composition.

Keywords: *Alloscardoviaomnicolens*, Opportunistic infection, Dysbiosis, Clinical significance

1. INTRODUCTION

The identification and characterization of *Alloscardoviaomnicolens* represent a significant milestone in microbiological research. This bacterium belongs to a relatively unknown genus, which had been previously underestimated in terms of its importance as a component of the oral and genitourinary microbiotas in humans. In 2007, Huys et al. [1] identified this bacterium when examining microorganisms presumed to belong to the genus *Bifidobacterium*, which were sampled from organic materials in individuals from different European countries. Further investigations were initiated, and isolates were cultured from various sources, including an aortic valve abscess, blood, lung abscess, oral cavity, tonsils, urethra, and urine. Genetic and phenotypic analyses revealed that these isolated bacteria did not belong to the *Bifidobacterium* genus but rather constituted a novel genus within the Bifidobacteriaceae family. This new genus was named *Alloscardovia*, and

the identified species was designated as *Alloscardoviaomnicolens*. The taxonomic etymology of the species name (omnicolens) is derived from the Latin words "omni" (all) and "colens" (inhabitant), suggesting a wide range of colonization or infection sites [1]. The distinctive genomic marker for this species is the 16S rRNA gene. The genus *Alloscardovia* currently includes, besides *A. omnicolens*, four other species (*Alloscardoviacriceti*, *A. macacae*, *A. venturaj*, and *A. theropithecij*) that colonize or infect non-human mammals [2].

Morphologically, *Alloscardoviaomnicolens* is characterized as a thin, Gram-positive, non-motile, and non-sporulating bacillus. It is considered a microaerophilic or facultative anaerobic bacterium, oxidase-negative and catalase-negative. This microorganism primarily multiplies in culture media under anaerobic conditions on blood agar, with visible colonies forming within 24 to 48 hours at 35°C. The colonies are small (less than 1 mm), and signs of hemolysis may sometimes be observed after 48 hours of cultivation [1,3,4,5]. Studies indicate that although it is rarely found colonizing humans, it is part of the gastrointestinal tract microbiota [6], urinary tract [6,7,8,9], vaginal mucosa [10,11,12,13], and oral cavity [4,14,15,16,17]. The species has been found in dental biofilms associated with dental plaques, suggesting a potential role in their formation [18,19].

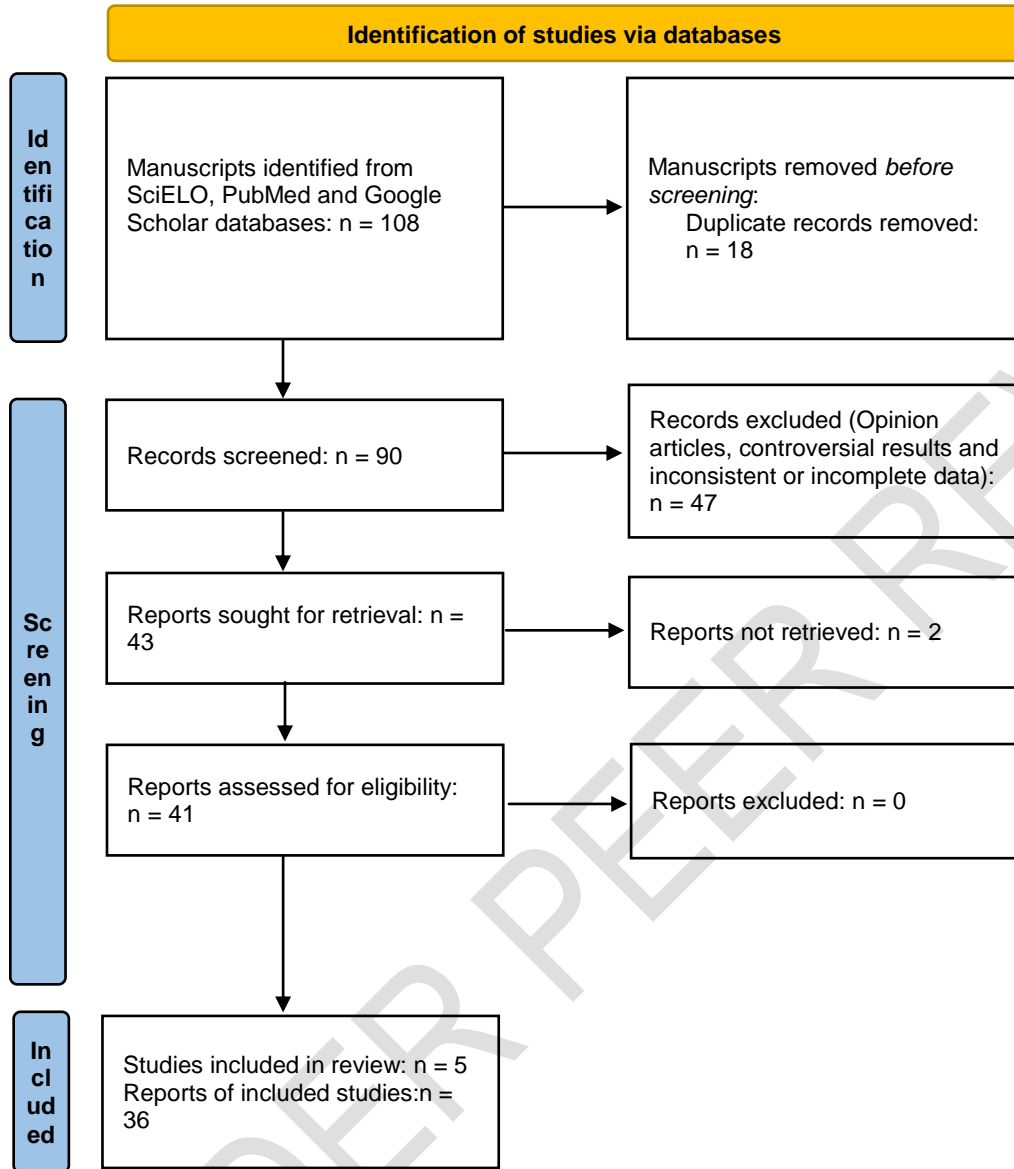
The clinical significance of *Alloscardoviaomnicolens* microbiological findings is controversial, given the possibility of it being a part of normal microbiotas and its low infectivity potential [4,15,20]. The aim of this research is to analyze, through a systematic literature review, the pathogenic potential of this bacterium and the underlying conditions involved in infection cases.

2. METHODS

A systematic review was conducted according to the methodological guidelines proposed by de Moher et al. [21], updated by Page et al. [22], using the PRISMA model. The objective of the review was to examine the infection potential of *Alloscardoviaomnicolens* and the significance of its positivity in the culture of organic samples from patients. The sources for the review included the databases PubMed, SciELO, and Google Scholar, and the search was performed using the following descriptors: "*Alloscardoviaomnicolens*", "infection", "culture" and "identification". The manuscripts reviewed were published in English, Portuguese, Spanish, and French, timeframed from 2007 till 2023.

Studies that evaluated the colonization by *Alloscardoviaomnicolens* and case reports of infections by this bacteria were selected for review. After reading the full text of each article and case report, relevant information was selected and evaluated. The most important aspects were recorded and summarized for analysis. Review articles, opinion articles, and articles with incomplete data or controversial diagnostic interpretations were excluded. A flowchart was provided to illustrate the rationale for selecting the reference material for this review (Figure 1).

Fig. 1. Flowchart of the screening process of publications according to the PRISMA model.



*Source: the authors

3. RESULTS AND DISCUSSION

Following the bibliographic selection process, five articles on *Alloscardoviaomnicolens* infections and thirty-six articles for analytical support were evaluated. The synthesis of the most pertinent aspects from the case reports of *Alloscardoviaomnicolens* infections is presented in Table 1.

Table 1. Key Aspects from Case Reports of *Alloscardoviaomnicolens* Infections.

Reference	Type of sample examined in culture	Total cultures positive for <i>Alloscardoviaomnicolens</i>	Clinical presentation of cases considered infectious	Clinical condition associated with cases considered infectious	Antibiotic treatment
-----------	------------------------------------	--	--	--	----------------------

Mahlen e Clarridge [15]	Urine	5 (4 patients)	Urinary tract infection (2)	Urinary bladder cancer (1) T-cell lymphoma (1)	Not informed
Brown et al. [20]	Urine	15	Probable bacteremia (1) Urinary tract infection (1)	Diamond-Blackfan anemia (1) Atrophic vaginitis (1)	Ciprofloxacin, Cephalexin and Ceftriaxone
Ogawa et al. [23]	Urine	1	Bacteremia (1)	Advanced uterine tumor with metastasis	Cefmetazol
Cardona-Benavides et al. [24]	Amniotic fluid	1	Intra-amniotic infection (1)	33-week pregnancy	Azithromicin, Ampicillin and Gentamicin
Takiguchi et al. [25]	Pleural fluid	1	Thoracic empyema	Tuberculosis	Ampicillin and Sulbactam / Amoxicillin and Potassium Clavulanate

*Source: the authors

Clarridge [26] examined positive urine cultures initially identified as belonging to the *Actinomyces* or *Gardnerella* group and identified the presence of a genetic marker (16S rRNA), subsequently confirmed as distinctive to *Alloscardoviaomnicolens*, in 5% of the samples. Mahlen and Clarridge [15] isolated five samples of *Alloscardoviaomnicolens* from 2005 urine samples of patients suspected of urinary tract infection over a one-year period, estimating a prevalence of approximately 0.2%. Two urine cultures positive for this bacterium were from the same patient, with a two-month time lapse between examinations. This patient had bladder cancer and presented with a urinary tract infection. *Alloscardoviaomnicolens* was the only microorganism that grew in the urine culture, at a concentration of approximately 105 CFU/ml in both cultures. An increase in the leukocyte count in the urinary sediment, suggestive of infection, was observed. The analysis using the RapID ANA II biochemical identification method failed to correctly identify the infectious agent. The RapID ANA II method works by inoculating a bacterial sample into a series of biochemical tests on strips or panels. Based on the observed biochemical reactions, the system provides a numerical code that can be used to identify the bacterial species in question. The RapID ANA II panel code for both isolates was 471771 (99.8% similarity to *Actinomyces israelii*). The therapeutic approach used for this patient was not reported. A second case of *Alloscardoviaomnicolens* infection was identified from the urine culture of a patient with T-cell lymphoma. The positive urine culture solely for this microorganism exhibited approximately 105 CFU/ml, albeit without pyuria. In the third case, the positive urine culture showed approximately 105 CFU/ml, and the patient was not subjected to antibiotic therapy due to the absence of urinary tract infection symptoms. This isolate also suffered the same diagnostic misidentification when using the RapID ANA II method, which suggested *Actinomyces israelii* as the suspected infecting agent. Regarding the fourth case where the presence of *Alloscardoviaomnicolens* was identified in the urine sample, no further clinical data on the patient were available. The medical records only indicated an "unidentified Gram-positive rod infection," later recognized as *Alloscardoviaomnicolens*, confirmed by mass spectrometry (MALDI-TOF MS) and RNA sequencing identification. The authors did not provide information about antibiotic treatment for the examined patients. Mahlen and Clarridge [15] emphasize that not all isolates of *Alloscardoviaomnicolens* can be definitively classified as opportunistic infectious agents, and they evaluate that only two cases in their research could be considered as infections. *Alloscardoviaomnicolens* can be mistaken for other Gram-positive, catalase-negative bacilli, even in biochemical tests, which may indicate an underestimation of infection cases caused by this bacterium.

Brown et al. [20] found that among 3395 urine samples examined between 2014 and 2015, a total of 15 cultures were positive for *Alloscardoviaomnicolens*. In the first group of nine patients examined in 2014, only one presented with fever and neutropenia, a child with Diamond-Blackfan anemia, and no other infectious agents were detected in microbiological tests except for *Alloscardoviaomnicolens*. In the group of patients examined in 2015, six urine cultures were positive for *Alloscardoviaomnicolens*. Only one patient exhibited symptoms consistent with a urinary tract infection and was treated with antibiotics. This patient had atrophic vaginitis and urgent urinary incontinence, complaining of burning upon urination, pelvic and lower back pain. Although she did not have a fever during her consultation, she reported having had a fever at home. Her urine examination was negative for leukocyte esterase and nitrite but positive for moderate blood presence. The urine culture yielded 20,000 CFU/ml of pure *Alloscardoviaomnicolens*.

Ogawa et al. [23] reported a clinical case of a 70-year-old woman with a history of advanced uterine cancer, who presented with malaise, bilateral lower limb edema, and oliguria. The patient was undergoing chemotherapy for cancer, which was refractory to treatment. The tumors were causing urethral constriction, and catheters were inserted to facilitate urinary function impaired by intra-abdominal metastasis growth. Two days after this procedure, the patient developed a sudden fever. Gram-positive rods of moderate length were detected in the anaerobic hemoculture. Analysis of the 16S ribosomal RNA of the isolated infectious agent showed a 100% match with *Alloscardoviaomnicolens*. The antibiogram demonstrated that the infecting strain was susceptible to all tested antibiotics (Penicillin, Ampicillin, Cefazolin, Cefoxitin, Ceftriaxone, Cefmetazole, Cefepime, Imipenem, Clarithromycin, Clindamycin, Levofloxacin, Minocycline, and Vancomycin). The patient was treated with Cefmetazole, and a percutaneous nephrostomy was performed, successfully controlling the infection.

Cardona-Benavides et al. [24] documented a clinical case involving a 31-year-old woman in the advanced stages of pregnancy, who had a medical history marked by obesity, irritable bowel syndrome, gastritis, and bronchial asthma. The patient presented to the Obstetrics and Gynecology emergency department, showing excessive watery vaginal discharge, devoid of vaginal bleeding or uterine contractions. Preliminary serological screenings for HIV, hepatitis B, and *Treponema pallidum* returned negative results. Additionally, microbiological assays targeting various potential infectious agents, conducted upon admission, yielded negative outcomes. Abdominal ultrasound scans revealed unremarkable findings. Subsequent cultivation of the amniotic fluid on blood agar medium in a CO₂-enriched atmosphere, following 48 hours of incubation, disclosed the presence of prolific colonies subsequently confirmed as *Alloscardoviaomnicolens* through MALDI-TOF analysis and definitive diagnosis via 16S RNA sequencing. Preceding the receipt of antibiotic susceptibility test results, the patient was subjected to a single dose of Azithromycin, followed by a sustained antibiotic regimen encompassing Ampicillin and Gentamicin. Antibiotic sensitivity analysis indicated susceptibility to Clindamycin, Ampicillin, Imipenem, Moxifloxacin, and Vancomycin, with exclusive resistance to Metronidazole. Notably, the patient exhibited favorable clinical progress throughout her hospitalization, remaining consistently afebrile without notable elevations in C-reactive protein levels or white blood cell counts. In the subsequent week, following corticosteroid-induced fetal lung maturation, labor induction was conducted. The newborn, upon assessment, exhibited a normal physiological status, devoid of any clinical manifestations indicative of infection. The clinical presentation of *Alloscardoviaomnicolens* infection, as reported by Cardona-Benavides et al. [24], represents a singular case lacking of any concomitant underlying medical conditions. This instance may be considered atypical, possibly stemming from an undetected genitourinary microbiota dysbiosis, where *Alloscardoviaomnicolens* transitioned from a commensal microorganism to an infectious agent.

A case report presented by Takiguchi et al. [25] described the clinical progression of a 62-year-old man with a history of smoking who reported worsening dyspnea after initiating tuberculosis treatment with Isoniazid, Rifampicin, Ethambutol, and Pyrazinamide. The patient had extremely poor oral hygiene. Chest radiography revealed an increase in right pleural effusion and pneumothorax compared to previous imaging studies conducted during the tuberculosis treatment period. Pleural fluid culture was performed, yielding the growth of *Alloscardoviaomnicolens*, *Bifidobacterium dentium*, and *Prevotella loescheii*, identified by PCR. Antibiotic therapy consisted of intravenous Ampicillin and Sulbactam every 6 hours, switched to oral Amoxicillin and Potassium Clavulanate on the thirty-fourth day, without discontinuation of tuberculosis treatment. The authors argue that pulmonary infections caused by oropharyngeal commensal bacteria are extremely rare and suggest that poor oral hygiene may have contributed to the empyema formation in the reported case. Interestingly, Naidoo et al. [27] point to a relative decrease in *Alloscardovia* among tuberculosis patients, and Mori et al. [28] indicate a decrease in the relative abundance and diversity of Bifidobacteriaceae during microbiome changes occurring during the course and treatment of tuberculosis. The case report by Takiguchi et al. [25], analyzed in the context of other research, can be considered atypical. The *Alloscardoviaomnicolens* strain in this case would be resistant to Rifampicin.

There is a scarcity of research on the pathogenic potential of *Alloscardoviaomnicolens* in the current scientific literature. Some reasons for this include the recent description of the bacterium, misdiagnosis of the actual infecting agent due to phenotypic similarity to other bacteria or inaccuracies in biochemical methods [15], the low incidence of the bacterium both as a microbiota component and as an opportunistic infectious agent [4,6,7,9,14,15,16,17,29], and the difficulty of

diagnosis through traditional laboratory routines [4,29,30,31,32]. Klein et al. [31] highlight that the laboratory automation process in bacterial culture has demonstrated a significant increase in the detection rate of *Alloscardoviaomnicolens* - ten times higher than the incidence recorded before laboratory routine changes - suggesting that this species may be underestimated as a causative pathogen of urinary tract infections. The recent availability of diagnostic methods based on PCR identification and metagenomic analysis can aid in determining the actual prevalence of colonization and infections by this bacterium [33,34,35]. Artificial intelligence analysis of microbiome composition changes may also provide valuable information for the identification of *Alloscardoviaomnicolens* and the treatment and elucidation of underlying diseases in which the predominance of the bacterium serves as a biological marker [36].

Antimicrobial resistance does not present a challenge in the context of *Alloscardoviaomnicolens* infections. The majority of strains exhibit sensitivity to all tested antibiotic classes with low minimum inhibitory concentrations (MIC), except for Metronidazole [23,24,37]. In rare instances, certain strains have been observed to display resistance to Erythromycin, Clindamycin, Fluoroquinolones [3], Gentamicin, Nitrofurantoin, Fosfomycin, and Daptomycin [37]. While the species itself does not exhibit substantial adaptive plasticity for antibiotic resistance, its capacity to colonize the human microbiota may, over time, select for resistant strains through mutational processes, thereby altering the prevailing pattern of broad susceptibility to these antibacterial agents.

The majority of *Alloscardoviaomnicolens* infections reported in the manuscripts included in our research were documented in patients with underlying medical conditions, such as bladder cancer, T-cell lymphoma [15], Diamond-Blackfan anemia, atrophic vaginitis [20], uterine tumors [23], and tuberculosis [25]. Recent investigations have unveiled alterations in the microbiome associated with severe pathologies, many of which exhibit an increased prevalence of *Alloscardoviaomnicolens*, characterized by its heightened relative abundance, thereby serving as a biomarker. These pathologies encompass intrahepatic cholangiocarcinoma [39, 40], squamous cell lung carcinoma [41,42], pancreatic ductal adenocarcinoma [36], Crohn's disease [43], adenomyosis, and endometriosis [11,12]. It is conceivable that physiological changes induced by these diseases or therapeutic interventions contribute to the predominance of *Alloscardoviaomnicolens* in conjunction with diminished immune function, this bacterium may transition from a commensal state to an opportunistic infectious agent. Further investigations are imperative to delineate the risks and conditions under which *Alloscardoviaomnicolens* assumes a pathogenic role, as well as to elucidate potential synergistic interactions between underlying diseases and the mechanisms driving the predominance of *Alloscardoviaomnicolens* in dysbiosis processes. Jia et al. [39] postulate that *Alloscardoviaomnicolens* might induce metabolic alterations conducive to carcinogenesis, suggesting that dysbiosis characterized by an overabundance of this bacterium may not be a consequence but rather a causative factor in the development of intrahepatic cholangiocarcinoma.

The clinical significance of positive cultures yielding *Alloscardoviaomnicolens* from biological specimens has been a subject of debate within the scientific community. Some authors argue that even when isolated in pure cultures, this bacterium should not be classified as an infectious agent due to its inherent presence in the human microbiota [15,20,44]. We posit that such an assessment should be contextualized, with healthcare providers considering the comprehensive health profile of the patient, encompassing risk factors, underlying medical conditions, and the state of the immune system when addressing cases of confirmed colonization by this bacterium. The monitoring of microbiota composition and the relative abundance of *Alloscardoviaomnicolens*, particularly in instances involving neoplastic conditions, can offer valuable insights for determining the appropriateness of prophylactic antibiotic therapy. Furthermore, this information may contribute to the evaluation of the stage and severity of the underlying disease, thereby shedding light on the dysbiosis dynamics in which *Alloscardoviaomnicolens* predominates.

4. CONCLUSION

Alloscardoviaomnicolens is a bacterium that is part of the microbiota in various sites of the human body. However, its colonization is relatively infrequent. Infection incidents attributed to this bacterium are scarce and predominantly manifest in the presence of underlying medical conditions, often concurrent with immunodepressive or immunosuppressive states. The detection of *Alloscardoviaomnicolens* in the culture of biological specimens from individuals afflicted with underlying diseases, particularly neoplastic disorders, warrants clinical significance. This is particularly pertinent when evaluating patients with precarious health statuses, where identified risk factors hint at the potential for opportunistic infections. Considering the prevailing antibiotic susceptibility patterns exhibited by the majority of contemporary *Alloscardoviaomnicolens* strains, we advocate the utilization of narrow-spectrum antibiotics in such scenarios, excluding Metronidazole. This therapeutic approach is poised to effectively eradicate *Alloscardoviaomnicolens* while exerting minor influence on the other constituents of the human microbiota.

REFERENCES

1. Huys G, Vancanneyt M, D'Haene K, Falsen E, Wauters G, Vandamme P. *Alloscardoviaomnicolens* gen. nov., sp. nov., from human clinical samples. *International Journal of Systematic and Evolutionary Microbiology*. 2007 Jul 1;57(7):1442–6.
2. Modesto M, Satti M, Watanabe K, Sciavilla P, Felis GE, Sandri C, et al. *Alloscardoviatheropithecii* sp. nov., isolated from the faeces of gelada baboon, the 'bleeding heart' monkey (*Theropithecus gelada*). *International Journal of Systematic and Evolutionary Microbiology*. 2019 Oct 1;69(10):3041–8.
3. Isnard C. Infections du tractus urinaire à pathogènes émergents. *Journal des Anti-infectieux*. 2015 Dec;17(4):152–61.
4. Lainhart W, Yarbrough ML, Jean S, Burnham CAD. New Bugs and New Drugs: Updates in Clinical Microbiology. *The Journal of Applied Laboratory Medicine*. 2018 May 1;2(6):925–40.
5. Moreland RB, Choi BI, Geaman W, Gonzalez C, Hochstedler-Kramer BR, John J, et al. Beyond the usual suspects: emerging uropathogens in the microbiome age. *Front Urol*. 2023 Jul 26;3:1212590.
6. Rosales-Castillo A, Jiménez-Guerra G, Ruiz-Gómez L, Expósito-Ruiz M, Navarro-Marí JM, Gutiérrez-Fernández J. Emerging Presence of Culturable Microorganisms in Clinical Samples of the Genitourinary System: Systematic Review and Experience in Specialized Care of a Regional Hospital. *JCM*. 2022 Mar 1;11(5):1348.
7. Rosales-Castillo A, Expósito-Ruiz M, Gutiérrez-Soto M, Navarro-Marí JM, Gutiérrez-Fernández J. Presence and Relevance of Emerging Microorganisms in Clinical Genitourinary Samples. *Microorganisms*. 2023 Mar 31;11(4):915.
8. Lainhart W, Gonzalez MD. *Aerococcusurinae*, *Alloscardoviaomnicolens*, and *Actinotignumchaalii*: the AAA Minor League Team of Urinary Tract Infection Pathogens. *Clinical Microbiology Newsletter*. 2018 May;40(10):77–82.
9. Chen YB, Hochstedler B, Pham TT, Alvarez MA, Mueller ER, Wolfe AJ. The Urethral Microbiota: A Missing Link in the Female Urinary Microbiota. *Journal of Urology*. 2020 Aug;204(2):303–9.
10. Chaban B, Links MG, Jayaprakash TP, Wagner EC, Bourque DK, Lohn Z, et al. Characterization of the vaginal microbiota of healthy Canadian women through the menstrual cycle. *Microbiome*. 2014 Dec;2(1):23.
11. Chao X, Liu Y, Fan Q, Shi H, Wang S, Lang J. The role of the vaginal microbiome in distinguishing female chronic pelvic pain caused by endometriosis/adenomyosis. *Ann Transl Med*. 2021 May;9(9):771–771.
12. Kunaseth J, Waiyaput W, Chanchaem P, Sawaswong V, Permpech R, Payungporn S, et al. Vaginal microbiome of women with adenomyosis: A case-control study. Staley C, editor. *PLoS ONE*. 2022 Feb 16;17(2):e0263283.
13. Tong Y, Sun Q, Shao X, Wang Z. Effect of vaginal microbiota on pregnancy outcomes of women from Northern China who conceived after IVF. *Front Endocrinol*. 2023 Jul 18;14:1200002.
14. Beighton D, Gilbert SC, Clark D, Mantzourani M, al-Haboubi M, Ali F, et al. Isolation and Identification of Bifidobacteriaceae from Human Saliva. *Appl Environ Microbiol*. 2008 Oct 15;74(20):6457–60.
15. Mahlen SD, Clarridge JE. Site and Clinical Significance of *Alloscardoviaomnicolens* and Bifidobacterium Species Isolated in the Clinical Laboratory. *J Clin Microbiol*. 2009 Oct;47(10):3289–93.
16. Husebø GR, Knudsen K, Nielsen R, Paytvi-Gallart A, Sanseverino W, Eagan TM. The role of the microbiome in COPD. In: 0301 - Molecular pathology and functional genomics [Internet]. European Respiratory Society; 2022p. 3745.

17. Téllez Corral MA, Herrera Daza E, Cuervo Jimenez HK, Bravo Becerra MDM, Villamil JC, Hidalgo Martinez P, et al. Cryptic Oral Microbiota: What Is Its Role as Obstructive Sleep Apnea-Related Periodontal Pathogens? *IJERPH*. 2023 Jan 18;20(3):1740.
18. Sánchez MC, Velapatiño A, Llama-Palacios A, Valdés A, Cifuentes A, Ciudad MJ, et al. Metataxonomic and metabolomic evidence of biofilm homeostasis disruption related to caries: An in vitro study. *Molecular Oral Microbiology*. 2022 Apr;37(2):81–96.
19. Sousa V, Spratt D, Davrandi M, Mardas N, Beltrán V, Donos N. Oral Microcosm Biofilms Grown under Conditions Progressing from Peri-Implant Health, Peri-Implant Mucositis, and Peri-Implantitis. *IJERPH*. 2022 Oct 28;19(21):14088.
20. Brown MK, Forbes BA, Stitley K, Doern CD. Defining the Clinical Significance of *Alloscardoviaomnicolens* in the Urinary Tract. Carroll KC, editor. *J Clin Microbiol*. 2016 Jun;54(6):1552–6.
21. Moher D, Liberati A, Tetzlaff J, Altman DG, The PRISMA Group. Preferred Reporting Items for Systematic Reviews and Meta-Analyses: The PRISMA Statement. *PLoS Med*. 2009 Jul 21;6(7):e1000097.
22. Page MJ, McKenzie JE, Bossuyt PM, Boutron I, Hoffmann TC, Mulrow CD, et al. The PRISMA 2020 statement: an updated guideline for reporting systematic reviews. *BMJ*. 2021 Mar 29;n71.
23. Ogawa Y, Koizumi A, Kasahara K, Lee ST, Yamada Y, Nakano R, et al. Bacteremia secondary to *Alloscardoviaomnicolens* urinary tract infection. *Journal of Infection and Chemotherapy*. 2016 Jun;22(6):424–5.
24. Cardona-Benavides I, Puertas-Prieto A, Pinilla-Martín FJ, Navarro-Marí JM, Gutiérrez-Fernández J. *Alloscardoviaomnicolens* emerging presence in premature rupture of membranes. *New Microbiol*. 2019 Oct;42(4):237–9.
25. Takiguchi Y, Nagayoshi M, Matsuura Y, Yokota S, Kajiwara Y, Akiba Y. Thoracic empyema caused by *Alloscardoviaomnicolens* and *Bifidobacterium dentium*. *Journal of Infection and Chemotherapy*. 2022 Nov;28(11):1567–70.
26. Clarridge JE. Occurrence of fastidious organisms identified by 16S rDNA sequencing recovered from urine relative to uropathogens, 103rd General Meeting of the Society for Microbiology American. *Society for Microbiology 2003*; 1: 154.
27. Naidoo CC, Nyawo GR, Wu BG, Walzl G, Warren RM, Segal LN, et al. The microbiome and tuberculosis: state of the art, potential applications, and defining the clinical research agenda. *The Lancet Respiratory Medicine*. 2019 Oct;7(10):892–906.
28. Mori G, Morrison M, Blumenthal A. Microbiome-immune interactions in tuberculosis. Hiller NL, editor. *PLoS Pathog*. 2021 Apr 15;17(4):e1009377.
29. Książek MD. Comprehensive urogenital microbiome profiling: towards better understanding of female urinary tract in health and disease. Minho University, Portugal, 2022. Available from: <https://repositorium.sdum.uminho.pt/bitstream/1822/41833/1/Patr%C3%ADcia%20Maria%20Alves.pdf>
30. Price TK, Dune T, Hilt EE, Thomas-White KJ, Kliethermes S, Brincat C, et al. The Clinical Urine Culture: Enhanced Techniques Improve Detection of Clinically Relevant Microorganisms. Forbes BA, editor. *J Clin Microbiol*. 2016 May;54(5):1216–22.
31. Klein S, Nurjadi D, Horner S, Heeg K, Zimmermann S, Burckhardt I. Significant increase in cultivation of *Gardnerella vaginalis*, *Alloscardoviaomnicolens*, *Actinotignum schaalii*, and *Actinomyces* spp. in urine samples with total laboratory automation. *Eur J Clin Microbiol Infect Dis*. 2018 Jul;37(7):1305–11.
32. Lainhart W, Burnham CAD. Enhanced Recovery of Fastidious Organisms from Urine Culture in the Setting of Total Laboratory Automation. Onderdonk AB, editor. *J Clin Microbiol*. 2018 Aug;56(8):e00546-18.

33. Moustafa A, Li W, Singh H, Moncera KJ, Torralba MG, Yu Y, et al. Microbial metagenome of urinary tract infection. *Sci Rep*. 2018 Mar 12;8(1):4333.
34. Wojno KJ, Baunoch D, Luke N, Opel M, Korman H, Kelly C, et al. Multiplex PCR Based Urinary Tract Infection (UTI) Analysis Compared to Traditional Urine Culture in Identifying Significant Pathogens in Symptomatic Patients. *Urology*. 2020 Feb;136:119–26.
35. Almas S, Carpenter RE, Rowan C, Tamrakar VK, Bishop J, Sharma R. Advantage of precision metagenomics for urinary tract infection diagnostics. *Front Cell Infect Microbiol*. 2023 Jul 4;13:1221289.
36. Kartal E, Schmidt TSB, Molina-Montes E, Rodríguez-Perales S, Wirbel J, Maistrenko OM, et al. A faecal microbiota signature with high specificity for pancreatic cancer. *Gut*. 2022 Jul;71(7):1359–72.
37. Isnard C, Lienhard R, Reissier S, Rodriguez S, Krähenbühl J, Liassine N, et al. In vitro antimicrobial susceptibility of *Alloscardoviaomnicolens* and molecular mechanisms of acquired resistance. *Diagnostic Microbiology and Infectious Disease*. 2016 Mar;84(3):227–9.
38. Byun JH, Kim M, Lee Y, Lee K, Chong Y. Antimicrobial Susceptibility Patterns of Anaerobic Bacterial Clinical Isolates From 2014 to 2016, Including Recently Named or Renamed Species. *Ann Lab Med*. 2019 Mar 31;39(2):190–9.
39. Jia X, Lu S, Zeng Z, Liu Q, Dong Z, Chen Y, et al. Characterization of Gut Microbiota, Bile Acid Metabolism, and Cytokines in Intrahepatic Cholangiocarcinoma. *Hepatology*. 2020 Mar;71(3):893–906.
40. Herraes E, Romero MR, Macias RIR, Monte MJ, Marin JJG. Clinical relevance of the relationship between changes in gut microbiota and bile acid metabolism in patients with intrahepatic cholangiocarcinoma. *Hepatobiliary Surg Nutr*. 2020 Apr;9(2):211–4.
41. Zhao Z, Fei K, Bai H, Wang Z, Duan J, Wang J. Metagenome association study of the gut microbiome revealed biomarkers linked to chemotherapy outcomes in locally advanced and advanced lung cancer. *Thoracic Cancer*. 2021 Jan;12(1):66–78.
42. Sani SN, Zhou W, Ismail BB, Zhang Y, Chen Z, Zhang B, et al. LC-MS/MS Based Volatile Organic Compound Biomarkers Analysis for Early Detection of Lung Cancer. *Cancers*. 2023 Feb 13;15(4):1186.
43. Sukhina MA, Yudin SM, Zagainova AV, Makarov VV, Veselov AV, Anosov IS, et al. Peculiarities of Microbiota in Patients with Inflammatory Intestinal Diseases. *Annals RAMS*. 2022 Jul 31;77(3):165–71.